Chapter 3

Causes of Congenital Malformations

Martin Lammens, Hans J. ten Donkelaar, John M.G. van Vugt, Gerard van Noort, Michèl Willemsen and Ben Hamel

3.1 Introduction

Congenital malformations are structural abnormalities due to faulty development, present at birth, and are among the major causes of prenatal, perinatal and infant mortality and morbidity. They include gross and microscopic malformations, inborn errors of metabolism, mental retardation and cellular and molecular abnormalities. About 2–3% of newborns have a single major malformation, and 0.7% have multiple major defects (Norman et al. 1995; Opitz and Wilson 1997; Aicardi 1998; Volpe 2001a). The frequency is much higher prenatally, the majority aborting spontaneously (Shiota 1991, 1993; Kalousek 1997). More than 80% of malformed conceptuses are lost during the embryonic period, and more than 90% before birth. The importance of congenital malformations as a cause of perinatal mortality has increased as deaths from intrapartum problems and infectious diseases have declined, and better neonatal care has improved the survival of normally developed low-birthweight babies. During the last few decades, there has been a rapid expansion of methods for detecting many different types of disorders prenatally. In this introductory chapter the known causes of congenital CNS malformations, and possibilities to detect them prenatally, will be outlined. Some emphasis will be given to the increasing group of inborn errors of metabolism affecting the CNS (neurometabolic disorders), myelination disorders, and vascular disorders, the last being the major cause of acquired damage to the developing nervous system.

3.2 Causes of Congenital Malformations

The causes of congenital malformations may be divided into five broad groups (Warkany 1971; Norman et al. 1995; Jones 1997; Opitz and Wilson 1997; Keeling and Boyd 2001): (1) single gene defects (mutant genes); (2) chromosome abnormalities; (3) multifactorial disorders which are the result of interaction between genetic predisposition and presumed environmental factors; (4) teratogenic factors; and (5) those of unknown cause. Despite the tremendous advances in genetics over the last decade, the aetiology of more than 50% of malformations is still unknown (Opitz and Wilson 1997; Moore et al. 2000; Keeling and Boyd 2001). Mutant genes, chromosome abnormalities and known teratogens can each be identified in about 7–8% of malformations, and a further 20–25% of malformations fall into the group of multifactorial disorders. A broad subdivision of malformations includes abnormalities of **pregenesis** (gonadogenesis, gametogenesis), **blastogenesis** (the first four embryonic weeks), **organogenesis** (the fifth to eighth embryonic weeks) and **phenogenesis** (roughly the fetal period; Opitz 1993; Opitz et al. 1997). Some essential and widely used terms and concepts relating to malformations are summarized in Table 3.1 (Spranger et al. 1982; Opitz 1993; Opitz et al. 1997). A glossary of genetic terms is included as Table 3.2 (Anderson 1995; Strachan and Read 2004).

3.2.1 Genetic Disorders

Chromosomal Abnormalities

Human development is dependent on the correct chromosome complement, usually 22 homologous pairs of autosomes and one pair of sex chromosomes (Fig. 3.1a). In general, one member of each pair of chromosomes is inherited from each parent. Each chromosome can be easily recognized by banding technology and, more recently, with fluorescence in situ hybridization (FISH; Fig. 3.2). Chromosome malformations are due to either excess or deficiency of chromosomal material including unbalanced rearrangements (Fig. 3.4). Approximately 1 in 200 live newborns will have a chromosome abnormality (Gilbert-Barness 1997; Miller and Therman 2001). In perinatal deaths, the frequency varies between 5 and 10%, and is estimated to be more than 60% in first-trimester miscarriages (Shiota 1993; Kalousek 1997; Keeling and Boyd 2001). Excess or deficiency of chromosomal material can arise through a change in either chromosome number or structure. Changes in chromosome number are of two types: (1) ***polyploidy***, an abnormal multiple of the haploid number 23, such as triploidy with 69 chromosomes; and (2) ***aneuploidy***, the loss or gain of a whole chromosome (monosomy and trisomy, respectively). A given aberration may be present in all body cells, or in two or more cell lines (***mosaicism***; Hall 1988; Youssoufian and Pyeritz 2002). ***Triploidy*** occurs in approximately 6% of recognized pregnancies (Keeling and Boyd

Table 3.1 Terms and concepts relating to malformations (based on Spranger et al. 1982; Opitz and Wilson 1997)

Individual alterations of form and structure	
Malformation	A morphological defect of an organ, part of an organ or a larger region of the body resulting from an intrinsically abnormal developmental process
Disruption	A morphological defect of an organ, part of an organ or a larger region of the body resulting from the extrinsic breakdown of, or interference with, an originally normal developmental process
Deformation	An abnormal form, shape or position of a part of the body caused by mechanical forces
Dysplasia	An abnormal organization of cells into tissue(s) and its morphological result(s)
General terminology	
Hypoplasia, hyperplasia	Underdevelopment and overdevelopment of an organism, organ or tissue resulting from a decreased or increased number of cells, respectively
Hypotrophy, hypertrophy	A decrease or increase in the size of cells, tissues or organs, respectively
Agenesis	Absence of a part of the body caused by an absent anlage (primordium)
Aplasia	Absence of a part of the body resulting from a failure of the anlage to develop
Atrophy	Decrease of a normally developed mass of tissue(s) or organ(s) because of a decrease in cell size and/or cell number
Patterns of morphological defects	
Polytopic field defect	A pattern of anomalies derived from the disturbance of a single developmental field
Sequence	A pattern of multiple anomalies derived from a single known or presumed prior anomaly or mechanical factor
Syndrome	A pattern of multiple anomalies thought to be pathogenetically related and not known to represent a single sequence or a polytopic field defect
Association	A non-random occurrence in two or more individuals of multiple anomalies not known to be a polytopic field defect, sequence or syndrome

2001), and is usually due to an error of fertilization: an ovum being fertilized by two spermatozoa. Both polyploidy and monosomy (with the exception of a small proportion of monosomy X: Turner syndrome) are virtually lethal in man. An additional chromosome is much more common than chromosome loss. ***Autosomal trisomy*** has been recorded for most autosomes, but the incidence varies enormously. Trisomy of chromosome 16 is the most common, but the usual result of this anomaly is spontaneous or missed abortion in the first trimester (Kalousek et al. 1990; Warburton et al. 1991; Kalousek 1997). The most common liveborn example is Down syndrome (trisomy 21; Fig. 3.1b), followed by trisomy 18 (Edwards syndrome) and trisomy 13 (Patau syndrome); first described by Down (1866), Edwards et al. (1960) and Patau et al. (1960) (Table 3.3). Even amongst these karyotypes, miscarriage is the most common outcome (Kalousek et al. 1990; Kalousek 1997).

Down syndrome is characterized by mental deficiency, a characteristic facial expression that results from the upward slanting of the eyes and the prominent skin folds extending from the base of the nose to the inner aspect of the eyebrows and other anomalies of body form. Frequently, there are also congenital heart malformations. Down syndrome is due to three categories of chromosomal abnormalities: (1) trisomy 21, secondary to non-disjunction during meiosis (95% of affected individuals); (2) translocation type or partial trisomy 21; and (3) mosaicism for trisomy 21. The extra chromosome 21 is maternal in origin in some 95% of cases (Antonarakis 1991). In less than 5% of the cases with Down syndrome, the trisomy 21 occurs as a result of an unbalanced translocation. Mosaicism for trisomy 21 is the rarest, less than 1–2% of cases. Trisomy 21 is the most common of all age-related chromosomal abnormalities, constituting about half the overall maternal age-related risk (Laxova 1997): at ages 35, 40 and 45, the risk is about 1 in 270, 1 in 135, and 1 in 50, respectively. Cytogenetic prenatal diagnosis of Down syndrome is established by chorion villus sampling (between 10 and 12 gestational weeks) or amniocentesis (between 14 and 16 weeks). Screening by measuring nuchal translucency thickness (Fig. 3.3), an early ultrasound marker for Down syndrome (Nicolaides et al. 1992, 1999; Snijders and Nicolaides 1996; Pajkrt et al. 1998a, b), carried out in the first trimester of pregnancy has a higher detection rate than invasive methods. Brains of patients with Down syndrome are characteristically small, rounded, foreshortened and exhibit a steep rise of the occipital lobes, extreme

Table 3.2 Glossary of genetic terms (after Anderson 1995; Strachan and Read 2004)

Alleles	Alternative forms of genes occuping an identical site (locus), e.g. the A and B alleles of the ABO blood group gene
Aneuploidy	Deviations by an integral number (rather than a multiple) from the normal diploid complement (2×23=46) of chromosomes
Association	The occurrence together in the population of two genes or phenotypic traits in a frequency greater than would be predicted on the chance basis of their individual frequencies
Autosomes	Non-sex chromosomes in the nucleus (pairs 1–22)
Carrier	A person who is carrying one copy of a gene, which causes symptoms only when present in double dose, and therefore the person is unaffected
Centromere	A construction connecting the chromatids in mitosis, separating the two arms
Codon	The unit of the genetic code, i.e. 3 bases in either DNA or RNA, that specifies a single amino acid to be incorporated into a protein
Dominant	One copy of a gene out of the normal pair produces a phenotypic effect
Exon	The portion of the gene that is transcribed into messenger RNA, usually containing coding information
Fragile site	A specific region on a chromosome that is prone to breakage, usually appearing as a non-staining gap or constriction in one or both chromatids in a metaphase chromosome
Gene	The unit of inheritance for one characteristic or trait, i.e. usually one localized DNA sequence coding for one protein
Haploid	The chromosome number usually found in a normal gamete with only one copy of each pair (in humans, the haploid complement is 23)
Insertion	A structural abnormality in which a sequence of DNA is introduced into another sequence, either at the DNA level or at the chromosome level
Intron	A sequence of DNA that is initially transcribed into messenger RNA, but is then removed from the trancsript by 'splicing' together the exon sequences on either side of it. It is the portion of DNA that usually does not contain coding information
Inversion	A structural chromosomal abnormality in which a segment of a chromosome is reversed, each end reattached to where the other end had previously been attached
Linkage	The location of two genes near enough to one another on the same chromosome that they are coinherited through a meiotic event more than 50% of the time
Locus	A location on the chromosome, usually implying the position of a gene
Mosaic	A person with cells with more than one genetic makeup
Multifactorial	A pattern of inheritance determined by the interaction of multiple genes with others and with the environment
Mutation	A permanent and inheritable change in genetic material.
Oligonucleotide	A short piece of DNA, usually 5–50 nucleotides
Phenotype	Characteristics observed in a person that reflect the gene and/or (to varying degrees) interaction with the environment
Polymorphism	An inherited characteristic present in the population at a frequency great enough that the rarest allele is not maintained by recurrence mutation alone
Recessive	The mechanism of single-gene inheritance that requires 2 doses of a mutant gene in order for the phenotype to manifest
Ring chromosome	A structural chromosomal abnormality with deletions of the terminal portions of the arms of the chromosome and the broken sticky arms rejoining to form a ring
Sex chromosome	The chromosomes that are different in the sexes (usually XX in women and XY in men)
Telomere	The tip of a chromosome
Translocation	The exchange of chromosomal material between two different chromosomes, either 'balanced' (no loss or gain of genetic material) or 'unbalaned'
Trisomy	3, rather than 2, copies of a given chromosome are present

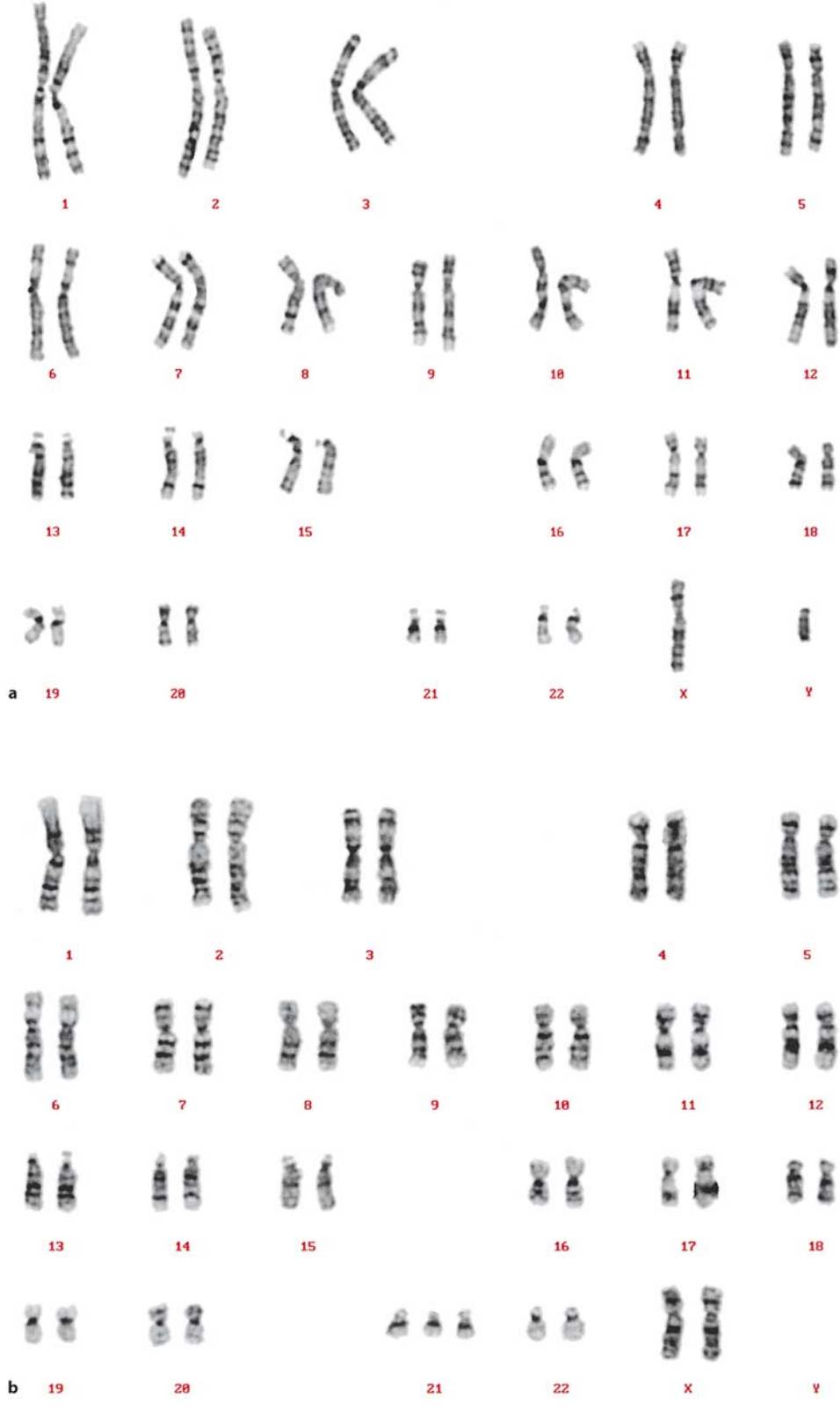

Fig. 3.1 G-banding pattern of human chromosomes: **a** normal; **b** in trisomy 21

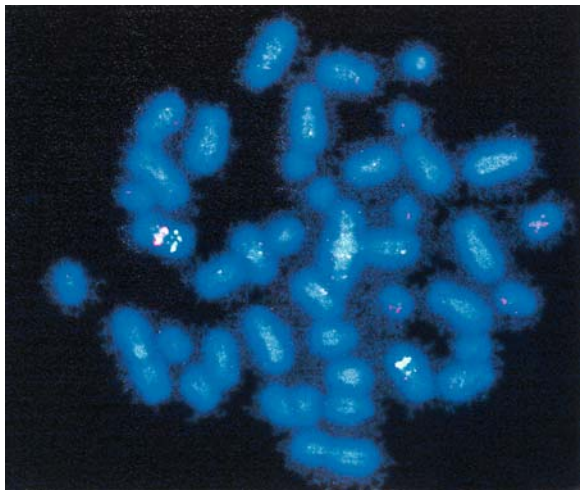

Fig. 3.2 Fluorescence in situ hybridization: example of microdeletion syndrome (Williams syndrome). The *light-blue* probe is a marker for the chromosome of interest (chromosome 7). The *pink* probe is a marker for the region of interest on that chromosome (7q11.23). The absence of a signal of the pink probe on one of the two chromosomes 7 proves that region 7q11.23 is deleted and supports the clinical diagnosis of Williams syndrome

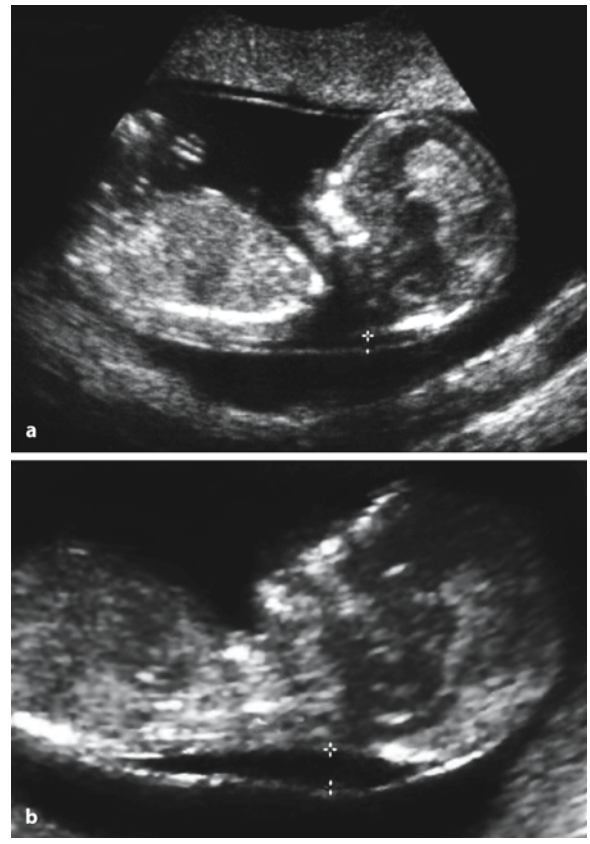

Fig. 3.3 Normal (**a**) and thickened (**b**) nuchal translucency associated with Down syndrome

Table 3.3 Autosomal trisomy syndromes (after Moore et al. 2000)

Chromosome aberration/syndrome	Incidence	Clinical manifestations
Trisomy 13 (Patau syndrome)	1:25,000	Mental deficiency; severe CNS malformations; sloping forehead; malformed ears; scalp defects; microphthalmia; bilateral cleft lip and/or palate; polydactyly; posterior prominence of heels
Trisomy 18 (Edwards syndrome)	1:8,000	Mental deficiency; growth retardation; prominent occiput; short sternum; ventricular septal defect; micrognathia; low-set, malformed ears, flexed digits with hypoplastic nails; rocker-bottom feet
Trisomy 21 (Down syndrome)	1:800	Mental deficiency; brachycephaly; flat nasal bridge; upward slant topalpebral fissures; protruding tongue; simian crease, clinodactyly of the 5th digit; congenital heart defects

narrowing of the superior temporal gyri, incomplete opercularization with exposure of the insular cortex and reduced secondary sulcal development (Källén et al. 1996; Cairns 1999; de la Monte 1999). These abnormalities are largely due to diminished and malformed growth of the frontal and temporal lobes secondary to impaired neuronal differentiation (Lubec and Engidawork 2002). Brain weight is usually in the low normal range, whereas the brain stem and cerebellum are small in relation to the cerebral hemispheres (Scott et al. 1983; Weis et al. 1991). Histological changes include abnormalities in cortical lamination, irregular clustering of neurons, muted dendritic arborization and proliferation of dystrophic neurites (Marín-Padilla 1972, 1976; de la Monte 1999; Chap. 10). Virtually all Down syndrome patients develop Alzheimer-like pathology by the fourth decade of life (Mann 1988).

Structural chromosome abnormalities may involve translocations (exchange of material between chromosomes), inversions, deletions or duplications (Gardner and Sutherland 1996; Fig. 3.4). They may

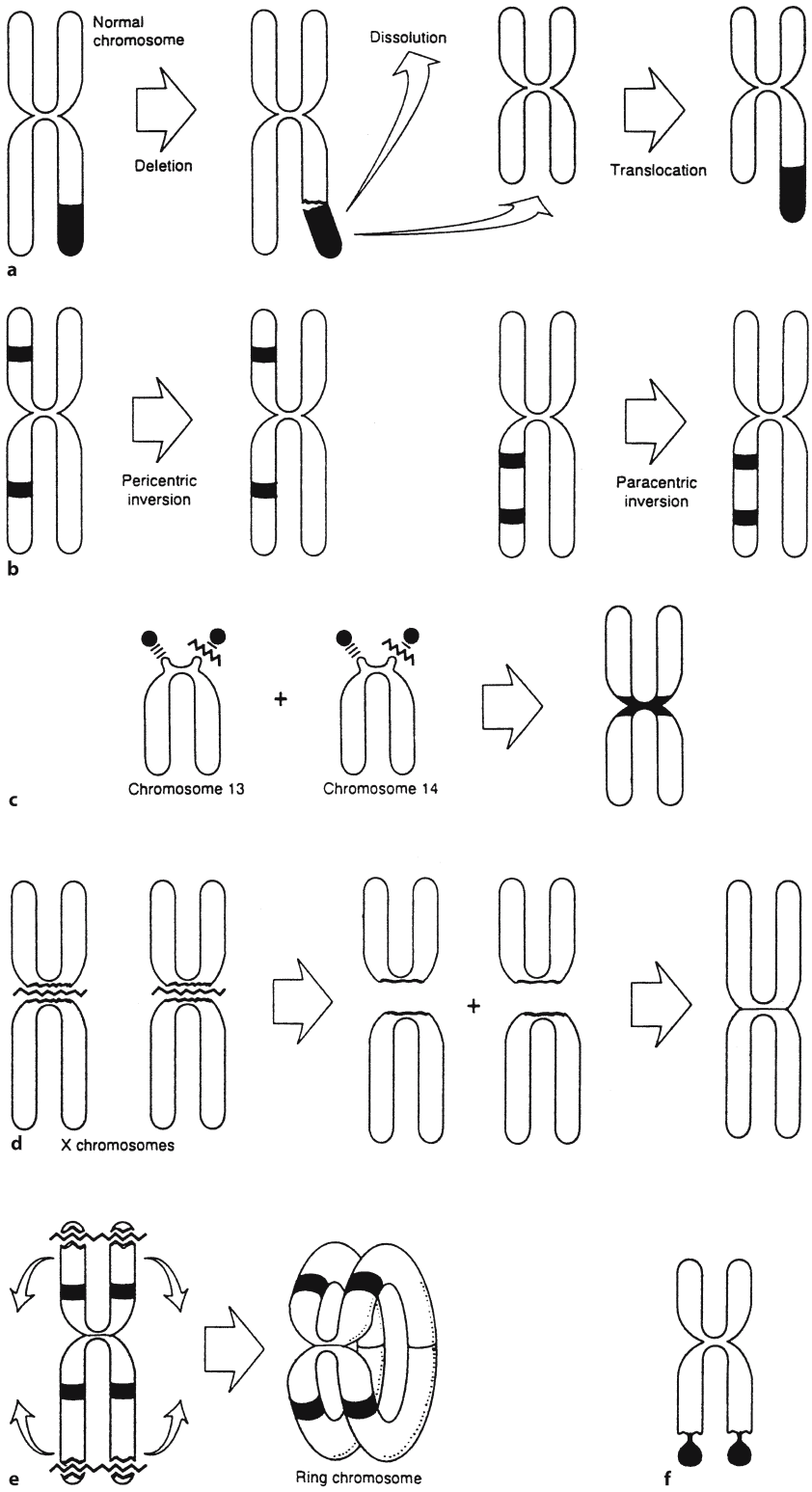

Fig. 3.4 Structural chromosomal abnormalities: **a** deletion and translocation; **b** inversion; **c** Robertsonian translocation; **d** isoschromosomal translocation; **e** ring formation; **f** fragile site (after Anderson 1995)

arise de novo or as a result of a parental chromosome rearrangement. Fusion at or near the centromere of the five acrocentric chromosomes, known as Robertsonian translocation, is one of the most common balanced structural rearrangements. Simple reciprocal translocations involve exchange of material between two chromosomes. Balanced carriers are entirely normal, but they are at risk of having chromosomally unbalanced offspring or miscarriages due to malsegregation at meiosis. Unbalanced structural

Table 3.4 Microdeletion syndromes with CNS manifestations

Syndrome	Location	Parental origin	Symptoms
Angelmann syndrome	15q11-13	Maternal	Mental retardation; macrostomia; prognathia; paroxysmal laughter
DiGeorge syndrome	22q11	Either parent	Aplasia of thymus and parathyroids; malformations great vessels/heart
Velocardiofacial (Shprintzen) syndrome	22q11	Either parent	Palatoschizis; heart malformations; growth retardation; sometimes mental retardation
Miller–Dieker syndrome	17p13	Either parent	Mental retardation; lissencephaly
Prader–Willi syndrome	15q11-13	Paternal	Mental retardation; hypotonia; adipositas
Rubinstein–Taybi syndrome	16p13.3		Mental retardation; broad thumbs and great toes
Smith–Magenis syndrome	17p11.2	Either parent	Mental retardation; deafness; eye malformations
Williams syndrome	7q11.23	Either parent	Mental retardation; typical facies; cardiovascular malformations
Wilms tumour and aniridia genitourinary anomalies and mental retardation	11p13		Urogenital malformations; mental retardation

chromosome rearrangements result in deletions (partial monosomy) and duplications (partial trisomy). ***Microdeletion syndromes***, such as Prader–Willi and Angelmann syndromes (chromosome 15), DiGeorge and Shprintzen syndromes (chromosome 22), and Miller–Dieker syndrome (chromosome 17; Chap. 10), are being recognized with increasing frequency (Malcolm 1996; Strachan and Read 2004; Table 3.4). Deletion of chromosome 22q11 (del22q11) is associated with a wide variety of clinical phenotypes (Chap. 5). In certain microdeletion syndromes, ***genomic imprinting*** is important. The female and male parent confer a sex-specific mark on a chromosome subregion so that only the paternal or maternal allele of a gene is active in the offspring. Therefore, the sex of the transmitting parent will influence the expression or non-expression of certain genes in the offspring. In Prader–Willi and Angelmann syndromes, the phenotype is determined by whether the microdeletion is transmitted by the father (Prader–Willi syndrome) or the mother (Angelmann syndrome).

Single Gene Defects

These disorders are the result of a single mutant gene and follow the Mendelian rules, either as autosomal dominant, autosomal recessive or X-linked traits. Many of the more than 8,000 disorders identified are rare and others may not show morphological defects (McKusick 1998; OMIM). Known single gene defects account for approximately 8% of congenital malformations at term. **Autosomal dominant gene defects** give rise to recognizable effects in heterozygous individuals, usually with an equal sex distribution in about 50% of the offspring. Some of these disorders, such as Huntington disease and some of the autosomal dominant cerebellar ataxias, do not produce recognizable disease before adult life, whereas others, such as achondroplasia and thanatophoric dysplasia, are recognizable at birth and may be detected prenatally by ultrasound examination. When an autosomal disorder occurs with unaffected parents, a new mutation is not likely to recur in siblings. Gonadal mosaicism, reduced penetrance and variable expression may represent a small but real recurrence rate. Small deletions, responsible for contiguous gene syndromes, may segregate as dominant mutations. For example, velocardiofacial syndrome (VCFS) is due to deletion of 22q11, but with sufficient extensive deletion a more severe condition arises, including DiGeorge sequence (Chap. 5).

Autosomal recessive gene defects occur equally in males and females, and are only clinically manifest in homozygotes with a recurrence risk of 25%. Therefore, affected individuals have healthy, heterozygous parents. Unless an autosomal recessive disorder is common in a certain population, such as Tay–Sachs disease in Ashkenazi Jews, there is often a history of consanguineous marriage. An example of a recessive inherited disorder, affecting the CNS, is Meckel–Gruber syndrome, a triad of CNS malformations, consisting of prosencephalic dysgenesis, occipital encephalocele and rhombic roof dysgenesis, combined with multicystic, dysplastic kidneys and polydactyly (Hori et al. 1980; Ahdab-Barmada and Claassen 1990; Clinical Case 3.1).

X-linked recessive gene defects usually affect only males in 50% of cases if the mother is a carrier. The disorder is usually transmitted by healthy female carriers and their daughters have a similar chance of carrying the gene. Since the father, in general, does not pass an X chromosome to his sons, he will never pass the X-linked recessive trait to his male offspring. Examples are Duchenne muscular dystrophy and

Clinical Case 3.1
Meckel–Gruber Syndrome

Originally described by Meckel (1822) and labelled ***dysencephalia splanchnocystica*** by Gruber (1934), the autosomal recessive ***Meckel–Gruber syndrome*** is a lethal multiple malformation syndrome that is characterized by a posterior encephalocele, by cysts of the kidneys, pancreas and liver and by polydactyly (Opitz and Howe 1969; Ahdab-Barmada and Claassen 1990). Additionally, aplasia of the olfactory tracts, microphthalmia, talipes and incomplete development of the external and/or internal genitalia may be found. Hori et al. (1980) presented a case of a male infant with multiple malformations (see Case Report).

Case Report. A 40-year-old mother with a history of three abortions and one child with multiple malformations including cheilopalatoschisis, cardiac anomalies and cleft bladder who died shortly after birth gave birth to a macrosomic male infant (4,650 g body weight) with multiple malformations. The infant survived for 4 days. External dysplasias comprised macrocephaly (head circumference 42 cm), cheilopalatoschisis, auricular anomalies and unilateral hexadactyly. Internal dysplasias were cysts of the kidneys and pancreas and a patent foramen ovale. The child had frequent generalized convulsions and died of bronchopneumonia. Chromosomal analysis was normal. The main neuropathological findings were a cleft foramen magnum, micropolygyria and heterotopia of the cerebral cortex, hypoplasia of the vermis and central white matter of the cerebellum, diffuse heterotopia of Purkinje cells and unique heterotopic grey matter in the central part of the cervical spinal cord (Fig. 3.5). The infant's disorder was classified as Gruber syndrome (Hori et al. 1980).

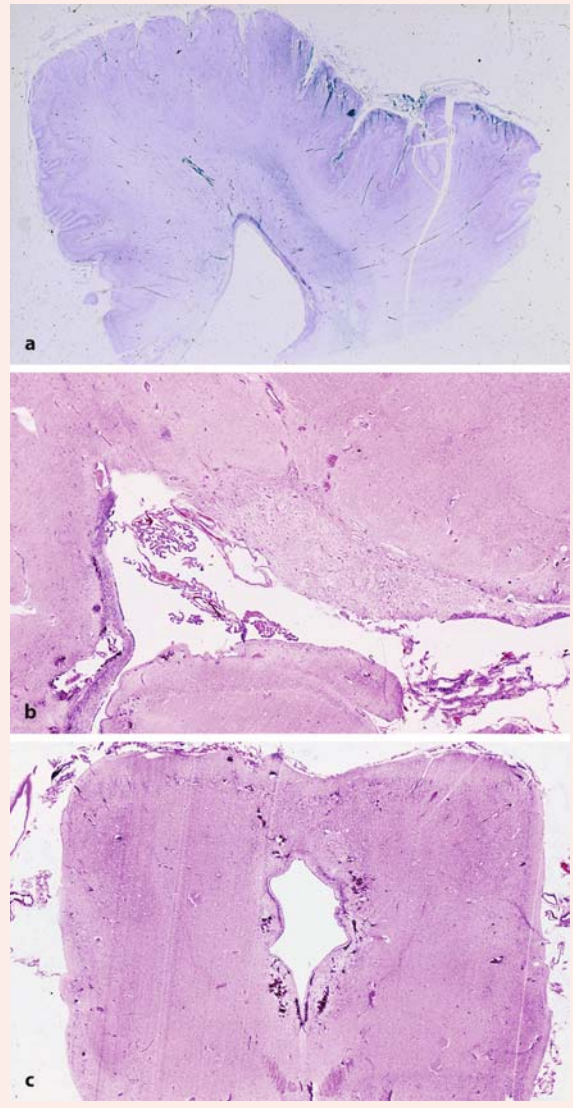

Fig. 3.5 Meckel–Gruber syndrome, showing various malformations of the brain: **a** micropolygyria of the cerebral cortex; **b** gliomesenchymal dysgenesis of the basal forebrain; **c** subependymal and tegmental calcifications in the mesencephalon

References

Ahdab-Barmada M, Claassen D (1990) A distinctive triad of malformations of the central nervous system in the Meckel-Gruber syndrome. J Neuropathol Exp Neurol 49:610–620

Gruber GB (1934) Beiträge zur Frage "gekoppelter" Mißbildungen (Akrocephalo-Syndactylie und Dysencephalia splanchnocystica). Beitr Pathol Anat Alg Pathol 93:459–476

Hori A, Orthner H, Kohlschütter A, Schott KM, Hirabayashi K, Shimokawa K (1980) CNS dysplasia in dysencephalia splanchnocystica (Gruber's syndrome). Acta Neuropathol (Berl) 51:93–97

Meckel JF (1822) Beschreibung zweier, durch sehr ähnliche Bildungsabweichungen entstellter Geschwister. Dtsch Arch Physiol 7:99–172

Opitz JM, Howe JJ (1969) The Meckel syndrome (dysencephalia splanchnocystica, the Gruber syndrome). Birth Defects Orig Art Ser 5:167–179

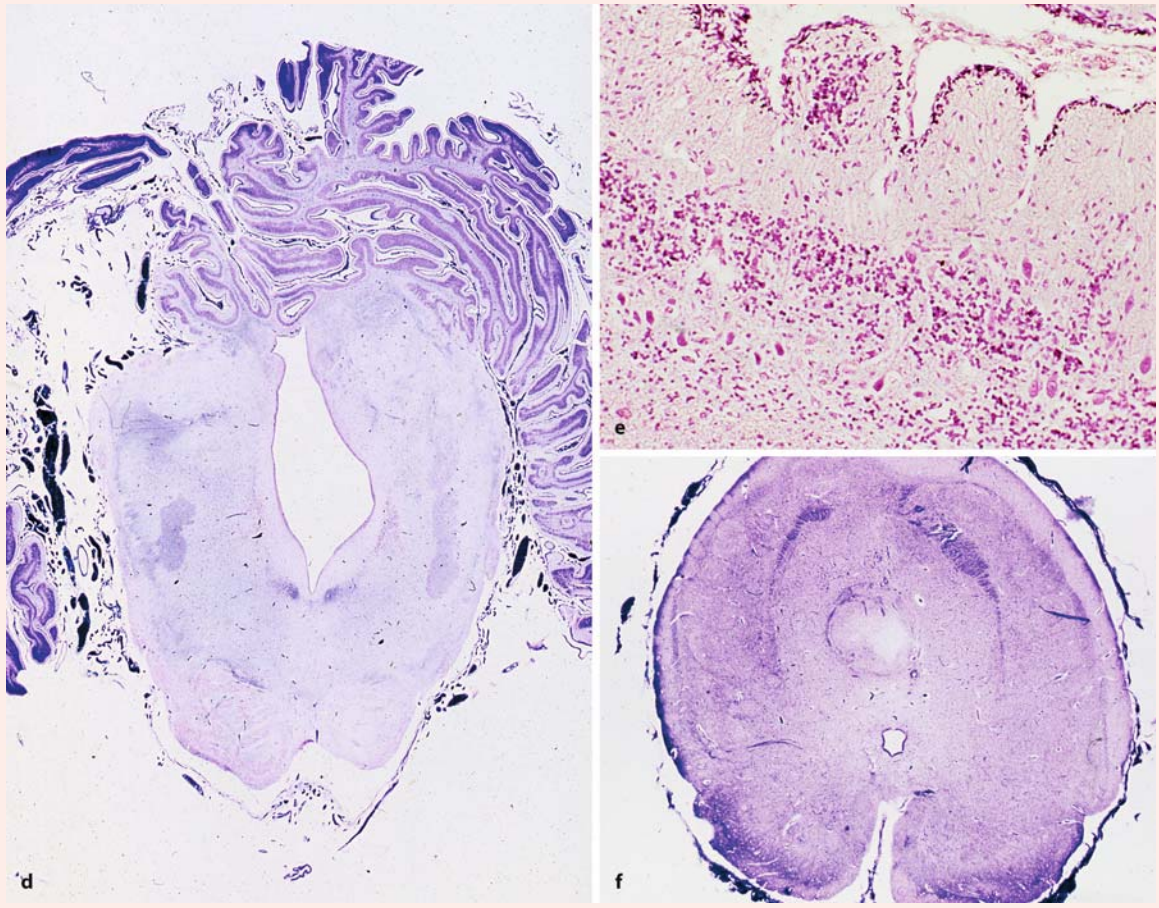

Fig. 3.5 *(Continued)* **d** displacement of cerebellar and vestibular nuclei, enlarged fourth ventricle and pontine hypoplasia; **e** reversed Purkinje cell layer; **f** heterotopia above the central canal and misplaced dorsal roots in upper cervical cord (mostly Luxol Fast Blue staining; from the Department of Neuropathology, Medizinische Hochschule Hannover; courtesy Akira Hori)

haemophilia. The fragile X mental retardation syndrome is not straightforwardly X-linked (Gardner and Sutherland 1996; Hamel 1999; Warren and Sherman 2001; O'Donnell and Warren 2002). It is the most common form of inherited mental retardation, affecting 1 in 4,000–6,000 males and 1 in 8–10,000 females. The *FMR1* gene on the long arm of the X chromosome causes an instable, fragile site at Xq27.3, where these chromosomes are easily broken. The sites can be detected by DNA analysis.

Mitochondrial DNA mutations

The known effects of mitochondrial DNA (mtDNA) mutations, transmitted by the mother, are mostly metabolic and apparently degenerative diseases. Since mitochondria are present in all cells with nuclei, every tissue or organ may be involved in mtDNA mutations. Most frequently, the brain, the heart and skeletal muscles are affected; therefore, these disorders are usually described as ***mitochondrial encephalomyopathies***. A better term may be ***defects*** of ***oxidative phosphorylation*** (***OXPHOS defects***), since all tissues and organs may be affected (Zeviani et al. 1998; Smeitink and van den Heuvel 1999). Many patients present the first symptoms before the age of 2 years. In general, OXPHOS defects are progressive and fatal disorders. The clinical features in patients suffering from OXPHOS defects are highly variable, but a well-recognized phenotype and in fact prototype of this large group of disorders is Leigh syndrome. ***Leigh syndrome*** (Leigh 1951) or subacute necrotizing encephalomyopathy is a progressive subcortical disorder, characterized by multifocal, bilateral areas of subtotal necrosis in the basal ganglia, the brain stem tegmentum, the cerebellum and to some extent the spinal cord (Chap. 9). Movement disorders of any type, including hypokinetic-rigid syndrome, chorea, myoclonus or dystonia, may be most obvious.

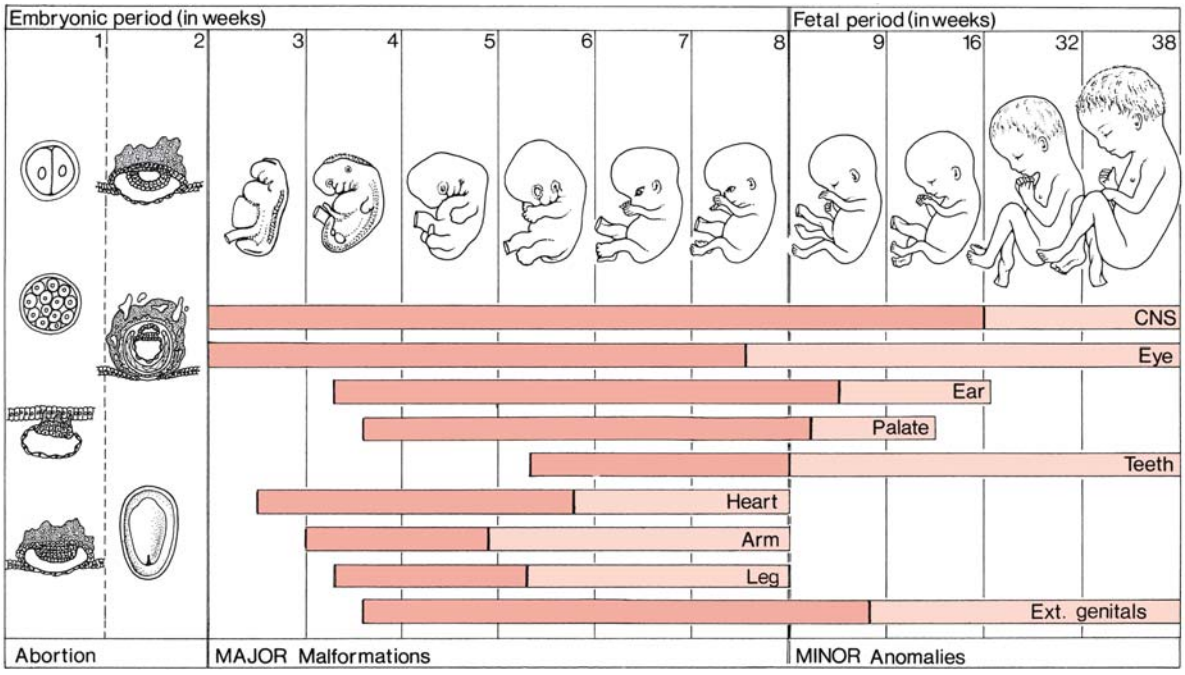

Fig. 3.6 Critical periods in human development and the site of action of teratogens. During the first 2 weeks of development, teratogenic factors destroy most cells of the embryo, resulting in the death of the embryo and spontaneous abortion. Alternatively, only a few cells are destroyed, the embryo recovers, and does not show malformations afterwards. In the *horizontal columns*, the period of major complications is shown in *red*, that of minor anomalies in *light red*. (After Moore and Persaud 1998)

Multifactorial Disorders

Common congenital malformations such as cleft lip with or without cleft palate and neural tube defects have a familial distribution consistent with **multifactorial inheritance**, suggesting that the disease is due to the interaction of different genes and environmental factors. Such disorders occur with increased frequency among family members of an affected individual in an inverse frequency to their relationship. A mathemathical 'liability' model invoking a threshold effect can be constructed and recurrence risks in the offspring of family members calculated. The recurrence risks used for genetic counselling of families with congenital anomalies determined by multifactorial inheritance are empirical risks based on the frequency of the anomaly in the general population and in different categories of relatives. In individual families, such estimates may be inaccurate, because they are usually averages from the population rather than precise probabilities for the individual family. **Digenic inheritance** in human diseases has been demonstrated in an increasing number of diseases (Ming and Muenke 2002), including retinitis pigmentosa, deafness, Hirschsprung disease, Usher syndrome, Waardenburg syndrome type 2 and holoprosencephaly.

3.2.2 Environmental Causes

Teratogenic factors have an adverse, disruptive effect on an embryo or a fetus between fertilization and birth. The term teratogen is usually limited to environmental agents, such as drugs, radiation and viruses. The disruptive effects include congenital abnormalities, embryonic and fetal death, intrauterine growth retardation (IUGR) and mental dysfunction. Critical periods in human development and the site of action are shown in Fig. 3.6. The fetus is less sensitive to morphological alterations than the embryo, but changes in functional capacity, intellect, reproduction or renal function may occur. Mechanical effects may be due to vascular disruptions and the amnion disruption sequence.

Chemicals, Drugs, Hormones and Vitamins

Drugs with a known teratogenic effect are relatively few (Gilbert-Barness and Van Allen 1997; Laxova 1997; Shepard 1998; Moore et al. 2000). Examples include alcohol, cocaine, thalidomide, lithium, retinoic acid, warfarin and anticonvulsant drugs (Table 3.5). ***Retinoic acid syndrome*** malformations first appeared after the introduction of Accutane (13-*cis*-retinoic

Table 3.5 Some drugs and infectious agents with teratogenic effects (after Gilbert-Barness and Van Allen 1997; Laxova 1997; Moore et al. 2000)

Agent	Mechanism of action	Most common congenital anomalies	Prenatal detection
Drugs			
Alcohol	Increased cell death	Fetal alcohol syndrome: IUGR; CNS abnormalities; characteristic facial expression	Ultrasound for growth, anomalies
Aminopterin and antifolates	Disrupted cell division	IUGR; skeletal defects; malformations of the CNS, notably meroanencephaly	Ultrasound for anomalies
Cocaine	Vasoconstriction	IUGR; prematurity; microcephaly; cerebral infarction; neurobehavioural disorders	High-risk care
Isotretinoin (13-*cis*-retinoic acid or Accutane)	Excessive cell death	Retinoic acid syndrome: craniofacial malformations; NTDs; cardiovascular defects	Ultrasound
Lithium carbonate		Right heart defects; increased incidence of NTDs	Fetal echo-cardography
Methotrexate	Increased cell death	Multiple anomalies, especially skeletal (face, skull, limbs, vertebral column); hydocephalus; meningomyelocele; cleft palate	Ultrasound
Phenytoin (Dilantin)	Increased cell death	Fetal hydantoin syndrome: IUGR; microcephaly; mental retardation; cleft lip/palate	Ultrasound
Thalidomide	Abnormal cell division	Abnormal development limbs (meromelia, amelia)	Ultrasound
Valproic acid		Craniofacial anomalies; NTDs; often hydrocephalus	
Warfarin	Impaired calcium and vitamin K metabolism	Fetal warfarin syndrome: nasal hypoplasia; stippled epiphyses; eye anomalies; mental retardation	Ultrasound
Chemicals			
Methylmercury		Minimata disease: cerebral palsy; microcephaly; mental retardation; blindness	
Polychlorated biphenyls		IUGR; skin discoloration	
Infections			
Cytomegalovirus		Microcephaly; hydrocephaly; cerebral palsy; chorioretinitis; sensorineural loss; psychomotor/mental retardation	Ultrasound
Herpes simplex virus		Chorioretinitis; hydranencephaly	
Human immuno-deficiency virus		Growth failure; microcephaly; prominent forehead; flattened nasal bridge; hypertelorism	Ultrasound
Rubella virus		IUGR; heart abnormalities; eye defects; hearing loss	
Toxoplasma gondii		Microcephaly; mental retardation	
Treponema pallidum		Hydrocephalus; congenital deafness; mental retardation	Ultrasound
Varicella virus		Hydrocephalus; limb paresis; seizures; eye malformations; mental retardation	Ultrasound

IUGR intrauterine growth retardation, *NTDs* neural tube defects

acid), a drug used for the treatment of severe cystic acne (Lammer et al. 1985). Although the retinoids (the normal biologically active retinoic acid and related compounds such as vitamin A, the dietary precursor of retinoic acid) had been long known to be potent teratogens, and the drug Accutane was not to be taken during pregnancy, in the USA many accidental exposures occurred, resulting in a surprisingly high incidence of severe craniofacial malformations (Lammer et al. 1985; Jones 1997; Gorlin et al. 2001; Chap. 5). Maternal chronic or excessive alcohol consumption, in particular during the first trimester of pregnancy, may lead to the ***fetal alcohol syndrome*** (Clarren et al. 1978; Gilbert-Barness and Van Allen 1997). The newborn baby is small and may show craniofacial anomalies. Brain anomalies are variable

and unspecific, in contrast to the more common craniofacial anomalies. Hydrocephalus, agenesis of the corpus callosum, neural tube defects and porencephaly may be found (Gilbert-Barness and Van Allen 1997), and even holoprosencephaly has been noted (Bonnemann and Meinecke 1990).

Maternal Conditions

A variety of maternal diseases, either genetic or acquired, and deficiency states may affect the developing embryo. In other disorders, such as epilepsy, the therapy is most likely damaging. ***Maternal phenylketonuria*** (***PKU***) is the best documented example of a genetic disorder in the mother affecting her offspring when her serum phenylalanine level is elevated during pregnancy. Without a strict diet throughout pregnancy, the children of women with PKU have severe mental retardation, microcephaly and heart defects (Scriver and Kaufman 2001). ***Maternal diabetes mellitus type 1*** is a risk factor for all sorts of congenital anomalies. Good control can prevent birth defects, however. A high incidence of Down syndrome (Narchi and Kulaylat 1997) and caudal regression syndrome (Passarge and Lenz 1966; Williamson 1970) have been noted. Maternal connective tissue disorders, such as osteogenesis imperfecta and Ehlers–Danlos syndrome, are risk factors for early amnion disruption sequence. ***Radiation effects*** on the developing brain were extensively studied after the atomic bombings of Hiroshima and Nagasaki (UNSCEAR 1986; Otake et al. 1989, 1991; Schull et al. 1992). The most conspicuous effect on brain development is an increased occurrence of severe mental retardation, with or without microcephaly at specific gestational ages. The period between 8 and 15 weeks following fertilization appeared to be the most vulnerable. Schull et al. (1992) studied brain abnormalities in five of these mentally retarded individuals, using MRI. In the two patients exposed at the eighth or ninth week following fertilization, large areas of ectopic grey matter were seen, due to failure of neurons to migrate properly. The two individuals exposed in the 12th or 13th week showed no readily recognized ectopic grey areas but did show mild macrogyria, which implies some impairment in the development of the cortical zone. The one individual who was exposed in the 15th week did not show such changes. The brain was small with an apparently normal architecture. ***Hyperthermia*** during pregnancy can cause embryonic death, abortion, growth retardation and developmental defects (Edwards et al. 1995, 2003). Cell proliferation, migration, differentiation and apoptosis are all adversely affected by elevated maternal temperature, showing some similarity to the effects of ionizing radiation. The development of the CNS is especially vulnerable: a 2.5 °C elevation for 1 h during early neural tube closure in rats resulted in an increased incidence of craniofacial defects, whereas 2–2.5 °C elevation for 1 h during early neurogenesis in guinea pigs caused an increase in the incidence of microcephaly (Edwards et al. 1995). In general, thresholds and dose–response relationships vary between species. In humans, epidemiological studies suggest that an elevation of maternal body temperature by 2 °C for at least 24 h during fever can cause a range of developmental defects, but there is little information on the threshold for shorter exposures (Chambers et al. 1998; Edwards et al. 2003).

Infectious Agents

A number of infectious agents can affect the fetus, producing a range of effects from structural anomalies to mental retardation (Table 3.5). Classically, the TORCH group of infections (toxoplasmosis, rubella virus, cytomegalovirus and herpes/varicella virus) are screened for in the case of permanent cerebral impairment in the neonate (Becker 1992; Stray-Pedersen 1993; Sunderland 1993). But also infections with human immunodeficiency virus (HIV) and other agents may lead to permanent fetal injury. Microcephaly, hydrocephalus, hydranencephaly and cerebral calcifications are the sequelae most often found in the TORCH group of infections (Fig. 3.7), and lead to developmental delay, psychomotor retardation and seizures. Microphthalmia is also often noted in toxoplasmosis, rubella and HIV infection. Often the infection ultimately leads to destruction of cerebral tissue with the formation of cystic spaces in the brain. They have been described as porencephaly (Tominaga et al. 1996) and schizencephaly (Iannetti et al. 1998). When the border of cystic lesions is formed by dysplastic cortex such as polymicrogyria, cytomegalovirus infection should be suspected (Barth 2003). In all instances the nature and the degree of the brain disturbances is a function of the time of the infection. Early infections may lead to intrauterine death, lissencephaly may result from cytomegalovirus onset between 16 and 18 weeks of gestation, whereas polymicrogyria may be due to onset of infection between 18 and 24 weeks of gestation (Barkovich and Linden 1994; de Vries et al. 2004). If the fetus is aborted early, the lesions may be restricted to foci of macrophages around glial or neuronal cells with classical intranuclear viral inclusions. The CNS malformations observed in a case of cytomegalovirus infection are illustrated in Clinical Case 3.2. Rubella virus is embryopathic but also has a recognizable fetopathic effect. Its features are cardiac defects, congenital cataract and deafness. Intracerebral calcifications, visible on ultrasound and CT examination, should raise suspicion for an intrauterine infection.

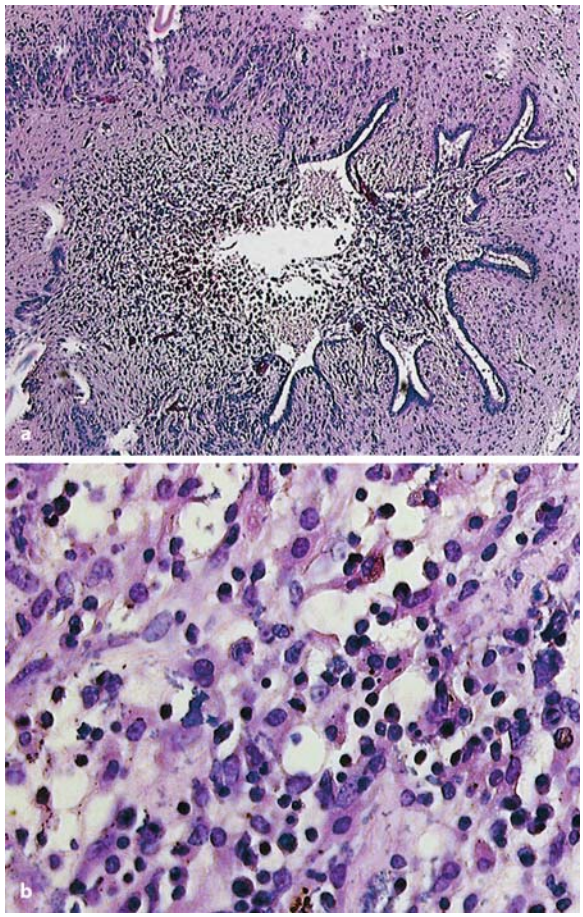

Fig. 3.7 Toxoplasmosis encephalopathy: **a** obstruction of the aqueduct by gliotic and inflamed tissue in intrauterine toxoplasmosis infection in a neonate; **b** detail of inflamed white matter (courtesy Caroline Van den Broecke, University Hospital Gent)

Mechanical Effects

Disruptions of the developing embryo and fetus are rather frequent (Gilbert-Barness and Van Allen 1997), and may arise as a result of vascular disruptions (e.g. Poland sequence), amnion rupture sequence (Van Allen et al. 1987a, b; Bamforth 1992; Moerman et al. 1992; Clinical Case 3.3) and less frequent mechanical effects due to invasive procedures for prenatal diagnosis (Squier et al. 2000; Squier 2002; Clinical Case 3.4) or pregnancy reduction. ***Amnion rupture sequence*** is a disruption sequence characterized by major anomalies of the craniofacial region, body wall,and limbs. The pathogenesis of these defects is unknown, but it is probably heterogeneous. Mechanisms involved may be vascular disruption (Van Allen et al. 1987a, b), mechanical disruption (Torpin 1965; Higginbottom et al. 1979), genetic disruption (Donnai and Winter 1989) and germ disc disruption (Streeter 1930).

3.3 Prenatal Diagnosis

Suspicion of a congenital malformation may arise on clinical grounds or because of an abnormal result from a routine prenatal investigation. A pregnancy may be at high risk of abnormality because of a particular family history or the advanced age of the mother. Higher-risk groups for chromosome abnormalities include older mothers, those with a previous chromosomally abnormal child, and when one parent is a translocation carrier. Usually, these women are offered chorion villus sampling or amniocentesis routinely. An increasing number of single gene disorders and chromosome abnormalities can now be identified at the molecular level. Population screening programmes may identify women at increased risk of fetal abnormalities (Brock et al. 1992; Laxova 1997; Nicolaides et al. 1992, 1999): second trimester serum test (triple test), first trimester serum test (double test) combined with nuchal translucency measurement on ultrasound examination, and the standard anomaly scan at 18–20 weeks of gestation. For instance, α-fetoprotein (AFP) escapes from the circulation into the amniotic fluid from fetuses with open neural tube defects and open ventral wall defects (gastroschisis, omphalocele). Measuring the level of AFP in amniotic fluid was first carried out for the prenatal diagnosis of neural tube defects. The various imaging methods for prenatal diagnosis will be briefly discussed.

3.3.1 Ultrasound and Magnetic Resonance Examination

High-frequency ultrasonography allows visualization of the normal and abnormal development of the embryo or fetus. However, detailed knowledge about early development of the embryo and fetus is a prerequisite for evaluation of the pregnancy at risk for genetic diseases of the fetus, or when abnormal development of the embryo or fetus is suspected (Blaas et al. 1994; Amin et al. 1999; Blaas and Eik-Nes 1999; Garel 2004; Chap. 1).

Ultrasound Examination of the Normal Spine

In normally developing embryos, the spine can be visualized from the eighth week of gestation onwards (van Zalen-Sprock et al. 1995). It is recognizable as two lines representing the not yet ossified vertebrae (Fig. 3.10a). Primary ossification of the vertebrae starts in the cervical spine and gradually extends caudally. Complete mineralization of the vertebrae is achieved between the 12th and 14th weeks of gestation; therefore, evaluation of the spine with ultrasound is possible from the 13th of gestation onwards.

Clinical Case 3.2
Cytomegalovirus Encephalopathy

Cytomegalovirus (CMV) infection affects the fetus and results in structural anomalies such as destruction of cerebral tissue with the formation of cystic spaces in the brain. Early CMV infections may lead to intrauterine death, lissencephaly may result from onset between 16 and 18 weeks of gestation, whereas polymicrogyria may be due to onset of infection between 18 and 24 weeks of gestation (Barkovich and Linden 1994; Tominaga et al. 1996; de Vries et al. 2004). The Case Report concerns an intrauterine fetal death at 33 weeks of gestation.

Case Report. The neuropathological findings in a case of intrauterine fetal death at 33 weeks of gestation from a 21-year-old mother are shown in Fig. 3.8. Intrauterine growth retardation was confirmed with ultrasound examination which further revealed ascites and oligohydramnios. A CMV infection was suggested. At autopsy, a male fetus of 793-g weight, 35-cm total length, 4.5-cm foot length and 4.5-cm femur diaphysis length, data comparable to those at 26 weeks of development, was examined. There was fetal hydrops and strong maceration. Generalized CMV infection was found of the lungs, kidneys, pancreas, thyroid, brain and placenta. Viral inclusions were easily recognized. The small placenta (250 g) showed a chronic villitis. The heart showed a perimembranous ventricular septal defect, a wide pulmonary trunk and interruption of the aortic arch between the left carotid and brachial arteries. The descending part of the aorta was continuous with the pulmonary trunk via the ductus arteriosus. The leptomeninges were thickened (Fig. 3.8 a, b). In the brain, polymicrogyria (Fig. 3.8 c) and periventricular necrosis with calcifications (Fig. 3.8 d) were found. Immunoperoxidase staining showed the viral organisms.

This case was kindly provided by Gerard van Noort (Laboratory for Pathology East-Netherlands, Enschede, The Netherlands).

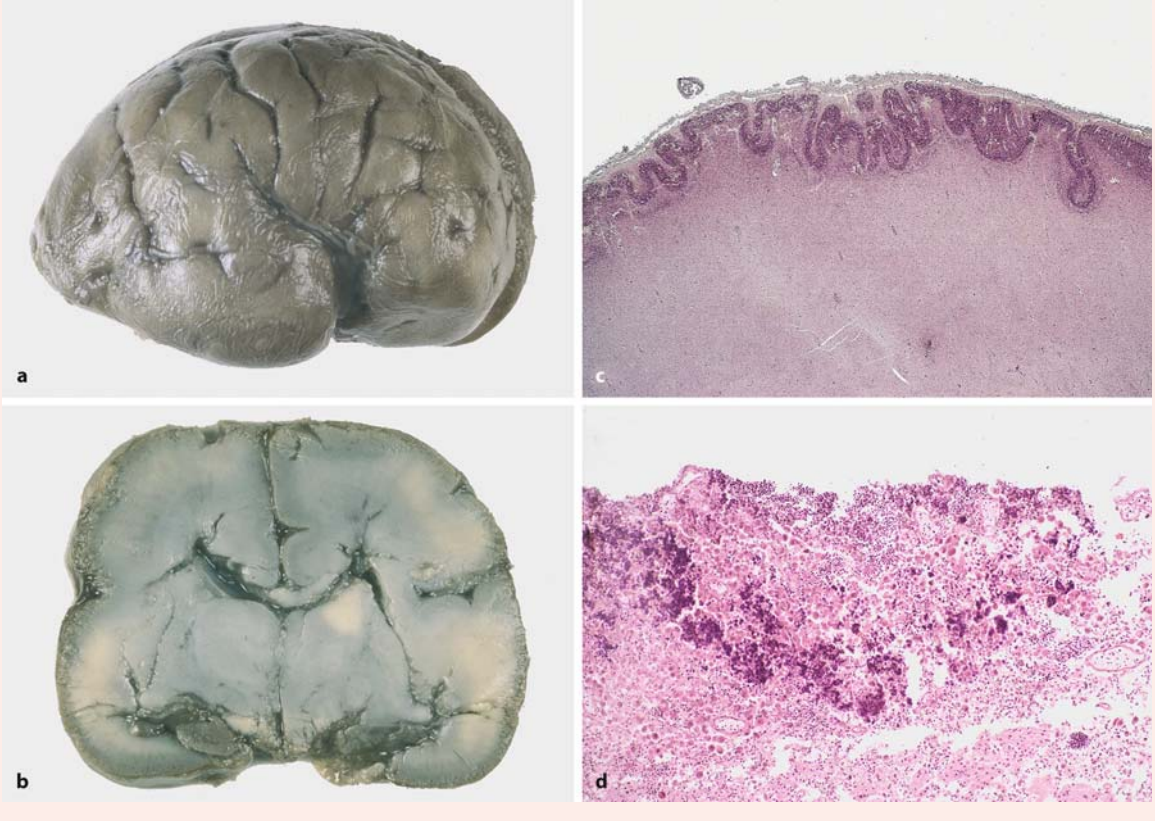

Fig. 3.8 Cytomegalovirus encephalopathy in a case of intrauterine fetal death at 33 weeks of gestation: **a**, **b** lateral view and frontal section of the brain showing thickened lerptomeninges; **c** polymicrogyria of the cerebral cortex; **d** periventricular necrosis with calcifications (courtesy Gerard van Noort, Enschede)

References

Barkovich AJ, Linden CL (1994) Congenital cytomegalovirus infection of the brain: Imaging analysis and embryonic considerations. AJNR Am J Neuroradiol 15:703–715

de Vries LS, Gunardi H, Barth PG, Bok LA, Verboon-Maciolek MA, Groenendaal F (2004) The spectrum of cranial ultrasound and magnetic resonance imaginig abnormalities in congenital cytomegalovirus infection. Neuropediatrics 35:113–119

Tominaga I, Kaihou M, Kimura T, Onaya M, Kashima H, Kato Y, Tamagawa K (1996) Infection foetale par le cytomégalovirus. Porencéphalie avec polymicrogyrie chez un garçon de 15 ans. Rev Neurol (Paris) 152:479–482

The curled position of the embryo in the first trimester requires consecutive scanning planes to visualize the entire spine. In the second trimester of pregnancy, the vertebrae and spinous processes are visible in the sagittal plane as a double row of elements, converging caudally into the sacrum (Fig. 3.10b). In the transverse plane the neural canal appears as a closed circle, which is lined anteriorly by the vertebral body and posteriorly by the two ossification centres of the laminae. A coronal scan shows the typical three-lined appearance of the vertebrae (Fig. 3.10c).

Ultrasound Examination of the Normal Brain

At 6 weeks of gestation, when the secondary brain vesicles are being formed, the embryonic cephalic pole is clearly visible and distinguishable from the embryonic torso (Achiron and Achiron 1991). The cavity of the rhombencephalon is one of the first 'structures' of the embryonic CNS that can be visualized with transvaginal ultrasound (Fig. 3.10e). The rhombencephalic cavity is no longer recognizable after 10–12 weeks of gestation. From 10 weeks onwards, in the fetal head a symmetric, butterfly-like structure (the choroid plexuses) can be seen (Fig. 3.10f), divided by a thin straight hyperechogenic line (the falx cerebri). The choroid plexuses become considerably reduced in size from the 18th week of gestation onwards. From 15–16 weeks of gestation onwards, the central parts (the atria) and the frontal horns of the lateral ventricles are clearly visible. The brain parenchyma is still translucent and hardly distinguishable. From 26 weeks of gestation, the brain parenchyma becomes more hyperechogenic (Fig. 3.11a). In the posterior cranial fossa, the hypoechogenic cerebellar hemispheres can easily be seen on each side of the echogenic midline vermis, rostral to the cisterna magna (Fig. 3.11b). The cerebellum is detectable from 14 weeks of gestation onwards. Imaging of the posterior fossa is important for exclusion of nearly all open spinal defects (see also Chap. 4).

Ultrasound Examination of the Abnormal Spine and Brain

The incidence of abnormalities of the fetal CNS has been estimated at approximately 5–6 per 1,000 births. Overall, the best detection rates by ultrasound are found for CNS abnormalities. The sensitivity of detecting CNS abnormalities by ultrasound is about 90% (Chitty et al. 1991; Levi 1998; Grandjean et al. 1999). ***Neural tube defects*** are the most common CNS abnormalities likely to be diagnosed by ultrasound. ***Anencephaly*** can be recognized by failure of development of the fetal skull vault with secondary degeneration of the brain (Fig. 3.11c). In the first trimester of pregnancy, the fetus shows acrania with the brain being either normal or disorganized and often incompletely formed (Fig. 3.11d). The malformation progresses through exencephaly into anencephaly in the second and third trimesters of pregnancy (Wilkins-Haug and Freedman 1991; Chap. 4). The facial bones, brain stem and portions of the occipital bone and midbrain are usually present. Associated spinal defects are found in about 50% of cases. A high detection rate of up to 99% is reported for anencephaly (Levi 1998). In ***spina bifida***, the neural arch is incomplete with secondary damage to the exposed spinal cord (Fig. 3.10d). Most lesions occur in the lumbosacral and sacral region, fewer in the thoracolumbar region and only a few in the cervical region (Van den Hof et al. 1990). The effectiveness of ultrasound in diagnosing spinal defects has been greatly improved by the recognition of associated intracranial abnormalities: (1) the changing shape of the skull vault from egg-shaped to lemon-shaped (Fig. 3.11e) with indentation of the frontal lobes bilaterally (Nicolaides et al. 1986); (2) changes that can be seen in the posterior fossa with an alteration of the shape of the cerebellum from a typical dumbbell shape to a 'banana' shape, owing to compression of the cerebellum in the posterior fossa (Fig. 3.11f); and (3) the possible presence of ventriculomegaly. The 'lemon' and 'banana' signs are seen in cases with an open spina bifida before 24 weeks of gestation. With the transvaginal ultrasound technique, spina bifida can already be diagnosed by the end of the embryonic period (Blaas et al. 2000). An ***encephalocele*** is characterized by a defect in the skull and dura through which

Clinical Case 3.3
Amnion Rupture Sequence

Amnion rupture causes constrictive bands with subsequent entanglement of fetal parts (mostly the limbs) by amniotic strands (Jones et al. 1974). Adhesive bands are the result of a broad fusion between disrupted fetal parts (mostly craniofacial) and an intact amniotic membrane. Most of the craniofacial defects, such as encephaloceles and/or facial clefts, that are found in these fetuses are not caused by constrictive amniotic bands but are due to a vascular disruption sequence with or without cephalo-amniotic adhesion (Bamforth 1992; Moerman et al. 1992). The combination of complex, atypical facial clefts, not strictly following embryogenetic patterns, and unusually large asymmetric encephaloceles should raise suspicion for amnion rupture sequence (see Case Report).

Case Report. Ultrasound examination of the first pregnancy of a 27-year-old mother revealed multiple malformations at 23 weeks of gestation; therefore, abortion was induced. Owing to the large size of the occipital encephalocele, some 30 ml of haemorrhagic brain tissue had to be extruded before a female fetus was born. Apart from the occipital encephalocele that was partly attached to the umbilical cord, an asymmetric face with cheilognathopalatoschisis, contractures of both ankle joints, an inverted flexed right foot and a hyperextended left foot were found (Fig. 3.9). Asymmetric hypertelorism was present with normal eyes and a single nostril on the left. Above the right eye there was a defect of 6 mm in diameter in the frontal and ethmoid bones through which some brain tissue protruded. A large, partly collapsed occipital encephalocele contained the larger part of the right cerebral hemisphere with the hippocampus and basal ganglia. The tentorium cerebelli could not be found. Infratentorial tissue was absent, probably lost during the difficult birth. The medial side of the right hemisphere showed some neuronal migration disturbances. Otherwise the brain was normally structured. Despite the extensive midline defects, there were no signs of holoprosencephaly. The other viscera were without gross malformations. The placenta was, apart from a small infarction, normally structured. The umbilical cord contained two arteries and one umbilical vein. At places, the umbilical cord was covered with multiple folds of fibrotic and focally calcified amniotic bands.

References

Bamforth JS (1992) Amniotic band sequence: Streeter's hypothesis re-examined. Am J Med Genet 44:280–287

Jones KL, Smith DW, Hall BD, Hall JG, Ebbin AJ, Massoud H, Golbus MS (1974) A pattern of craniofacial and limb defects secondary to aberrant tissue bands. J Pediatr 84:90–95

Moerman P, Fryns J-P, Vandenberghe K, Lauweryns JM (1992) Constrictive amniotic bands, amniotic adhesions, and limb-body wall complex: Discrete disruption sequences with pathogenetic overlap. Am J Med Genet 42:470–479

the meninges herniate with or without skin covering (Chap. 4). The meningeal sac can contain brain tissue (an encephalocele) or only cerebrospinal fluid (a meningocele). In the majority of cases a bone defect of the skull can be recognized (Fig. 3.12a).

Malformations of the ***cerebrum*** that can be visualized by ultrasound include ventriculomegaly, holoprosencephaly, schizencephaly and porencephaly. ***Ventriculomegaly*** means enlargement of the intracranial ventricular system. It is distinct from hydrocephalus in which not only enlargement but also raised pressure within the ventricular system is found (Nyberg et al. 1987). Ventriculomegaly is defined as dilatated central parts (atria) of the lateral ventricles of 10 mm or more, at any gestation time, measured in a transverse plane at the level of the cavum septi pellucidi (Cardoza et al. 1988; Fig. 3.12b). In most cases, ventriculomegaly is caused by an obstruction of the circulation of the cerebrospinal fluid. Associated sonographic features such as a 'dangling choroid plexus' and an enlarged third ventricle may be present. Ventriculomegaly may not be apparent until the second or third trimester of pregnancy. The corpus callosum can be visualized on ultrasound, but it should be emphasized that it forms rather late in development and has not formed entirely before 20 weeks of gestation (Chaps. 1, 10); therefore, accurate diagnosis of ***agenesis*** of the ***corpus callosum*** can only be made after that time. In routine scanning, agenesis of the corpus callosum is suspected by detection of focal dilatation of the posterior horns of the lateral ventricles (teardrop configuration), absence of the cavum septi pellucidi and a high-riding third ventricle (Parrish et al. 1979).

Holoprosencephaly is a failure of the development of midline forebrain structures that is usually classified into alobar, semilobar and lobar forms (Chap. 9). In the alobar form, a monoventricle and non-separation of the thalami are found (Fig. 3.12c), whereas the non-separation of these structures declines in the

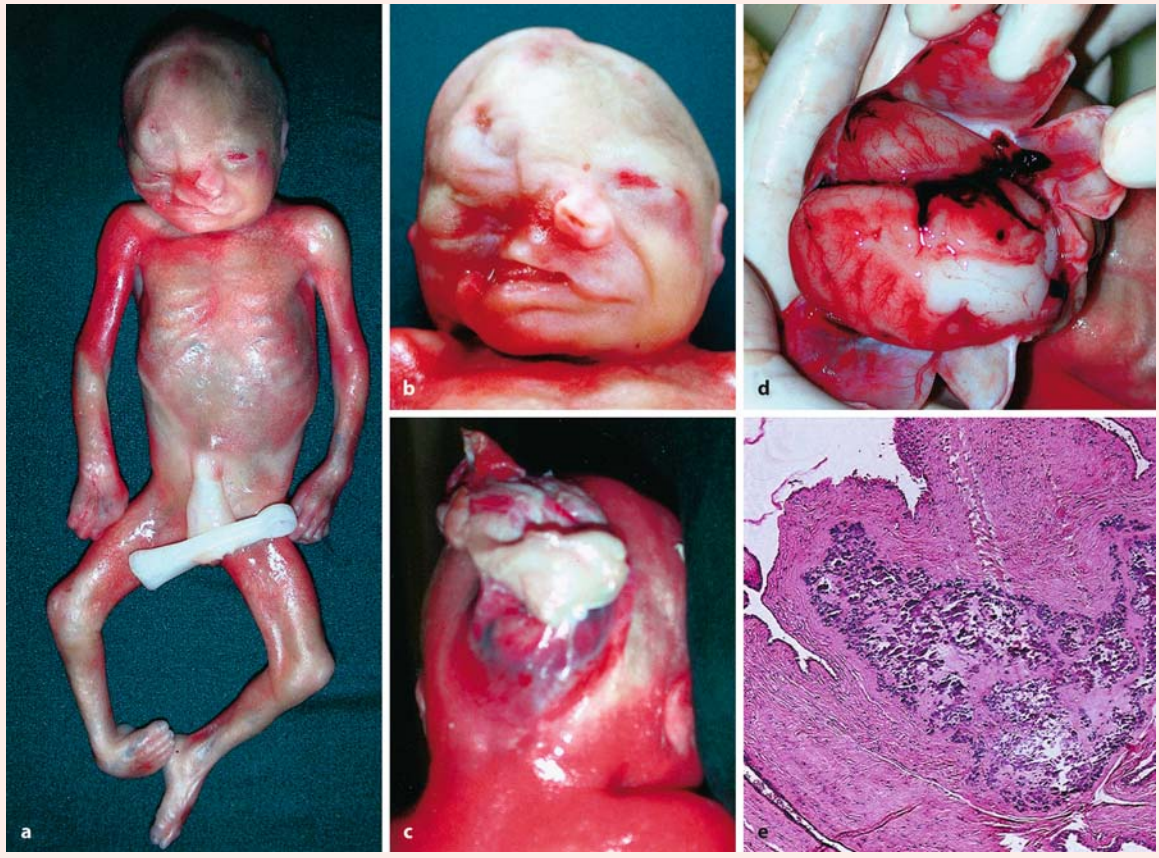

Fig. 3.9 Amnion rupture sequence in a fetus of 23 gestational weeks: **a** overview of malformations; **b** malformed craniofacial region; **c** occipital encephalocele; **d** the brain after opening of the skull; **e** detail of calcified amniotic band (courtesy Martin Lammens, Nijmegen)

semilobar and lobar forms (Chap. 9). Holoprosencephaly is usually associated with craniofacial malformations such as brachycephaly, microcephaly and abnormal facial development (Chap. 5). The detection rate by routine fetal anomaly scan is high for both the alobar and semilobar forms of holoprosencephaly, even in the first trimester (Blaas et al. 2002). In ***schizencephaly***, mostly bilateral clefts can be seen as translucent areas extending from the dilatated lateral ventricles to the subarachnoid space.

Malformations of the ***cerebellum*** detectable by ultrasound include the Dandy–Walker complex and cerebellar hypoplasias (Chap. 8). The ***Dandy–Walker complex*** refers to a spectrum of abnormalities of the cerebellar vermis, cystic dilatation of the fourth ventricle and enlargement of the cisterna magna (Barkovich et al. 1989; Chap. 8). The ***Dandy–Walker malformation*** is characterized by failure of development of the cerebellar vermis with a midline cyst-like appearance in the posterior fossa with communication between the fourth ventricle and the enlarged cisterna magna (Fig. 3.12 d).

Anomalies of the ***choroid plexuses*** detectable by ultrasound are rather common. ***Choroid plexus cysts*** are found in approximately 1–2 % of fetuses in a low-risk population (Chitty et al. 1998) and in 1 in 150–200 fetuses of 16–18 gestational weeks (Kraus and Jirásek 2002). On ultrasound, choroid plexus cysts with a variable diameter are detected as hypoechoic structures within the body of the choroid plexus (Fig. 3.12 e). The majority will resolve by 24–28 weeks of gestation (Chitkara et al. 1988; Chitty et al. 1998). It is generally accepted that such cysts reflect a normal variation of the intracranial anatomy. An ***aneurysm*** of the ***vein*** of ***Galen*** is a rare vascular malformation of the choroid plexus within the roof of the third ventricle. Arteriovenous fistulas from the choroidal, anterior cerebral and other arteries to the vein of Galen lead to the aneurysmal dilatation of the vein (Fig. 3.12 f). On ultrasound, a large midline

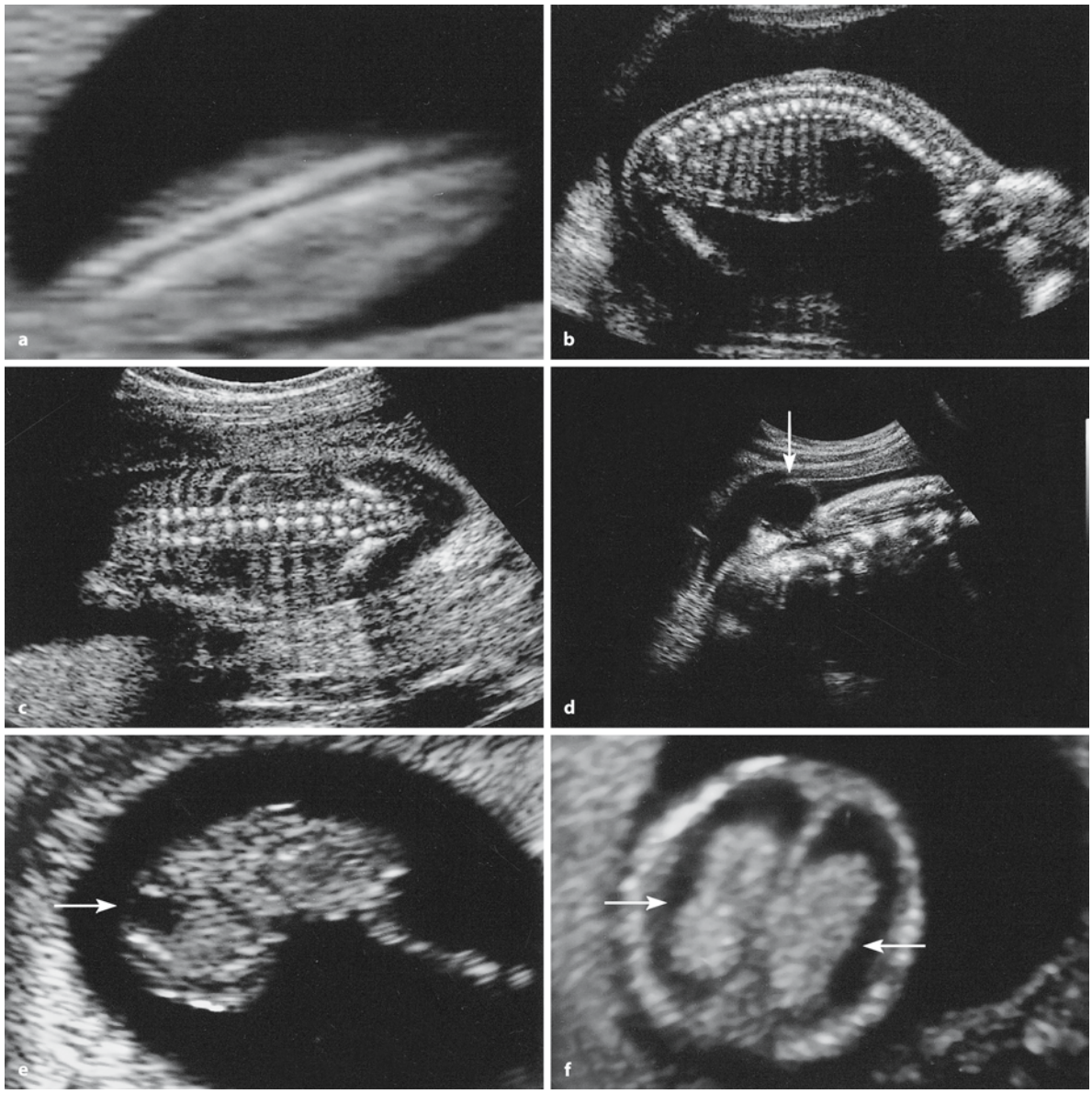

Fig. 3.10 Normal and abnormal ultrasound scans: **a** transvaginal ultrasound of 11-week-old fetal spine; **b** sagittal view of second-trimester normal fetal spine; **c** coronal view of second-trimester normal fetal spine; **d** spina bifida with meningocele (*arrow*) in lumbosacral region; **e** cavity of the rhombencephalon (*arrow*) in a 6-week-old embryo; **f** normal choroid plexuses (*arrows*) in an 11-week-old fetus (**b**, **c** courtesy Monique Haak; **d** courtesy Mireille Bekker, Amsterdam)

cystic structure above the thalamus can be seen. With colour Doppler investigation a turbulent blood flow can be demonstated (Gerards et al. 2003).

Three-Dimensional Ultrasound

Three-dimensional ultrasound can be used for surface reconstruction, multiplanar image analysis and volume calculation (Blaas 1999; Pooh et al. 2003). The surface mode shows not only fetal head anomalies such as acrania but also the normal structure of cranial bones and sutures. Rotation of brain volume image and multiplanar analysis enable tomographic visualization as MRI. The planes obtained are comparable to sections obtained by CT or MRI (Monteagudo et al. 2000). Three-dimensional ultrasound provides the ability to simultaneously view a brain volume in all three scanning planes. In spinal defects, the three orthogonal planes proved to be most helpful in delineating the exact nature and level of the defect.

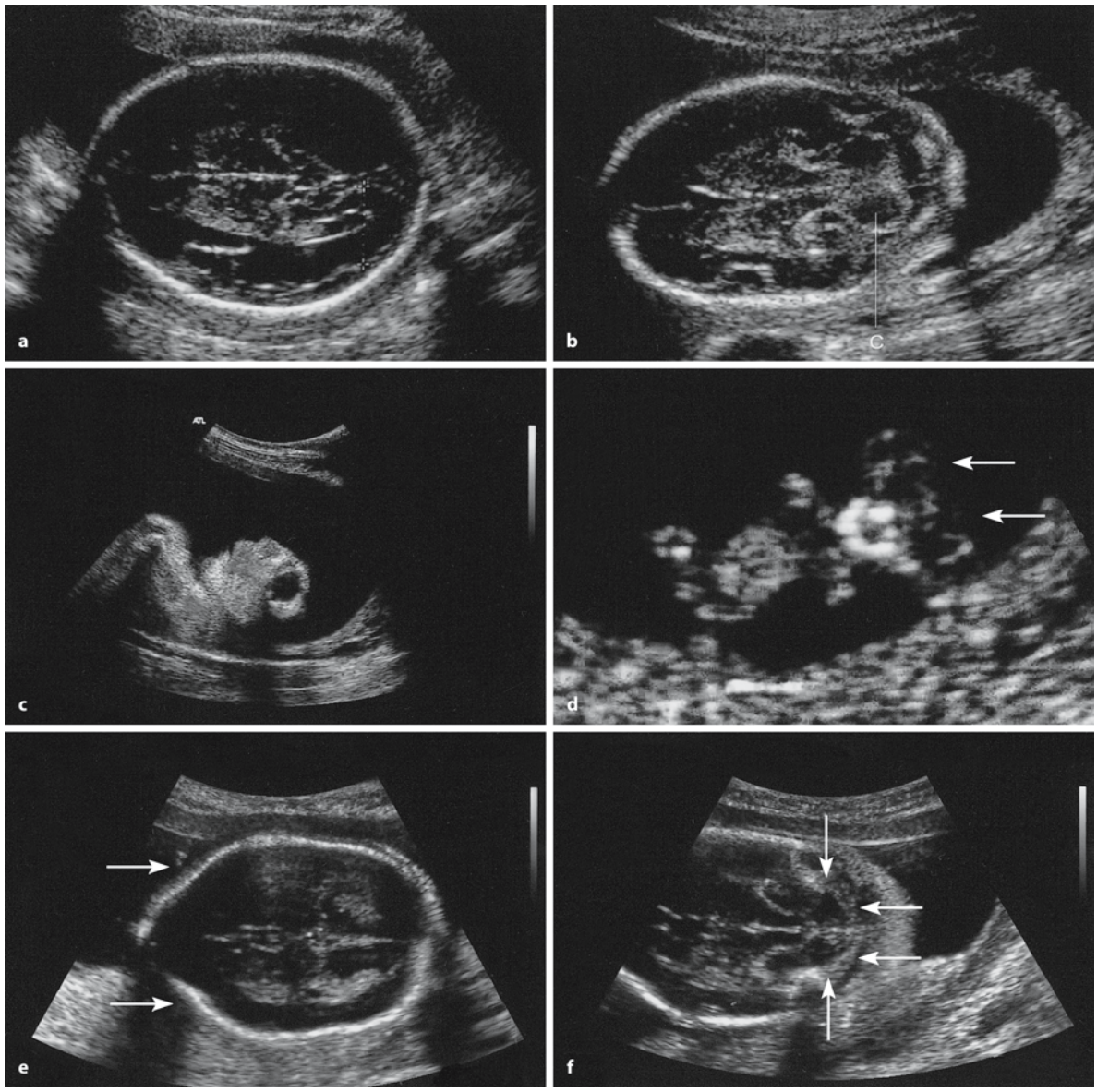

Fig. 3.11 Normal and abnormal ultrasound scans: **a** transverse plane with view of normal brain parenchyma in a second-trimester fetus; **b** transverse plane with view of the cerebellum; **c** fetus with anencephaly; **d** first-trimester fetus with exencephaly (*arrows*); **e** frontal denting: 'lemon' sign (*arrows*) in fetus with spina bifida in the lumbosacral region; **f** Chiari II malformation: 'banana' sign (*arrows*) in fetus with spina bifida (**a**, **b** courtesy Monique Haak, Amsterdam; **e**, **f** courtesy Mireille Bekker, Amsterdam)

Magnetic Resonance Imaging

Ultrasonography is the method of choice for prenatal scanning of fetal anomalies; however, there remain circumstances in which ultrasound data obtained are limited or technically difficult, for example in maternal obesity, oligohydramnios and unfavourable position of the fetus. Moreover, ultrasound examination of the fetal CNS is limited because of the non-specific appearance of some abnormalities and ossification of the fetal skull. Some subtle parenchymal abnormalities cannot be seen on ultrasound (Poutamo et al. 1999). MRI may be a useful adjuvant when ultrasound examination is indeterminate. Fetal MRI is hindered by fetal motion and long acquisition times, but ultrafast MRI with scan times of less then 1 s greatly decreases motion artefacts. MRI has proved to be especially useful in the evaluation of the fetal CNS (Levine et al. 1999; Garel 2004; Chap. 1).

MRI is especially useful in cases in which fetal ventriculomegaly (Fig. 3.13a) is associated with other

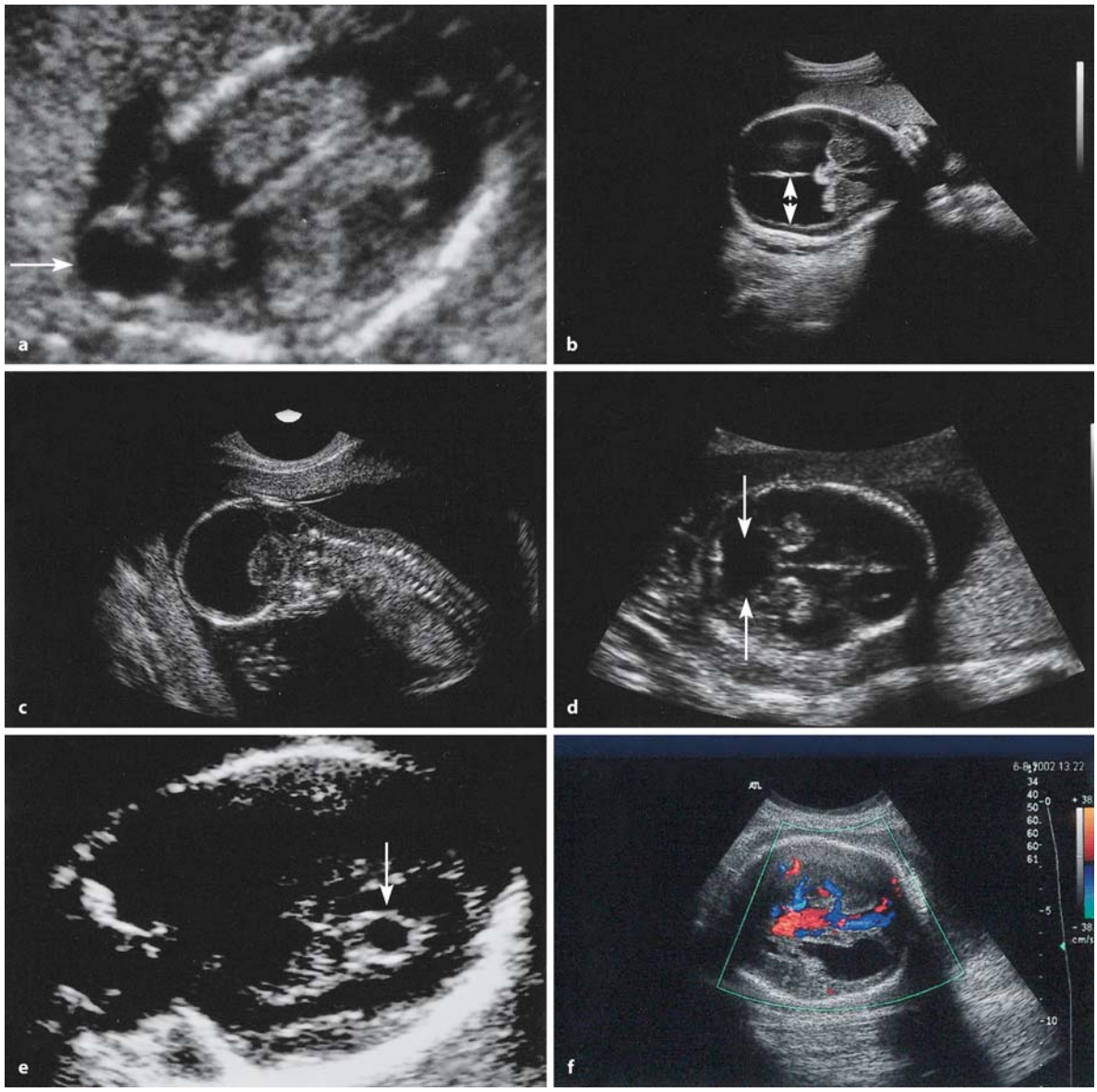

Fig. 3.12 Normal and abnormal ultrasound scans: **a** 12-week-old fetus with encephalocele (*arrow*); **b** second-trimester fetus with ventriculomegaly (*arrows*); **c** fetus with alobar form of holoprosencephaly; **d** Dandy–Walker malformation (*arrows*; **e** choroid plexus cyst (*arrow*); **f** colour Doppler of vein of Galen malformation (**b**–**d** courtesy Melanie Engels, Amsterdam; **f** courtesy Franca Gerards, Amsterdam)

CNS malformations and anomalies outside the CNS (Wagenvoort et al. 2000). Agenesis of the corpus callosum is also such an anomaly easily missed on ultrasound examination, although it is often suspected by indirect signs, that can be visualized with MRI (Levine et al. 1997; Fig. 3.14). In fetuses with arachnoid or other cerebral cysts, MRI contributes to defining the extent of the cyst and its relationship to surrounding structures (Fig. 3.13 b). With ultrasound it may be difficult to distinguish between hydrocephalus and mild forms of holoprosencephaly. With MRI (Fig. 3.13 c), all forms of holoprosencephaly can be visualized (Hubbard et al. 1999). MRI evaluation of the posterior cranial fossa is not hindered by the engagement of the fetal head, especially not in the third trimester. Other anomalies such as lissencephaly and schizencephaly, and also more subtle parenchymal migration disorders such as heterotopia and polymicrogyria have been visualized with MRI (Levine and Barnes 1999; Garel 2004). Fetal intracranial haemorrhage can be detected with MRI (Fig. 3.13 d). The signal intensity of the bleeding varies with its duration (Zanders et al. 2003). Recently developed techniques such as diffusion-weighted imaging, which makes it

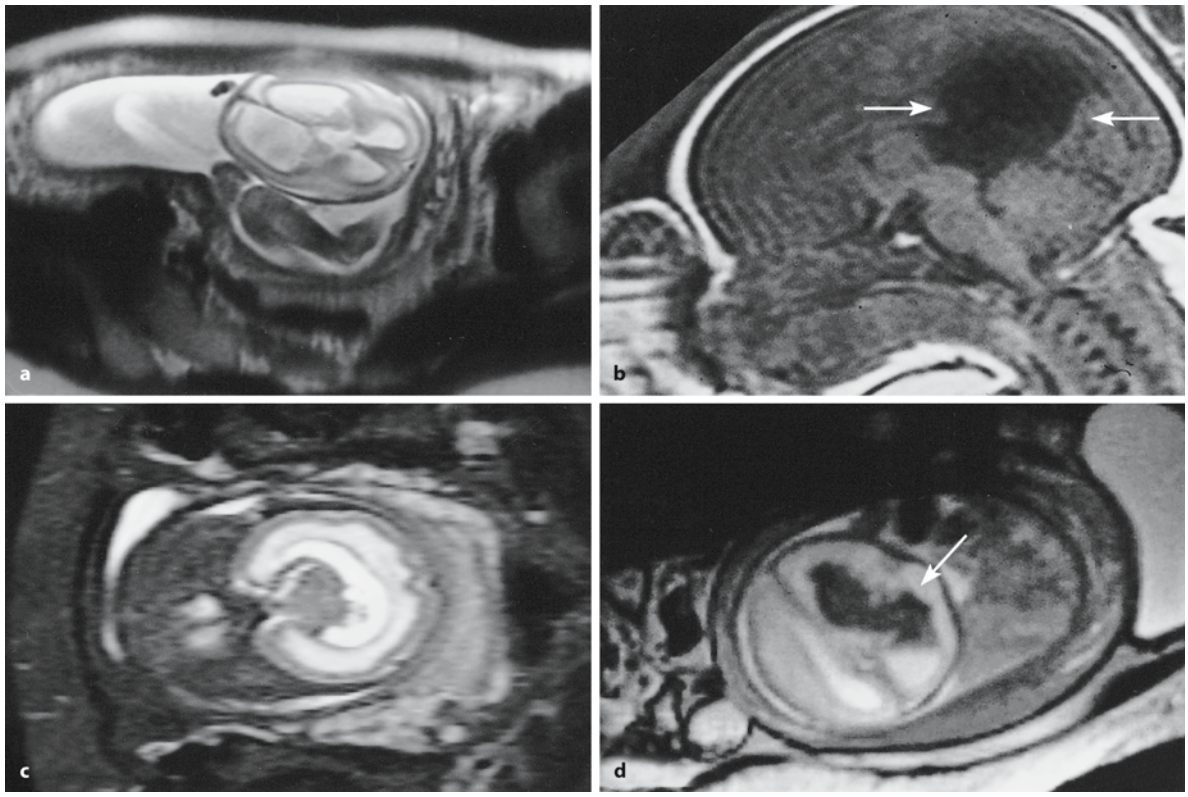

Fig. 3.13 Fetal MRI: **a** ventriculomegaly; **b** arachnoid cyst (between *arrows*); **c** holoprosencephaly; **d** intracranial haemorrhage (*arrow*)

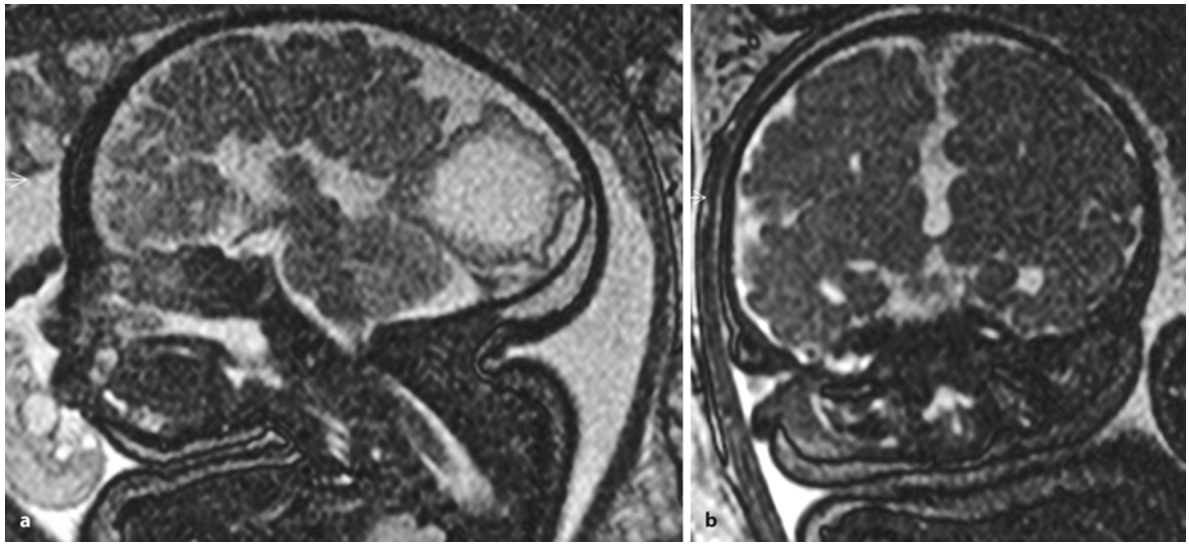

Fig. 3.14 MRI of callosal agenesis in a fetus of 36 gestational weeks: **a** sagittal view showing a high third ventricle, colpocephaly (dilatation of occipital horn) and radial patterning of medial cortex; **b** frontal section (courtesy Berit Verbist, Leiden)

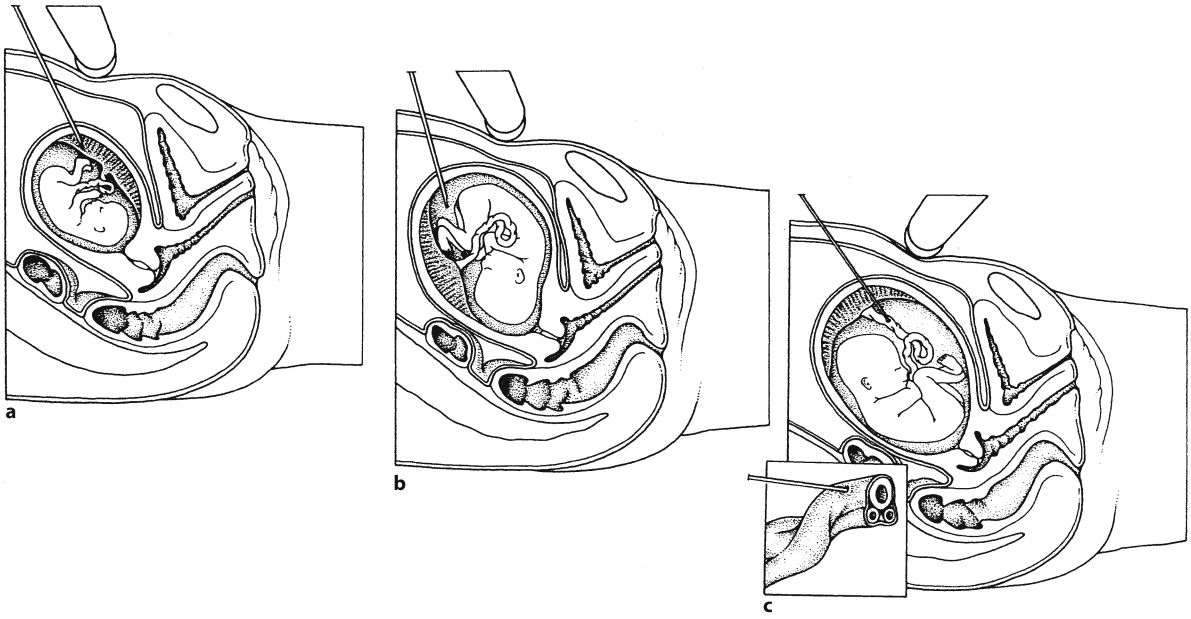

Fig. 3.15 Invasive sampling tests: **a** chorion villus sampling, **b** amniocentesis; **c** fetal blood sampling from the umbilical cord

possible to detect hypoxic brain regions, provide the opportunity to assess fetuses at risk from intrauterine growth restriction, pre-eclampsia of the mother or the twin-to-twin transfusion syndrome. MRI is also helpful in cases with spinal defects to delineate the precise defect and therefore may play a role in fetal surgery for such defects (Sutton et al. 2001).

3.3.2 Invasive Tests

Various invasive sampling techniques for prenatal diagnosis are available (Fig. 3.15): chorion villus sampling, amniocentesis and fetal blood sampling. ***Chorion villus sampling*** can be carried out during the first trimester and presents the possibility of an early termination of pregnancy. Biopsies of chorionic villi may be obtained by a transcervical or a transabdominal approach (Fig. 3.15a). For safety chorion villus sampling is usually carried out after 11 weeks of gestation. It is used for detecting chromosomal abnormalities, DNA analysis, inborn errors of metabolism and X-linked disorders. Karyotyping of aspirated/biopsied chorionic villi can be performed both from direct examination or from short-term culture of the cytotrophoblast and/or long-term culture of fibroblasts from the core of the villus. Complications of chorion villus sampling are, apart from reliability, maternal cell contamination and confined placental mosaicism, increased miscarriage risk and fetal injury, especially oromandibular/limb hypogenesis syndrome and transverse limb reduction defects, the latter when chorion villus sampling is carried out before 10 weeks of gestation (Boyd et al. 1990; Quintero et al. 1992; Firth 1997; Keeling and Boyd 2001).

Amniocentesis has been performed for much longer than chorion villus sampling and is the most common invasive prenatal diagnostic procedure (Fig. 3.15b). A 15–20-ml aliquot of amniotic fluid is taken transabdominally under ultrasound guidance, usually between 14 and 16 weeks of gestation. Indications for amniocentesis are similar to those for chorion villus sampling, but amniocentesis provides also the possibility to analyse AFP in the amniotic fluid as an indicator for neural tube defects. The vast majority of amniocenteses are performed because of increased risk of Down syndrome in women aged over 35 years or in younger women with a positive result from biochemical (AFP) screening or those with a suspicion of abnormality on ultrasound examination. The reliability of amniocentesis is very accurate. A miscarriage risk of 0.5–1.4% has been found in large studies but it may be higher (Nicolaides et al. 1999). Fetal damage is rare, but documented (Squier et al. 2000; Squier 2002; Clinical Case 3.4). ***Fetal blood sampling*** may be used at about 20 weeks of gestation for chromosomal analysis when ultrasound or other invasive tests have shown a fetal anomaly. It is carried out transabdominally from the umbilical cord (Fig. 3.15c) or a transplacental route into an umbilical cord vessel at the placental insertion if the placenta is anterior. Fetal blood sampling is not routinely done but miscarriage risk in experienced hands is in the order of 1.5%.

Clinical Case 3.4
Traumatic Amniocentesis

Although fetal injury after amniocentesis has been reported, reports of brain injury are rare. Squier and coworkers (Squier et al. 2000; Squier 2002) described five cases of brain injury following amniocentesis in midterm pregnancy. One of these cases is presented as the Case Report.

Case Report. The dramatic effects of a traumatic amniocentesis at 16 weeks of gestation are shown in Fig. 3.16. The baby had a scar on the left side of the scalp, and developed hemiplegia and intractable epilepsy. MRI showed atrophy of the left cerebral hemisphere, a defect in the rostral part of the corpus callosum and cortical thickening in the left Sylvian fissure with underlying neuronal heterotopia. Hemispherectomy was performed to relieve the severe epilepsy.

The case was kindly provided by Waney Squier (Department of Neuropathology, The Radcliffe Infirmary, Oxford, UK; with permission from the publisher).

References

Squier W (2002) Pathology of fetal and neonatal brain damage: Identifying the timing. In: Squier W (ed) Acquired Damage to the Fetal Brain: Timing and Causation. Arnold, London, pp 110–127

Squier W, Chamberlain P, Zaiwalla Z, Anslow P, Oxbury J, Gould S, McShane MA (2000) Five cases of brain injury following amniocentesis in midterm pregnancy. Dev Med Child Neurol 42:554–560

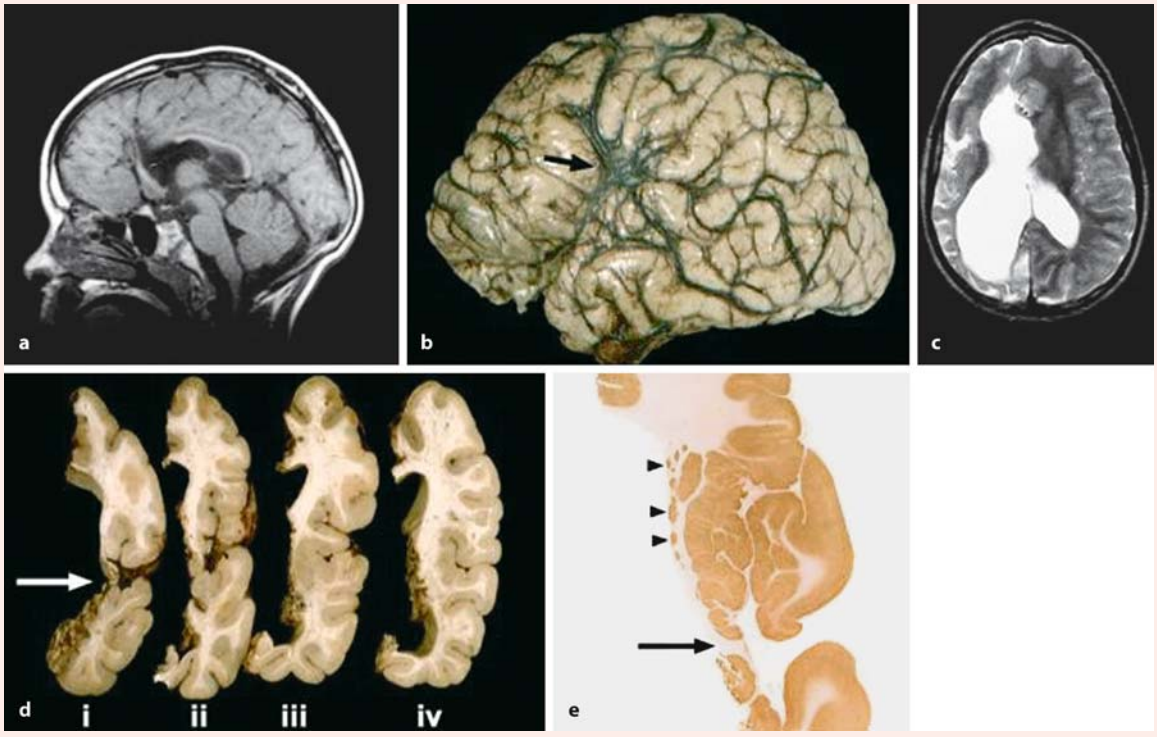

Fig. 3.16 Traumatic amniocentesis: **a** sagittal MRI showing a defect in the anterior part of the corpus callosum; **b** lateral surface of the hemisphere; the *arrow* indicates a cortical scar; **c** horizontal MRI showing atrophy of the left cerebral hemisphere; **d** coronal slices through the affected hemisphere showing a cortical defect (*arrow*) and a thin corpus callosum; **e** section of part of the hemisphere, stained to show neurons, illustrating the cortical defect (*arrow*) and several nodular heterotopia (*small arrows*) due to lack of normal migration (from Squier 2002, with permission; courtesy Waney Squier, Oxford)

3.3.3 Genetic Diagnosis

Karyotyping

Chromosome analysis can be performed on any tissue with living nucleated cells which undergo division. Circulating lymphocytes from peripheral blood are most commonly used, but also skin, bone marrow, chorionic villi or amniocytes are often used. After culturing and a technical preparation, different staining methods can be used in order to identify the individual chromosomes by their banding pattern such as G (Giemsa) banding, which gives each chromosome a characteristic and reproducable pattern of light and dark bands. **G banding** is the most widely used banding technique with up to 400–500 bands. High-resolution banding provides greater sensitivity with up to 800 bands, but is much more time consuming. Usually 10–15 cells are microscopically analysed. If mosaicism is suspected 30 or more cells are examined. The karyotype is the end result of the analysis whereby each chromosome is pairwise represented in descending order of size (Fig. 3.1 a). **Fluorescent in situ hybridization** (FISH) combines chromosome analysis with a molecular technique that allows a piece of single-stranded DNA (probe) with known genomic localization to hybridize with its complementary target sequence. The probe is fixed to a fluorescent label which gives a visible signal after hybridization (Fig. 3.2). FISH technology is particularly useful for the detection of submicroscopic deletions such as 22q11 deletion in VCFS and DiGeorge syndrome, 7q11 deletion in Williams syndrome, 15q11 maternal deletion in Angelmann syndrome and 15q11 paternal deletion in Prader–Willi syndrome. In these examples the clinical suspicion is highly relevant: only when VCFS is suspected, 22q11 FISH will be performed. Newer techniques have been developed–and are being improved–to detect even smaller deletions and/or duplications in a systematic way (multiplex amplifiable probe hybridization, multiplex ligation-dependent probe amplification, microarray-based comparative genomic hybridization; Sismani et al. 2001; Schouten et al. 2002; Vissers et al. 2003; Strachan and Read 2004).

Identifying the Genes for Human Developmental Anomalies

The most commonly used way to initiate the identification of genes involved in monogenic disorders is linkage analysis; its aim is to map the locus where the putative gene, mutated in the involved monogenic disease, is located. **Linkage analysis** is based on the fact that when two loci are sufficiently close together on a chromosome, alleles at these loci are very likely to stay together in meiosis, or in other words are very unlikely to be separated by crossover or recombination in meiosis. It involves study of the segregation of a monogenic disease in large families with a set of polymorphic markers from each chromosome. In families with an X-linked disorder only X-chromosomal polymorphic markers will be used. Eventually a marker can be identified which cosegregates with the disease or in other words the marker locus and the disease locus are linked. The likelihood of linkage can be calculated and is expressed in a Lod score. Since usually many markers are used, it is possible to construct a linked haplotype: a set of alleles of linked markers with on each side a recombined non-linked marker, so defining the linkage interval or the linked chromosomal region. The size of such a region is expressed in centimorgan: the smaller the region, the better the chances to identify a gene.

Positional gene cloning uses two strategies. The first is based on linkage studies: if the linkage interval is very small, techniques are available to identify one or more genes in the interval and to test these for the presence of pathogenic mutations. In this way, for instance, the cystic fibrosis gene was found. The second is based on the identification of patients with a monogenic disease and a chromosomal rearrangement: the hypothesis is that the chromosomal rearrangement disrupts the gene involved in that monogenic disease. Again techniques are available to identify that gene. When subsequently in other patients with that monogenic disease mutations in the so-identified gene are found the hypothesis becomes true. The X-chromosomal gene for the Duchenne muscular dystrophy was detected in this way. **Candidate gene mapping** is another method. From animal models and the human genome project information about genes and the gene content of a given linkage interval can be retrieved. Very often information about the function and/or the expression pattern of the genes is available and this allows for the selection of one or more candidate genes for a given disorder. Finally, identifying pathogenic mutations in patients confirms that this candidate gene is in fact the disease gene. In this way p63 was found to be the gene involved in the ectrodactyly–ectodermal dysplasia-clefting (EEC) syndrome.

DNA Diagnosis

DNA diagnosis in monogenic diseases can be done in two ways: the indirect and the direct way. In indirect DNA diagnosis linkage analysis is performed. This gives reliable results, though never 100% reliable, provided the disease locus is known, the clinical diagnosis is correct, the disease is homogeneous, a sufficient number of family members are available and recombination does not occur. Direct DNA diagnosis is presently the more commonly used method and is based on mutation analysis in the known disease gene. This gives usually 100% reliable results, though not finding the mutation does not necessarily

exclude the disease owing to genetic heterogeneity and/or technical shortcomings. For hundreds of monogenic disorders DNA diagnosis is possible both pre- and postnatally. Also carrier testing is reliably possible for autosomal and X-linked recessive disorders. Presymptomatic DNA diagnosis involves the genetic testing of healthy individuals in families with an usually late onset hereditary disease and in which the pathogenic mutation is known. Examples are Huntington disease and hereditary breast/ovary cancer. Obviously, adequate pre- and posttest genetic counselling and where relevant psychosocial support are required.

Preimplantation Genetic Diagnosis

Preimplantation genetic diagnosis (PGD) is the combination of in vitro fertilization (IVF) and genetic testing (Braude et al. 2002). After IVF early embryos are allowed to develop into the eight-cell stage. Then one to two cells are biopsied and examined while the rest are set aside in the deep freezer. After the results are known only the healthy embryos are implanted in the uterus. This is still a fairly experimental method with as its most serious drawback the relatively low chance of an ongoing pregnancy. Examples in which it is performed are cystic fibrosis, spinal muscular atrophy, haemophilia and fragile X syndrome.

3.4 Inborn Errors of Metabolism Affecting the CNS

Inborn errors of metabolism present a large group of genetic metabolic disorders, the common feature of which is a genetically determined interruption in one or several related metabolic pathways (Fitzpatrick 2001; Scriver et al. 2001; Epstein et al. 2004). In general, metabolic diseases are recessive disorders without clinical symptoms in heterozygous individuals. However, involved genes may also be located on the X chromosome and on the mtDNA, leading to different modes of inheritance. Many metabolic diseases are caused by mutations in genes encoding proteins with a single enzymatic function. Most conditions are individually rare, but collectively metabolic diseases are rather common. The complexity and vulnerability of the CNS is illustrated by the presence of neurological signs and symptoms in the majority of inborn errors of metabolism. CNS malformations may occur in almost all types of inborn errors of metabolism, including disorders of oxidative phosphorylation, aminoacidopathies, organic acidurias, fatty acid oxidation disorders, lysosomal storage disorders, peroxisomal disorders, congenital disorders of glycosylation and disorders of cholesterol biosynthesis. From a clinical point of view, the following three categories can be distinguished:

1) ***Inborn errors of metabolism that primarily are located in other organs, whereby the CNS is secondarily involved.*** In such cases, the CNS is generally threatened by energy deficiency or intoxication. Examples are disorders of carbohydrate metabolism and fatty acid oxidation that primarily involve the liver but lead to acute energy crises of the CNS owing to hypoglycemia or CNS intoxication (e.g. in galactosemia and PKU), respectively. In propionic and methylmalonic acidurias and urea cycle defects, the CNS is threatened by energy defects as well as intoxication. Many disorders in this category exhibit acute neurological manifestations like coma and seizures.

2) ***Inborn errors of metabolism that mainly affect the CNS.*** In this category, the involved metabolic pathway is located in the CNS. For such disorders, the term ***neurometabolic diseases*** is increasingly used (Moser 1998). The pathophysiological mechanisms of these disorders include energy failure, substrate deficiency, intoxication, or combinations of these. Pattern recognition via MRI is very helpful in the classification of neurometabolic diseases (Barkovich 2000). An important decision to be made is whether the disorder is primarily in the grey matter, primarily in the white matter or a combination of both. Examples of neurometabolic disorders are:
   a) Some lysosomal storage disorders (Tay–Sachs disease and the neuronal ceroid lipofuscinoses, classic examples of 'grey matter' disorders; and metachromic leukodystrophy, a typical 'white matter' disorder)
   b) Cerebral organic acid disorders such as glutaric aciduria types 1 and 2, and L-2-hydroxyglutaric aciduria and D-2-hydroxyglutaric aciduria
   c) Neurotransmitter synthesis disorders (e.g. tyrosine hydroxylase deficiency)
   d) Neurotransmitter degradation defects (e.g. succinic semialdehyde dehydrogenase deficiency)
   e) CNS disorders of energy production due to defective substrate availability (e.g. glucose transporter type 1 deficiency) or defective substrate intoxication (e.g. mitochondrial encephalopathies). Most neurometabolic disorders show progressive neurological features such as mental retardation, motor disturbances and epilepsy.

Table 3.6 Some inborn errors of metabolism that mainly affect the CNS

Group of disorders	Disorder	Defective gene/ protein	CNS malformations	References
Amino acids	Non-ketotic hyper-glycinemia		Dysgenetic corpus callosum	Dobyns (1989); Hamosh and Johnston (2001)
Organic acids	Pyruvate dehydrogenase deficiency		Dysgenetic corpus callosum	Brown et al. (1989); Robinson (2001)
	Fumarase deficiency		Agenesis corpus callosum; polymicrogyria; hydrocephalus	Remes et al. (1992); Kerrigan et al. (2000)
	Glutaric aciduria type 1		See Chap. 9	
	Glutaric aciduria type 2		Pachygyria; heterotopia; hypoplastic corpus callosum; dysplastic cerebellum	Goodman and Frerman (2001)
Purines, pyrimidines	Lesch–Nyhan syndrome	Purine salvage enzyme hypo-xanthine–guanine phosphoribosyl-transferase	Neurobehavioural syndrome with motor dysfunction and self-injurious behaviour	Jinnah and Friedmann (2001)

3) ***Inborn errors of metabolism that present as multisystem disorders with mild, moderate, or severe CNS involvement***. Many inborn errors of metabolism fall into this category. Striking examples of multisystem disorders are:
   a) Congenital disorders of N- and O-linked glycosylation
   b) Mitochondrial encephalomyopathies
   c) Lysosomal storage disorders
   d) Peroxisomal disorders
   e) Cholesterol biosynthesis disorders

The clinical approach to metabolic diseases of the CNS involves careful history-taking, MRI pattern recognition, ophthalmological investigation (some disorders are accompanied by highly typical forms of cataract or retinopathy) and appropriate laboratory analyses at the metabolite, enzyme or DNA level.

3.4.1 Inborn Errors of Metabolism that Mainly Affect the CNS

Some of the inborn errors of metabolism that cause isolated CNS malformations are summarized in Table 3.6. Pachygyria or microgyria appear to be the most common malformations, followed by agenesis of the corpus callosum, hydrocephalus and (ponto)cerebellar hypoplasia. Pyruvate dehydrogenase deficiency is the best studied neurometabolic disorder (Brown et al. 1989; Brown and Squier 1996; Robinson 2001), with partial or total agenesis of the corpus callosum as the dominant feature. Other examples of disorders in the metabolism of organic acids are fumarase deficiency (Remes et al. 1992; Kerrigan et al. 2000) and glutaric aciduria type 1 (Chap. 9) and type 2 (Goodman and Frerman 2001).

The best known disorder of amino acid metabolism is non-ketotic hyperglycinemia (Hamosh and Johnston 2001), clinically characterized by a severe neonatal epileptic encephalopathy. In many patients, the corpus callosum is absent (Dobyns 1989). In Lesch–Nyhan syndrome, hyperuricemia and a characteristic neurobehavioural syndrome with motor dysfunction and self-injurious behaviour is found (Jinnah and Friedmann 2001). This syndrome and its variants are due to inherited deficiency of the purine salvage enzyme hypo-xanthine–guanine phosphoribosyltransferase (HPRT).

3.4.2 Multisystem Disorders with CNS Involvement

Under this heading the following inborn errors of metabolism will be briefly discussed: (1) congenital disorders of glycosylation (the CDG syndromes); (2) inherited disorders of cholesterol biosynthesis; and (3) disorders of peroxisomal structure and function, Zellweger's cerebrohepatorenal syndrome in particular (Table 3.7).

Congenital Disorders of Glycosylation

Congenital disorders of glycosylation (the ***CDG syndromes***) are a rapidly growing family of genetic diseases caused by defects in the synthesis of the glycan moiety of glycoconjugates or in the attachment of glycans to macromolecules (Jaeken and Carchon 2001; Jaeken and Matthijs 2001; Jaeken et al. 2001; Marquardt and Denecke 2003). In addition to many other organs, the brain is affected in 10 of the 11 known congenital disorders of N-linked glycosylation, mostly to a severe degree. Because a large number of enzymes, transporters and other proteins

Table 3.7 Some multisystem disorders with CNS involvement

Group of disorders	Disorder	Defective gene/ protein	CNS malformations	References
Cholesterol biosynthesis	Smith–Lemli–Opitz syndrome	*DHCR7*; 7-dehydrocholesterol reductase	Holoprosencephaly; periventricular nodes; dysplasia cerebellum and corpus callosum	Cunniff et al. (1997); Haas et al. (2001)
	Mevalonic aciduria	*MVK*; mevalonate kinase	Cerebellar atrophy	Hoffmann et al. (1993)
	CHILD syndrome	Sterol-4-demethylase	Unilateral hypoplasia brain stem and spinal cord	Happle et al. (1980)
	Desmosterolosis	Sterol-Δ24-reductase	Variable phenotype, ranging from macrocephaly to microcephaly	FitzPatrick et al. (1998); Haas et al. (2001); Waterham et al. (2001)
Congenital disorders of N-glycosylation	CDG-1a	*PMM2*; phosphomannomutase	Olivopontocerebellar atrophy	Jaeken and Carchon (2001); Chap. 8
Congenital disorders of O-glycosylation defects	Walker–Warburg syndrome	*POMT*; *O*-mannosyltransferase	Cobblestone lissencephaly; encephalocele; pontocerebellar hypoplasia	Barkovich et al. (2001); Beltrán-Valero de B et al. (2002); Chap. 10
	Fukuyama type of congenital muscular dystrophy	*Fukutin*/Fukutin	Cobblestone lissencephaly; mental retardation; congenital muscular dystrophy	Kobayashi et al. (1998); Toda et al. (2003)
	Muscle–eye–brain disease	POMGnT1 (a glysosyltransferase)	Pachygyria; pontocerebellar hypoplasia	Barkovich et al. (2001); Yoshida et al. (2001); Chap. 10
Peroxisomes	Zellweger syndrome		Polymicrogyria; pachygyria; hypoplasia corpus callosum, cerebellar dysplasia	Zellweger (1987); Gould et al. (2001); Wanders et al. (2001)
	X-linked adrenoleukodystrophy	ALD protein gene		Moser et al. (2001)

are involved in glycosylation (both N-linked and O-linked), it is expected that the great majority of congenital disorders of glycosylation are yet to be identified (Jaeken and Carchon 2001). An example of an N-linked glycosylation disorder (CDG-1a), leading to pontocerebellar hypoplasia, is shown in Clinical Case 3.5. O-linked glycosylation defects form the underlying mechanism of certain lissencephalies such as Walker–Warburg syndrome, Fukuyama congenital muscular dystrophy and muscle–eye–brain disease (Barkovich et al. 2001; Chap. 10).

Disorders of Cholesterol Biosynthesis

Defects of cholesterol biosynthesis (Fig. 3.18) comprise a heterogeneous group of disorders, most of which have only recently been described. More are likely to follow in the near future (Haas et al. 2001; Kelley and Herman 2001). In general, there are two mechanisms by which aberrant cholesterol biosynthesis may cause developmental disorders: (1) a relative deficiency of cholesterol; and (2) a relative excess of the sterol precursor. Abnormal sterols are known to alter membrane fluidity, which may alter both the movement of embryonic cells and cell–cell interaction. Altering the sterol content of membranes may also lead to the aberrant functioning or mistargeting of some proteins. Perturbations in cholesterol homeostasis may result from a defect in the normal Sonic hedgehog signalling network and cholesterol biosynthesis (Cohen and Shiota 2002; Chap. 9). ***Mevalonic aciduria***, caused by deficiency of mevalonate kinase, an enzyme located proximally in the cholesterol pathway, was the first reported disorder of cholesterol (Hoffmann et al. 1986). The patient showed profound psychomotor retardation, ataxia, a dysmorphic appearance, cataract, hepatosplenomegaly and recurrent febrile attacks. Later, several patients with milder forms were described (Hoffmann et al. 1993; Gibson et al. 1997). The other recognized defects of cholesterol biosynthesis, such as CHILD syndrome, desmosterolosis and Smith–Lemli–Opitz syndrome, are due to enzyme defects located distally in the cholesterol pathway (Fig. 3.18). Patients with these disorders all show complex malformation syndromes

Clinical Case 3.5
Congenital Disorders of Glycosylation

Congenital disorders of glycosylation (the CDG syndromes) are genetic diseases caused by defects in the synthesis of the glycoconjugates or in the attachment of glycans to macromolecules (Jaeken and Matthijs 2001; Jaeken et al. 2001). Apart from the brain, many other organs are usually severely involved in disorders of N-linked glycosylation (Strømme et al. 1991). The best known N-linked CDG syndrome, CDG-1a, leads to pontocerebellar hypoplasia (see Case Report). The defective gene and protein are *PMM2* and the enzyme phosphomannomutase, respectively.

Case Report. A 15-year-old boy, with psychomotor retardation of unknown aetiology and severe scoliosis, died after a severe bronchopneumonia. At autopsy, an extensive necrotic bronchopneumonia and signs of aspiration were found. The endocard showed fibrosis and the liver was steatotic and mildly fibrotic (Fig. 3.17 f). Cystically enlarged tubules were present in the kidneys (Fig. 3.17 g) and a calyceal vein was occluded by thrombotic material. Brain examination showed no obvious malformations of the cerebrum but extensive olivopontocerebellar atrophy (Fig. 3.17 a–c). The cerebellar atrophy was present in the vermis as well as in the hemispheres. A reduced number of small folia were present. Microscopic examination of the brain stem revealed severe atrophy of the inferior olives (Fig. 3.17 d). No accessory olives and arcuate nuclei were present. In the cerebellar cortex, small molecular and granular layers could be distinguished, but no Purkinje cells. Distinct dentate nuclei were found. The pontine nuclei were small. In the cerebrum, some nodular heterotopia were found along the lateral ventricles. These characteristic findings at autopsy permitted the diagnosis of CDG type 1a, a diagnosis that was confirmed by deficient enzymatic phosphomannomutase activity in cultured fibroblasts (0.06 mU/mg protein; normal range 1.27–4.53).

This case was kindly provided by Gerard van Noort (Laboratory for Pathology East-Netherlands, Enschede, The Netherlands).

References

Jaeken J, Matthijs G (2001) Congenital disorders of glycosylation. Annu Rev Genomics Hum Genet 2:129–152

Jaeken J, Matthijs G, Carchon H, Van Schaftingen E (2001) Defects of N-glycan synthesis. In: Scriver CR, Beaudet AL, Sly WS, Valle D (eds) The Metabolic & Molecular Bases of Inherited Disease, 8th ed. McGraw-Hill, New York, pp 1601–1622

Strømme P, Maehlen J, Strøm EH, Torvik A (1991) Postmortem findings in two patients with the carbohydrate-deficient glycoprotein syndrome. Acta Paediatr Scand Suppl 375:55–62

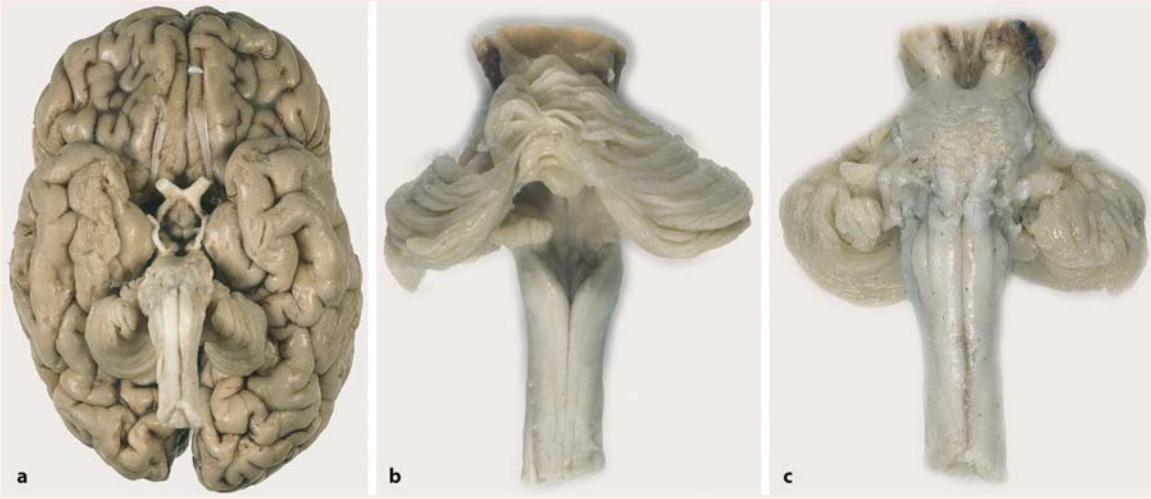

Fig. 3.17 CDG-1a case in a 15-year-old boy: **a** basal view of the brain; **b**, **c** dorsal and ventral views of the brain stem and cerebellum

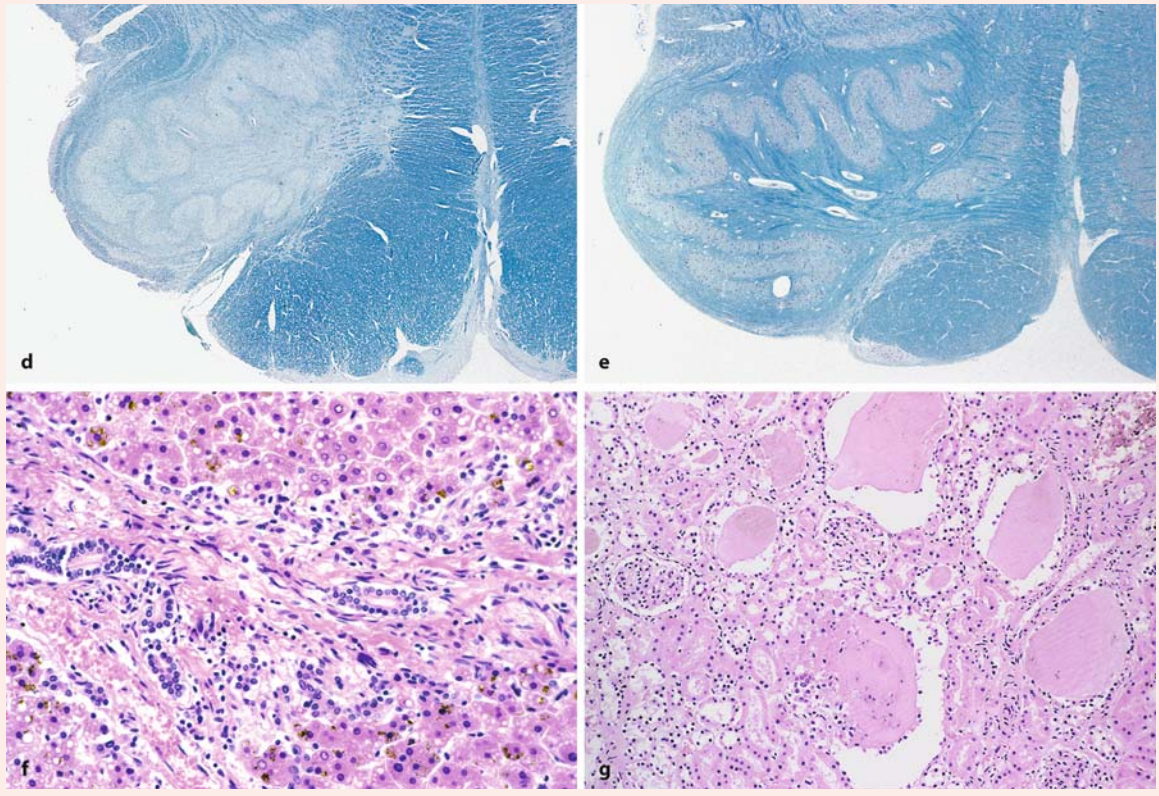

Fig. 3.17 *(Continued)* **d**, **e** Luxol Fast Blue stained sections of the inferior olive in this case and a control, respectively; **f** steatotic and mildly fibrotic liver; **g** cystically enlarged tubuli in the kidney (courtesy Gerard van Noort, Enschede)

involving different organ systems. ***CHILD syndrome***, an acronym for congenital hemidysplasia, ichthyosiform erythroderma and limb defects, is characterized by unilateral ichthyotic skin lesions with a sharp demarcation at the midline of the trunk (Happle et al. 1980). ***Desmosterolosis*** shows a variable phenotype ranging from macrocephaly to microcephaly with facial and limb malformations (FitzPatrick et al. 1998; Haas et al. 2001; Waterham et al. 2001). ***Smith–Lemli–Opitz syndrome*** (***SLOS***) is an autosomal recessively inherited, multiple malformation syndrome, characterized by retardation, syndactyly and hypogenitalism (Smith et al. 1964; Opitz et al. 1969; Cunniff et al. 1997; Kelley and Hennekam 2000). The face of SLOS patients is distinct and characterized by microcephaly, bitemporal narrowing, hypertelorism, ptosis, a short nasal root, anteverted nares and micrognathia. Characteristic skeletal abnormalities include postaxial polydactyly and syndactyly of the second and third toes, and limb shortness. Hypogenitalism ranges from cryptorchidism to apparent complete sex reversal. Cardiac malformations are common (Liu et al. 1997). Common CNS malformations include hypoplasia or aplasia of the corpus callosum, hypoplasia of the frontal lobes, and cerebellar hypoplasia, especially of the vermis (Cherstvoy et al. 1975; Fierro et al. 1977; Marion et al. 1987). Congenital sensorineural hearing deficits may affect about 10% of patients (Ryan et al. 1998), and some form of holoprosencephaly, from a small midline notch of the upper lip to semilobar holoprosencephaly, occurs in about 5% of patients (Kelley et al. 1996). Irons et al. (1993) noted that patients with SLOS had a more than a 100-fold increase in the plasma level of 7-dehydrocholesterol, the immediate precursor of cholesterol. A few years later, Moebius et al. (1998) cloned the human DHCR7 gene, localized it to chromosome 11q12-13, and subsequently mutations of DHCR7 causing SLOS were found (Fitzky et al. 1998; Moebius et al. 1998; Wassif et al. 1998; Waterham et al. 1998).

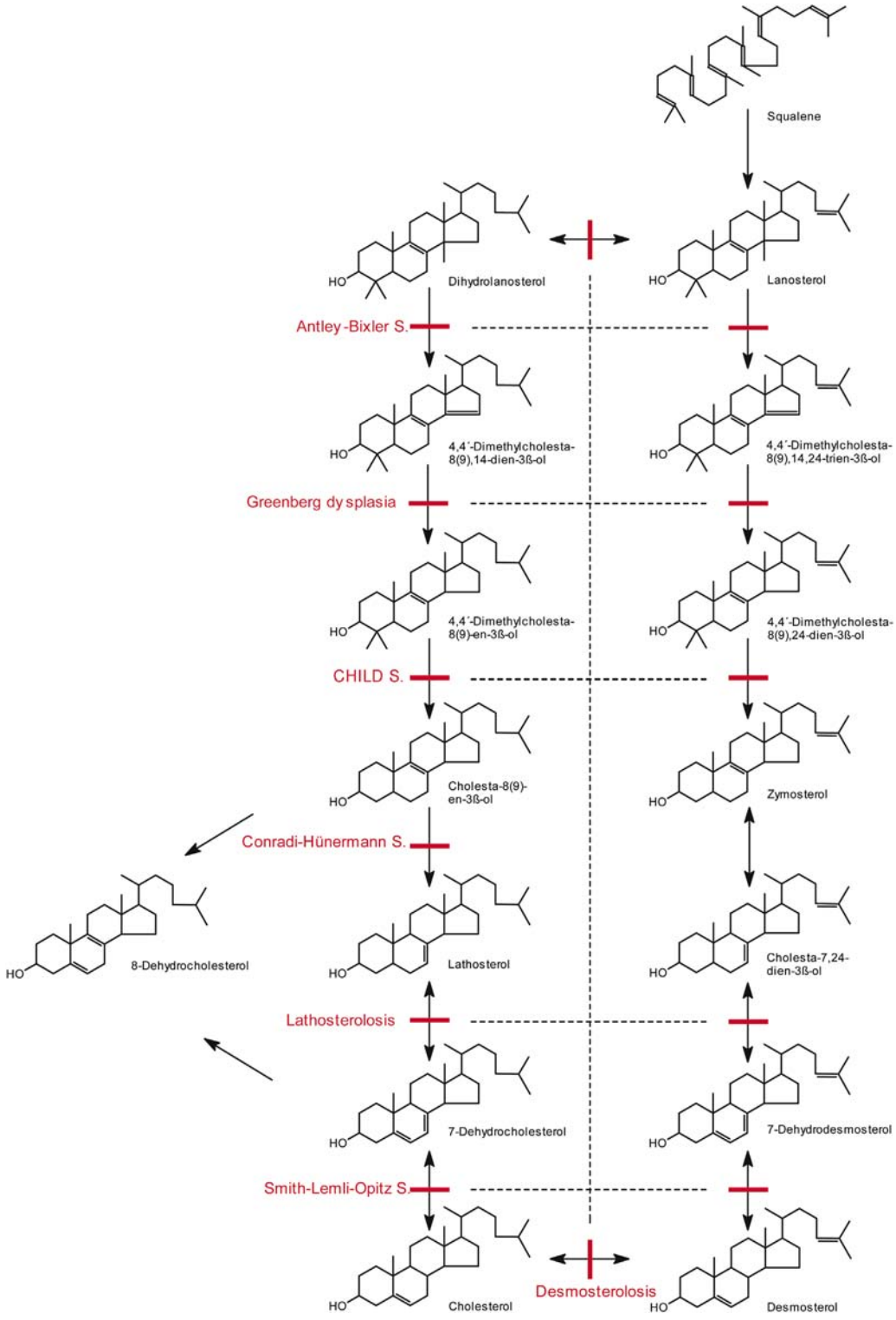

Fig. 3.18 Pathway of cholesterol biosynthesis. This pathway is used with informed agreement of Drs. D. Haas, J.G. Okun (both of the University Children's Hospital Heidelberg, Germany), and R.I. Kelley (Johns Hopkins University, Kennedy Krieger Institute, Baltimore, USA)

Disorders of Peroxisomal Structure and Function

Peroxisomes are roughly spherical organelles bound by a single lipid bilayer to the intracellular membrane. Their enzymatic abilities include roles as oxidases, in ether lipid synthesis, and in cholesterol and dolichol biosynthesis. The disorders of peroxisome biosynthesis have been divided into 11 complementation groups (Moser et al. 1995). Groups 1–10 are associated with the phenotypes of ***Zellweger syndrome*** (Gould et al. 2001; Wanders et al. 2001; Clinical Case 3.6), neonatal adrenoleukodystrophy or infantile Refsum disease, which are now thought to represent variants with different severity of the same disorder (Moser et al. 1995). Group 11 is associated with the rare rhizomelic chondrodysplasia punctata phenotype.

3.5 Myelination Disorders

Myelination is the final phase in the development of the cerebral white matter. In the CNS, myelin is produced by oligodendrocytes. Flat processes, extending outwards from the oligodendrocyte cell body, are being wrapped around axons in a spiral fashion and so form myelin. As a rule myelination in the CNS occurs along a caudal to rostral gradient (Chap. 1). Most of the myelination of the forebrain takes place after birth. MRI assessment of myelination patterns in children can be performed to score functional maturity of the brain (van der Knaap and Valk 1990, 1995; Sie et al. 1997). Primary absence of central myelination has not been described so far. Even patients with a null mutation of the major CNS myelin protein, the proteolipid protein 1, as found in Pelizaeus–Merzbacher disease, do show light microscopical presence of myelin even at adult age (Koeppen and Robitaille 2002). ***Pelizaeus–Merzbacher disease*** is the prototype of a central hypomyelinating disorder (Fig. 3.20), and is due to mutations of the ***proteolipid protein*** (***PLP***) gene on chromosome Xq22 (Inoue et al. 1996; Koeppen and Robitaille 2002; Chap. 2).

Several inherited metabolic diseases have their principal target in the cerebral white matter and are generally called ***leukodystrophies***. They include diseases such as globoid cell leukodystrophy (Krabbe disease), metachromic leukodystrophy and adrenoleukodystrophy (Ruggieri 1997; Aicardi 1998). Early in the disease course, their clinical picture is generally dominated by bilateral and slowly progressive motor manifestations such as spasticity and ataxia. Cognitive and behavioural deterioration and epileptic phenomena usually appear at a later time and remain overshadowed by motor disturbances for a long time. ***Congenital white matter hypoplasia*** has also been reported without evidence of demyelination, dysmyelination or degeneration of cortical neurons (Chattha and Richardson 1977; Lyon et al. 1990), and may possibly be due to a primary defect of axonal development. Recently, the so-called ***vanishing white matter disease***, originally descibed as occurring only in children older than 1 year of age and in adults (van der Knaap et al. 1997), has been found to start prenatally (van der Knaap et al. 2003). Autopsy of one of the nine patients originally described confirmed MRI findings (van der Knaap et al. 1997) of extensive cystic degeneration of the cerebral white matter with reactive changes and a preserved cortex. Moreover, typical involvement of the pontine tegmental white matter was observed. This autosomal recessive disorder is due to mutations in one of the five subunits of the translation initiation factor eIF2B, located on chromosome 3q27 (Leegwater et al. 1999, 2001; van der Knaap et al. 2002; Clinical Case 3.7). The neurological signs of vanishing white matter disease include cerebellar ataxia, spasticity, inconstant optic atrophy and a usually relatively mild mental decline. The disease is chronically progressive, with in most patients episodes of rapid deterioration following febrile infections and minor head trauma. Death occurs after a variable period of a few months to a few decades. MRI findings are diagnostic, showing a diffuse abnormality of the cerebral white matter (van der Knaap 1997, 2002).

3.6 Vascular Disorders

The developing brain is vulnerable to various vascular disturbances during pregnancy. The resulting brain lesions are not only dependent on the severity of the particular disturbance but correlate also with the developmental state of the brain. The cause of ischemia or hypoxia may be maternal, placental, fetal or a combination of these factors. Early in gestation, general hypoxia may lead to very severe brain malformations such as porencephaly and hydranencephaly. ***Porencephaly*** was originally defined as a smooth-walled cyst with communication between the ventricle and the subarachnoid space due to circumscribed hemispheric necrosis that occurs in utero or before the adult features of the hemisphere are manifest (Friede 1989; Norman et al. 1995; Clinical Case 3.8). This term is often used more widely, particularly by neuroradiologists, who include unilateral enlargement of the lateral ventricles. ***Hydranencephaly*** means the destruction of the cerebral hemispheres, usually the bilateral territories of supply of the internal carotid arteries, combined with hydrocephalus due to aqueduct stenosis (Fig. 3.23). In both types of brain injury a varying part of the basal ganglia and the thalamus are also involved (Norman et al. 1995). When the fetus survives such serious

Clinical Case 3.6
Zellweger Syndrome

Zellweger syndrome is an early lethal multisystem disorder with deficient peroxisomes, and is characterized by cerebrohepatorenal malformations due to defective β-oxidation of very long chain fatty acids (Moser et al. 1984). Definitive diagnosis is made by demonstration of increased levels of very long chain fatty acids in plasma or cultivated fibroblasts (Gould et al. 2001; Wanders et al. 2001). Clinical features include dysmorphic facies, deafness, congenital cataract, hepatomegaly, gastrointestinal bleeding, hypotonia and seizures (see Case Report).

Case Report. The girl was the first child of nonconsanguineous parents, born at 40.5 weeks of gestation. Her weight was 2,500 g (P5), and her head circumference was 33 cm (P3). There were dysmorphic signs: a broad nasal bridge, low-set ears, a high forehead, a small chin, Simian crease, joint contractures of the lower limbs and bilateral congenital cataract. The baby was hypotonic. There was hepatomegaly. X-ray examination of the knees showed stippled patellar calcifications. Abdominal ultrasound examination showed renal cortical cysts. There was severe epilepsy and poor psychomotor development. The clinical diagnosis of Zellweger syndrome was confirmed by the demonstration of deficiency of per-

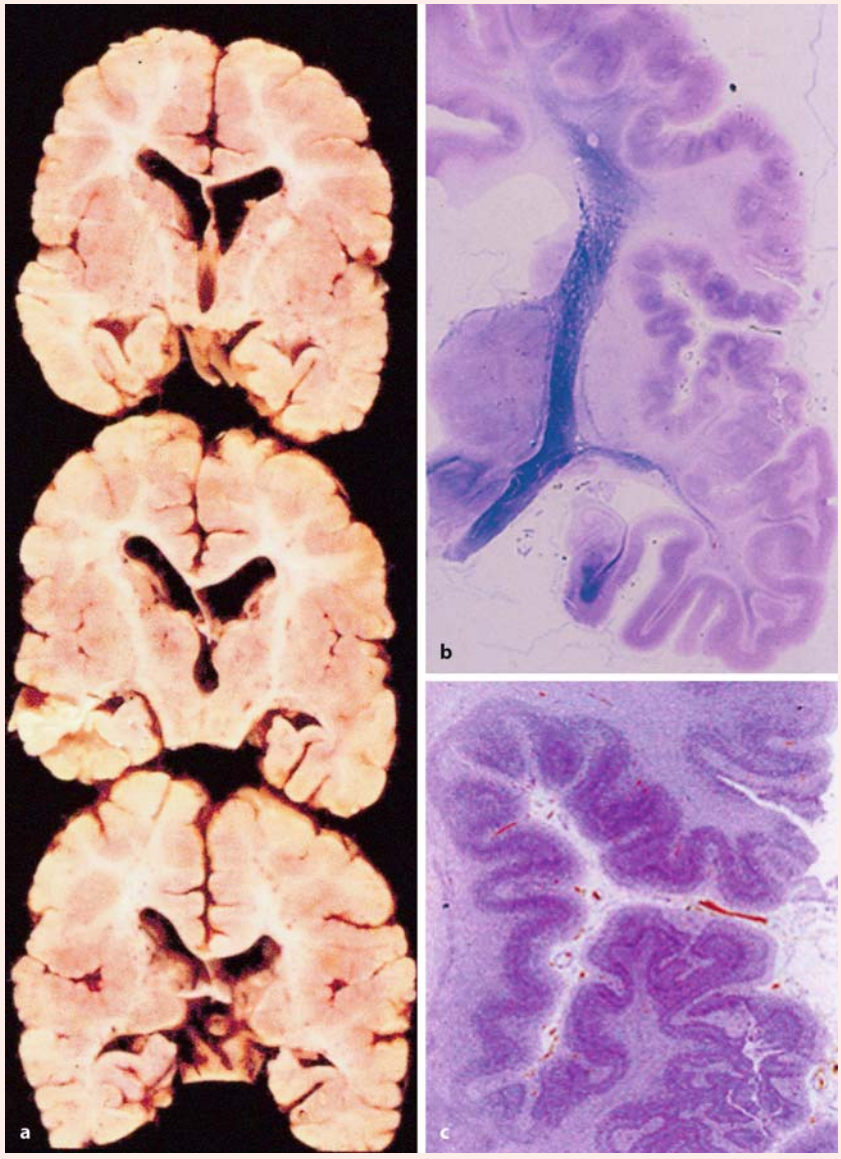

Fig. 3.19 Zellweger syndrome, showing bilateral polymicrogyria in frontal sections of the brain: **a** overview of three slices; note hypoplastic corpus callosum and periventricular cavity on the left side; **b, c** Luxol Fast Blue stained sections of the insular region (courtesy Martin Lammens, Nijmegen)

oxisomal enzymes such as palmitoylcoenzyme A oxidase and glycolate oxidase, by the presence of phytanic acid (1.21 ìg/ml), by the increase of very long chain fatty acids and by electron microscopic examination of the liver which revealed absence of peroxisomes. The child died at 9 months of age. The neuropathological findings are shown in Fig. 3.19. Brain weight was 940 g (range 820±49 g). The cerebrum showed bilateral polymicrogyria, especially pronounced in the insular region of the temporal lobe, whereas the middle and lower temporal gyri were normal. The corpus callosum was hypoplastic. A periventricular cavity was found on the left side. On microscopy, there was hypomyelination and widespread gliosis of the white matter. The polymicrogyric cortex showed some vertical lamination, with vertically oriented strands of neurons present in the underlying white matter. A few glioneuronal ectopia were present in the insular leptomeninges. The plump inferior olives showed an abnormal gyration pattern with very sparse undulations. Material for further molecular biological examination was not available.

This case was kindly provided by Mark D'hooghe (General Hospital St. Jan, Bruges, Belgium).

References

Gould SJ, Raymond GV, Valle D (2001) The peroxisome biogenesis disorders. In: Scriver CR, Beaudet AL, Sly WS, Valle D (eds) The Metabolic & Molecular Bases of Inherited Disease, 8th ed. McGraw-Hill, New York, pp 3181–3218

Moser AE, Singh I, Brown FR, Solish GI, Kelley RI, Benke PJ, Moser HW (1984) The cerebro-hepato-renal (Zellweger) syndrome. Increased level and impaired degradation of very-long-chain fatty acids and their use in prenatal diagnosis. N Engl J Med 310:1141–1146

Wanders RJA, Barth PG, Heymans HSA (2001) Single peroxisomal enzyme deficiencies. In: Scriver CR, Beaudet AL, Sly WS, Valle D (eds) The Metabolic & Molecular Bases of Inherited Disease, 8th ed. McGraw-Hill, New York, pp 3219–3256

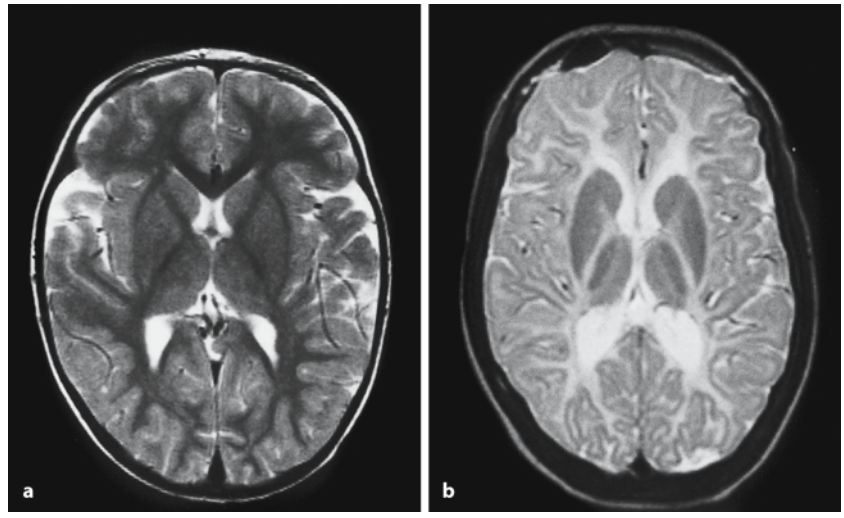

Fig. 3.20 MRI (T2-weighted) of **a** a normal 2-year-old child and **b** a child with Pelizaeus–Merzbacher disease (courtesy Henk O.M. Thijssen, Nijmegen)

lesions, additionally polymicrogyria and other malformations may be seen, the extent of the lesion again is dependent on the developmental state of the fetus.

An important cause of intrauterine ischemic cerebral damage may be seen in monochorionic twins in which, owing to placental shunting (Arts and Lohman 1971; Eberle et al. 1993; Benirschke and Kaufman 1995), ***twin-to-twin transfusion*** leads to shortage of blood in one fetus and surplus of blood in the other (Clinical Case 3.9). There are several reports of polymicrogyria in monozygotic twins (Norman 1980; Barth and van der Harten 1985; Larroche et al. 1994). In their cases, Barth and van der Harten (1985) dated the appearance of polymicrogyria in monozygotic twins to the 13th to 16th weeks of gestation. Bordarier and Robain (1995) described a case of dizygotic twins in which both parts showed cerebral damage.

Periventricular haemorrhage, most often synonymous to germinal matrix haemorrhage, represents an important midterm pathology (Fig. 3.25 a). Although classically seen in very low birthweight infants with less than 24 weeks of gestation or in sick premature neonates owing to disturbed autoregulation of cerebral blood flow, it may also occur during intrauterine life (de Vries et al. 1998a) and may be associated with

Clinical Case 3.7
Vanishing White Matter Disease

In two MRI-defined white matter disorders, megalocephalic leukoencephalopathy with subcortical cysts and vanishing white matter, the gene defects have been identified (Leegwater et al. 2001; van der Knaap et al. 2002, 2003). ***Vanishing white matter disease*** (***VWMD***) usually has its onset in late infancy or early childhood, but onsets in early infancy, have also been described. The youngest case reported so far is presented as the Case Report. Mutations in each of the five subunits of the translation initiation factor eIF2B can cause VWMD.

Case Report. The second child, a girl, of a consanguineous Turkish family was born at 38 gestational weeks after a prenatal history of severe and progressive intrauterine growth retardation since the 26th gestational week. At birth, there was microcephaly and the infant had a drop hand. The neurological status of the baby deteriorated progressively with loss of most neurological functions. She died at 3 months of age. MRI showed severe hypomyelination. Autopsy confirmed the diagnosis vanishing white matter disease. The first child in this family, a boy, had a comparable clinical history and died at 4 months of age. In both infants, a homozygous mutation in the delta subunit of eIF2B4 was found. At autopsy, the microcephalic brain showed a normal gyral pattern and a hypoplastic cerebellum. The white matter of the cerebral hemispheres had a grey colour, it was diffusely very weak and focally cystic (Fig. 3.21). The central white matter of the cerebellum was less affected. On microscopic examination, there was severe diffuse degeneration of the myelin in the centrum semiovale and to a lesser degree in the cerebral hemispheres, the pyramidal tracts and the cerebellar hemispheres. Mild degeneration was found in the basal ganglia and the brain stem. In the severely affected parts of the brain, complete absence of myelin with relatively little myelin debris was observed.

This case was kindly provided by Caroline Van den Broecke and Rudy Van Coster (University Hospital, Gent, Belgium).

References

Leegwater PAJ, Vermeulen G, Könst AAM, Naidu S, Mulders J, Visser A, Kersbergen P, Mobach D, Fonds D, van Berkel CGM, et al. (2001) Subunits of the translation initiation factor eIF2B are mutated in leukoencephalopathy with vanishing white matter. Nat Genet 29:383–388

van der Knaap MS, Leegwater PAJ, Könst AAM, Visser A, Naidu S, Oudejans CBM, Schutgens RBH, Pronk JC (2002) Mutations in each of the five subunits of translation initiation factor eIF2B can cause leukoencephalopathy with vanishing white matter. Ann Neurol 51:264–270

van der Knaap MS, van der Voorn P, Barkhof F, Van Coster R, Krägeloh-Mann I, Feigenbaum A, Blaser S, Vles JSH, Rieckmann P, Pouwels PJW (2003) A new leukodystrophy with brain stem and spinal cord involvement and high lactate. Ann Neurol 53:252–258

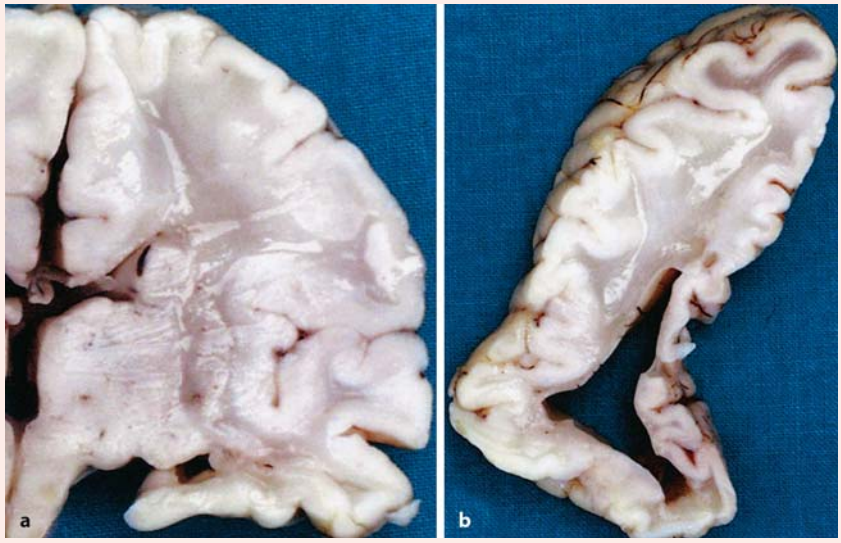

Fig. 3.21 Frontal sections through the frontal and temporal lobes (**a**) and the occipital lobe (**b**) in a fetal case of vanishing white matter disease (courtesy Caroline Van den Broecke, Gent)

Clinical Case 3.8
Porencephaly

Porencephaly is a severe brain malformation, usually occurring early in gestation owing to general hypoxia (see Case Report).

Case Report. The second child of healthy parents with a normal first child presented with a severe encephalopathy. MRI made in the third week after birth showed extensive defects in both cerebral hemispheres, particularly of the frontoparietal lobes, dilatated lateral ventricles and severe cerebellar hypoplasia (Fig. 3.22 a–d). No cerebral aqueduct could be identified. The boy died at the age of 3 months. At autopsy, brain weight was 280 g. Both hemispheres showed large defects, especially in the insular region, with polymicrogyria around the borders of the defects (Fig. 3.22 e). Aqueduct stenosis, a small, artificially torn corpus callosum, extremely reduced cerebellar hemispheres and absent pyramids (Fig. 6.35 e) were found.

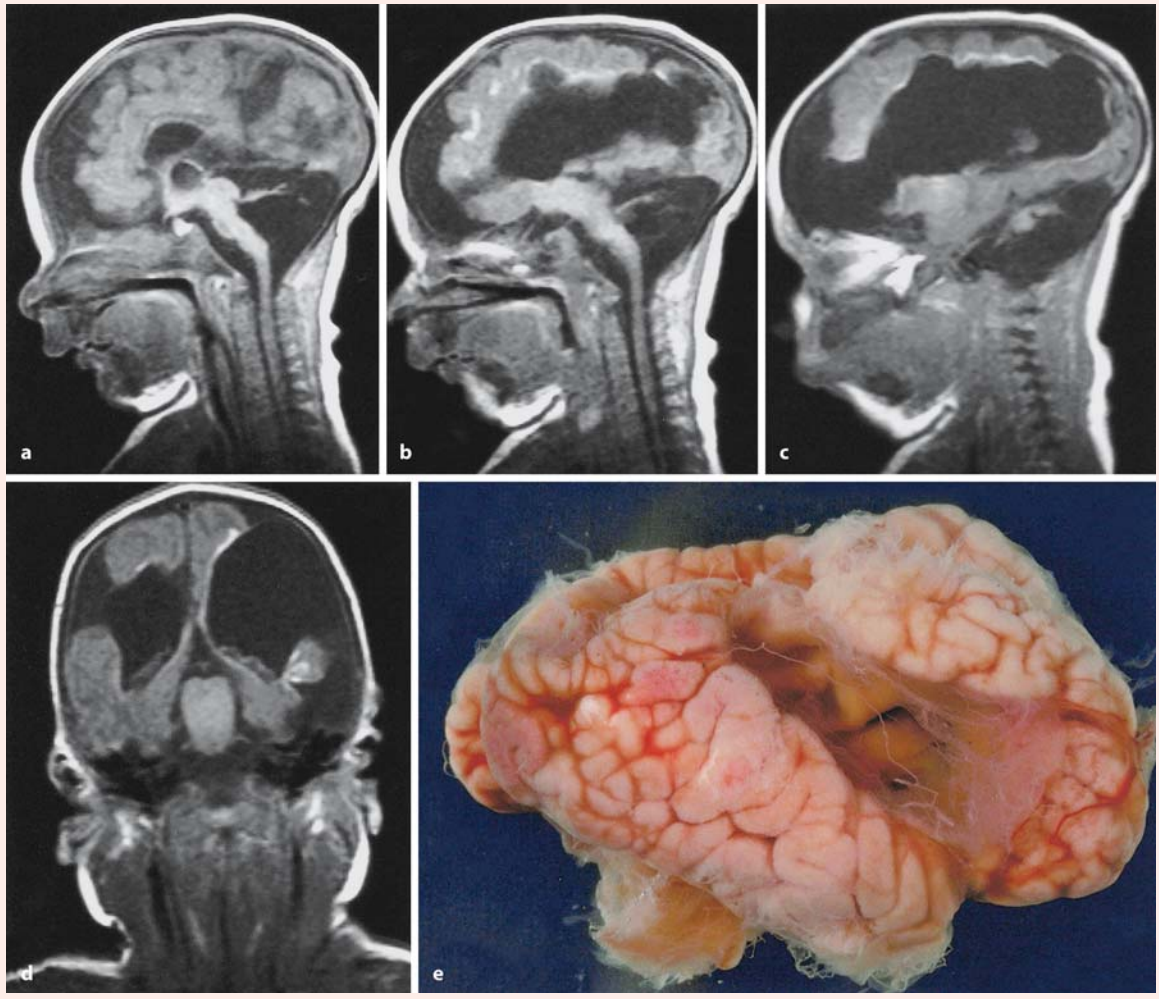

Fig. 3.22 Porencephaly in a 3-month-old male infant: **a**–**c**, sagittal MRI; **d** coronal MRI; **e** lateral view of the brain (courtesy Michèl Willemsen and Pieter Wesseling, Nijmegen)

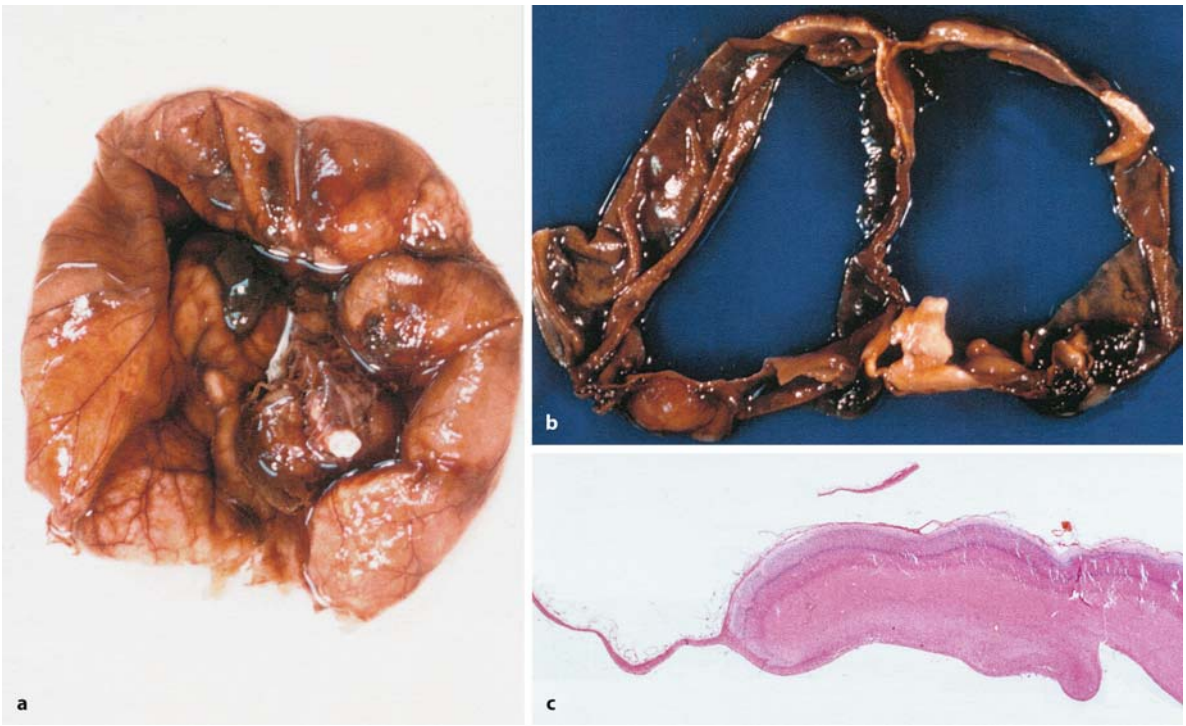

Fig. 3.23 Hydranencephaly due to intracranial haemorrhage in a term baby who survived 4 days: **a** basal view of brain; **b** coronal section of the cerebrum; **c** section through the cerebral cortex (from the Department of Neuropathology, Medizinische Hochschule Hannover; courtesy Akira Hori)

amniotic sac inflammation (Hansen and Snyder 1998). Other risk factors are clotting disorders. The periventricular haemorrhage may extend into the ventricle and ultimately give rise to hydrocephalus by blocking the narrow ventricular and arachnoidal pathways for CSF (Jackson and Blumhagen 1983; Hill and Rozdilsky 1984; Weindling 2002). It may also extend into the brain parenchyma and even give rise to infarction of the adjacent white matter. The latter will usually be haemorrhagic by obstruction of the draining veins (de Vries et al. 2001; Volpe 2001b). This is referred to as ***periventricular venous infarction*** (***PVI***). It provokes intraparenchymatous echodensity (IPE). In 10–15% of all preterm infants with a germinal matrix-intraventricular haemorrhage, a unilateral IPE occurs which leads to contralateral hemiplegia in two thirds of these patients (de Vries et al. 1998b). Recently, Takanashi et al. (2003) described five children born at term with congenital hemiplegia whose magnetic resonance images were compatible with PVI. This suggests that a clinically silent PVI in utero can lead to congenital hemiplegia at term. In contrast to ***periventricular leukomalacia*** (***PVL***), congenital hemiplegia is usually unilateral.

During the last trimester of pregnancy (26–36 weeks of gestation), the developing white matter is especially vulnerable to hypoxic–ischemic injuries. The resulting lesions are known as ***periventricular white matter disease***. The term periventricular leukomalacia is used for the state in which the periventricular white matter is destroyed and resorbed during the perinatal period in premature infants. The ischemia may be aggravated by the specific anatomical and physiological circumstances of the premature infant. Studies on the anatomy of the vascular supply to the white matter suggested that the deep white matter represented a watershed territory in this period (De Reuck et al. 1972). In a detailed anatomic study, Kuban and Gilles (1985) failed to demonstrate such a watershed zone (Nelson et al. 1991; Rorke 1992). Blood-flow studies showed that arterial flow to the white matter is low at this developmental period (Borch and Greisen 1998; Weindling 2002), and that blood vessel density in the white matter is lower between 28 and 36 weeks than in earlier or later periods of development (Miyawaki et al. 1998; Weindling 2002). More recently, the importance of intrauterine infection, resulting in elevation of proinflammatory cytokines, such as interleukin-6, interleukin-1β and tumour necrosis factor-α, has been emphasized (Kadhim et al. 2001). Another important factor, contributing to the vulnerability of the prenatal white matter, may be the intrinsic vulnerability of the developing oligodendroglial cells. Oligodendroglia

Clinical Case 3.9
Twin-to-Twin Transfusion

Twin-to-twin transfusion may lead to serious defects in the brain of one of the twins (see Case Report). Owing to abnormal blood shunting between the placentae in monochorionic biamniotic twins, perfusion failure may occur. This may result in cerebral damage, the extent of which is dependent on the state of development of the fetus. Polymicrogyria is commonly one of the characteristic malformations (Barth and van der Harten 1985; Larroche et al. 1994).

Case Report. This was the second pregnancy of nonsanguineous parents with one healthy child of 1 year old. Of the monozygotic twins, the female patient was severely affected, the second twin was completely normal. During pregnancy, disproportionate growth was noted and fetal movements were almost absent. At 27 weeks of gestation, polyhydramnios was recognized on ultrasound examination, and 2,000 ml of amniotic fluid was removed through amnion punctures in two sessions. The patient was born at 29 weeks of gestation and died a few minutes after birth owing to lung hypoplasia. The second of the twins was briefly admitted to the neonatal intensive care unit, but did well and showed no congenital malformations. The placenta was monochorionic and biamniotic. There was only one umbilical artery in the first twin and a velamentous insertion of its umbilical cord.

The weight of the girl was 730 g (less than P3). There was hyperextension of the neck and multiple joint contractures were evident. The elbows were fixed in flexion, whereas the hips were fixed in extension. There was clinodactyly and camptodactyly, the knees were extended with genua recurvata. On the left side a pes equinovarus was present, and on the right side a pes calcaneovarus. There was severe scoliosis. The lungs were very hypoplastic (5.6 g). General autopsy further revealed a small stomach, multiple renal cortical cysts and hepatomegaly. Brain weight was 120 g (normal range 174±38 g). On the lateral surface of the brain bilateral polymicrogyria was noted (Fig. 3.24). Microscopic examination showed that the polymicrogyric cortex was severely disrupted. No layering of neurons whatsoever could be observed. Ectopic groups of neuroglial cells were found in the meninges. The brain stem was quite normal. There was no dysplasia of either the inferior olives or the dentate nuclei.

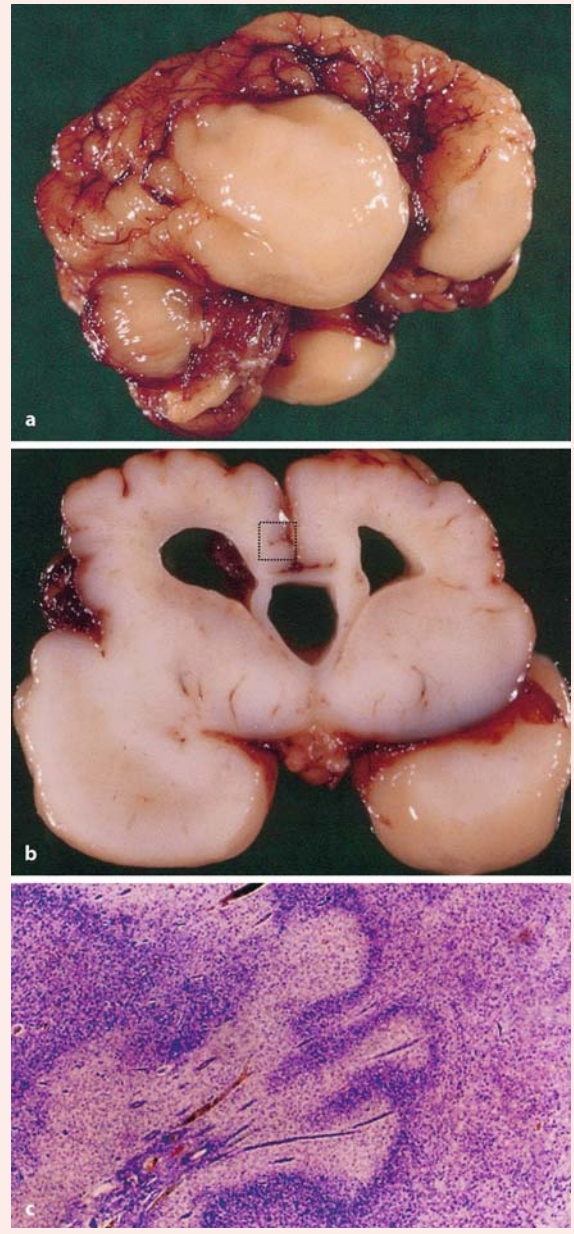

Fig. 3.24 Lateral view (**a**), frontal section (**b**) and detail of polymicrogyric cortex (**c**) in a case of twin-to-twin transfusion (courtesy Martin Lammens, Nijmegen).

References

Barth PG, van der Harten JJ (1985) Parabiotic twin syndromes with topical isocortical disruption and gastroschisis. Acta Neuropathol (Berl) 67:345–349

Larroche JC, Girard N, Narcy F, Gallet C (1994) Abnormal cortical plate (polymicrogyria), heterotopias and brain damage in monozygous twins. Biol Neonate 65:343–352

have glutamate receptors and may be damaged by excess glutamate release when neural tissue is damaged by ischemia (Kinney and Back 1998; McDonald et al. 1998; Volpe 2001 a, b). Three patterns of white matter damage, PVL, telencephalic leukoencephalopathy, and multicystic leukoencephalopathy, represent a spectrum of severity of damage (Volpe 2001 a, b; Squier 2002). Macroscopically, PVL is characterized by small areas of necrosis in the deep white matter (Fig. 3.25 b). The lesions appear yellow owing to calcium deposition and may become cavitated and cystic. Microscopically, in PVL widespread glial proliferation and capillary reactive changes are found. There is often axonal damage adjacent to areas of infarction. The term ***telencephalic leukoencephalopathy*** is used to describe diffuse reactive changes throughout the white matter of the cerebral hemispheres without focal infarction or cyst formation. In ***multicystic leukoencephalopathy***, the white matter contains many large cysts which may almost completely replace it (Clinical Case 3.10).

In neonates, haemorrhages are frequently found in the brain. The most frequent is subventricular haemorrhage, but if isolated it most often has no consequences (Volpe 2001a). An extensive isolated subarachnoidal bleeding in a neonate should raise suspicion for additional factors such as clotting disorders, of which ***neonatal alloimmune thrombocytopenia*** (***NAIT***) is the most frequent at this age (Clinical Case 3.11). This form of neonatal thrombocytopenia affects 1 per 1,000–2,000 deliveries (Müller-Eckhardt et al. 1989) with a mortality up to 14 % (Smith 2001). Infants may present with porencephaly or postdelivery intracranial haemorrhage. The cause of NAIT is incompatibility of the human platelet antigen-1 (HPA1) system in 80 % of European women, with a negative mother carrying a positive fetus expressing the antigen inherited from the father. Alloantibody to HPA-5b represents a relatively common cause of NAIT in Europe but results in less severe disease, and only rarely in intracranial haemorrhage and death (Herrero et al. 2003). HPA-4a induced NAIT is often severe but occurs almost exclusively among Asian populations (Glade-Bender et al. 2001). HPA-3a incompatibility represents less than 1 % of documented cases of NAIT but is similar in severity to disease caused by incompatibility of HPA-1a (Glade-Bender et al. 2001). Unlike Rhesus-incompatibility pregnancies, the first pregnancy is often affected. Isolated plexus haemorrhages most often are of no consequence.

Vascular malformations such as an ***aneurysm*** of the ***vein*** of ***Galen*** are rare and other arteriovenous malformations only rarely provoke intrauterine problems. Besides rare haemorrhages, malformation of the vein of Galen may also lead to important cerebral damage and ultimately brain atrophy due to ischemic complications (Norman and Becker 1974). They are most likely due to steal phenomena, leading to hypoperfusion in some adjacent or even remote parts of the brain (Grossman et al. 1984; Raybaud et al. 1989).

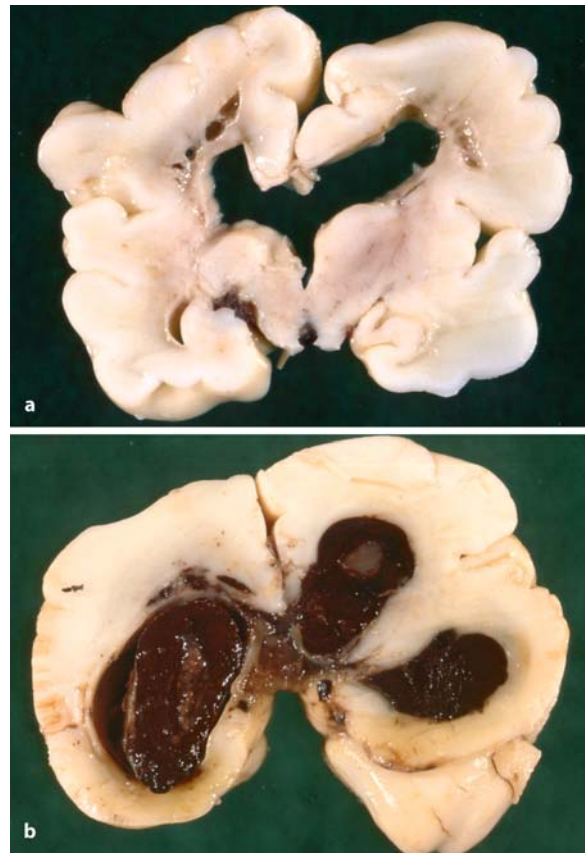

Fig. 3.25 Periventricular leukomalacia (**a**) and periventricular haemorrhage (**b**). See text for explanation

Focal arterial infarctions due to obstruction of a single cerebral artery are a rare phenomenon early in life. Estimates from brain imaging suggest an incidence of 0.2–0.35 per 1,000 neonates (Govaert et al. 2000). ***Perinatal ischemic stroke***, defined as a cerebrovascular event around the time of birth with pathological or radiological evidence of focal arterial infarction, is largely a disorder of term or near-term infants (de Vries et al.1997; Govaert et al. 2000; Nelson and Lynch 2004). The middle cerebral artery is most often involved. The left hemisphere is more frequently affected than the right, probably owing to haemodynamic differences from a patent ductus arteriosus (Trauner et al. 1993). Perinatal-stroke risk factors include cardiac, blood, homocystein and lipid disorders, infections, maternal and placental diseases, and iatrogenic interventions such as catheterization and extracorporeal membrane oxygenation (Nelson and Lynch 2004). Although rare, perinatal stroke can also

Clinical Case 3.10
Multicystic Leukoencephalopathy

Multicystic leukoencephalopathy is the most severe form of white matter damage (Volpe 2001; Squier 2002), in which the white matter is largely replaced by cysts (see Case Report). The lesions of the grey matter in this case are typical for an episode of complete asphyxia in a full-term neonate. They consist of severe necrosis of the deep brain nuclei, the neocortex and the hippocampus. The reason for the perinatal asphyxia was not entirely clear, but was probably placental in origin.

Case Report. After an uneventful pregnancy, birth at full term at home presented unexpected difficulties. Deteriorating heart tones resulted in the transport of the mother to the hospital. Owing to traffic problems, transport took more than 1 h, after which a boy was born with low Apgar scores. Epileptic fits were present from the first day but no spontaneous movements were noted. MRI after 1 month showed severe leukomalacia. The infant died after 1 week of fluid refusal at 6 weeks of age. At autopsy, brain weight was 300 g. There was complete neuronal loss of the deep nuclei (Fig. 3.26 a), including the basal ganglia and the thalamus, with severe gliosis and partial pseudocystic necrosis of these nuclei. Large parts of the neocortex were also severely necrotic with sparing of the occipital lobes. The top of each sulcus affected was always better preserved than its base. Ultimately, this necrosis would result in ulegyria. On both sides, the hippocampus and the subiculum were almost completely necrotic. In the cerebellum partial loss of Purkinje cells and of some cells in the dentate nuclei was found. The supratentorial white matter was almost completely necrotic except for part of the occipital white matter, leading to porencephaly. The white matter of the cerebellum and the brain stem was partly gliotic, but better preserved than the supratentorial parts. The meningeal arteries showed distinct intima fibrosis and calcification of the inner part of the media (Fig. 3.26 b).

References

Squier W (2002) Pathology of fetal and neonatal brain damage: Identifying the timing. In: Squier W (ed) Acquired Damage to the Developing Brain: Timing and causation. Arnold, London, pp 110–127

Volpe JJ (2001) Neurology of the Newborn, 4th ed. Saunders, Philadelphia, PA

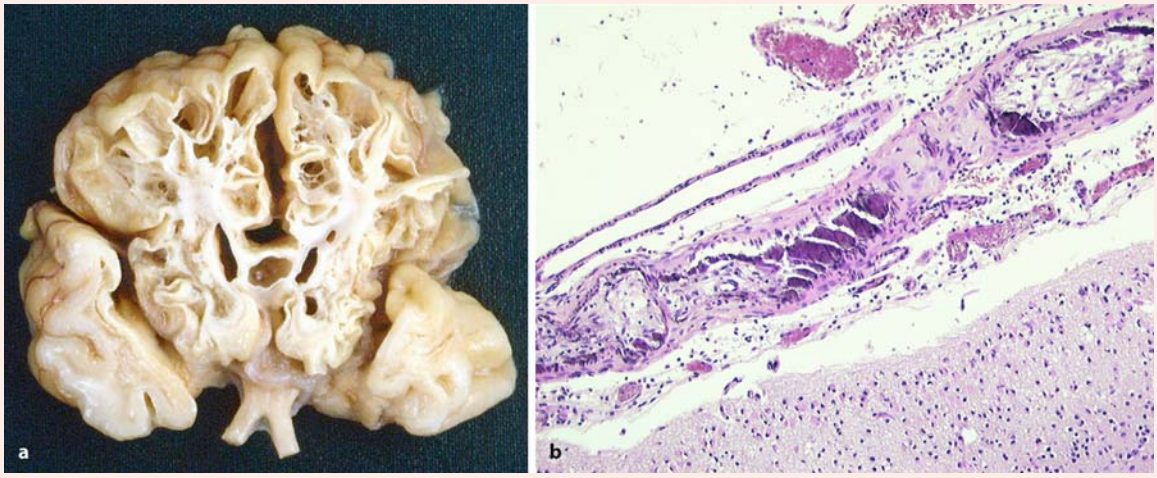

Fig. 3.26 Multicystic leukoencephalopathy: **a** frontal section through the frontal and temporal lobes; **b** intima fibrosis and media calcification of meningeal arteries (courtesy Martin Lammens, Nijmegen)

occur in term infants with neonatal encephalopathy, owing to underlying infections or endocrine disorders of the mother (Ramaswamy et al. 2004).

Generalized ischemic or perfusion failure may lead to ***selective necrosis*** of particular groups of neurons. The selective vulnerability of neuronal groups is dependent on regional vascular and metabolic factors (Volpe 2001b). The so-called ***watershed infarct***, in which neuronal injury is more prominent in border zones between vascular territories, is the most prominent example of regional vascular factors. This may explain the parasagittal cerebral injury at the

Clinical Case 3.11
Neonatal Alloimmune Thrombocytopenia

Extensive isolated subarachnoidal bleeding in a neonate is often due to ***neonatal alloimmune thrombocytopenia***. A case of fetomaternal alloimmune thrombocytopenia due to HPA-5b incompatibility came to autopsy (see Case Report).

Case Report. During the first pregnancy of a mother with Sjögren syndrome, intrauterine growth retardation of the fetus was observed at 31 weeks of gestation. Caesarean section was carried out because of a deteriorating cardiotocogram, and a boy of 1,180 g and 39-cm length was born. Apgar scores were 8 and 9, and no meconium-staining of the amniotic fluid was found. The placenta showed no abnormalities. A few hours later, the boy was transferred to a university hospital because of acute respiratory failure. His clinical condition rapidly deteriorated. Ultrasound examination showed a massive intracranial haemorrhage. The boy died 22 h after birth. At autopsy, brain weight was 222 g. Recent massive subarachnoidal haemorrhages were found at the base of both temporal lobes (Fig. 3.27 b) and at the superior surface of the cerebellum. Microscopic haemorrhages were seen in the cerebral white matter, but no large intracerebral bleedings. No other abnormalities were found. In the blood of the mother immunoglobulin G antibodies against thrombocytes were found. The father appeared to be heterozygous for HPA-5a/HPA-5b. Fetomaternal alloimmune thrombocytopenia due to HPA-5b was demonstrated in the fetus and, most probably, caused the unusually large subarachnoidal bleeding.

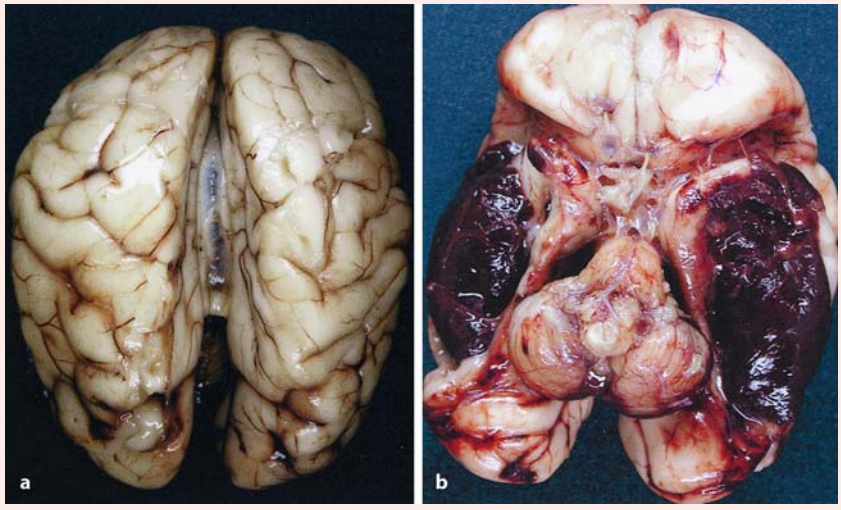

Fig. 3.27 Dorsal (**a**) and ventral (**b**) views of the brain in a case of neonatal alloimmune thrombocytopenia (courtesy Martin Lammens, Nijmegen). Note the massive subarachnoidal haemorrhages at the base of both temporal lobes

border zone between the anterior and middle cerebral artery territories, characterized by a lesion of the cerebral cortex and subcortical white matter on the parasagittal superomedial aspects of the cerebral convexities (Friede 1989; Volpe 2001b). The depths of the sulci are more vulnerable than the tops owing to the fact that they form a relatively avascular area between penetrating meningeal arteries in the near-term infant brain. This leads to ulegyria. Differences in regional distribution of glutamate receptors of the *N*-methyl-D-aspatate type, in metabolic rate or in NADPH-diaphorase activity are examples of regional metabolic factors which play a role in the selective vulnerability of groups of neurons in the brain stem, the striatum and the hippocampus (Chaps. 7, 9, 10).

3.7 Classifications of CNS Malformations

Traditional schemes of classifying CNS malformations are based on descriptive morphogenesis of the brain and spinal cord. Usually, neural tube defects are discussed separately. Abnormalities of the cerebral hemispheres are grossly subdivided into the prosencephalies and neuronal migration disorders. Other malformations are mostly discussed regionally, such as those of the spinal cord, the brain stem and the cerebellum. Since we discussed the development of the CNS regionally, in this book we have also followed a more or less regional approach for developmental disorders of the CNS. Recently, Sarnat (Sarnat 2000;

Table 3.8 Molecular classification of malformations of early CNS development (after Sarnat 2000)

Proposed molecular genetic classification	Further subdivision	Selected specific disorders
I. Genetic mutations expressed in the primitive streak or node	A. Upregulation of organizer genes	1. Duplication of neural tube
	B. Downregulation of organizer genes	1. Agenesis of neural tube, partial or complete
II. Disorders of ventralizing gradient in the neural tube	A. Overexpression of ventralizing genes	1. Duplication of spinal central canal 2. Duplication of ventral horns of spinal cord 3. Diplomyelia (Clinical Case 6.1) 4. Duplication of neural tube 5. Ventralizing induction of somite (segmental amyoplasia)
	B. Underexpression of ventralizing genes	1. Fusion of ventral horns of spinal cord 2. Sacral (thoracolumbosacral) agenesis (Chap. 3) 3. Arhinencephaly (Chap. 9) 4. Holoprosencephaly (Chap. 9)
III. Disorders of dorsalizing gradient of the neural tube	A. Overexpression of dorsalizing genes	1. Duplication of dorsal horns of spinal cord 2. Duplication of dorsal brain stem structures
	B. Underexpression of dorsalizing genes	1. Fusion of dorsal horns of spinal cord 2. Fusion of midbrain colliculi 3. Rhombencephalosynapsis (Clinical Case 8.1) 4. Septo-optic dysplasia (Clinical Case 9.7)?
IV. Disorders of the rostrocaudal gradient and/or segmentation	A. Increased homeobox domains and/or ectopic expression	1. Chiari II malformation
	B. Decreased homeobox domains and/or neuromere deletion	1. Agenesis of mesencephalon and metencephalon (Clinical Case 7.1) 2. Global cerebellar aplasia or hypoplasia 3. Agenesis of basal telencephalic nuclei (Chap. 9) 4. Agenesis of corpus callosum (some cases)
V. Aberrations in cell lineages by genetic mutation	A. Non-neoplastic	1. Striated muscle in CNS 2. Dysplastic gangliocytoma of cerebellum (Lhermitte–Duclos; Chap. 8) 3. Tuberous sclerosis (Chap. 10)
	B. Neoplastic	1. Myomedulloblastoma 2. Dysembryoplastic neuroepithelial tumours
VI. Disorders of secretory molecules and genes that mediate neuronal migration (Chap. 10)	A. Mediating neuroblast migration	1. Initial course of neuroblast migration (Filamin-1: X-linked periventricular nodular heterotopia) 2. Middle course of neuroblast migration (subcortical laminar heterotopia or band heterotopia; Miller–Dieker syndrome; Fukuyama muscular dystrophy) 3. Late course of neuroblast migration, differentiation of cortical plate (Reelin and Disabled-related NMDs)
	B. Mediating glioblast migration	
VII. Disorders of secretory molecules and genes that attract and repel axonal growth cones	A. Netrin downregulation	*ROBO3*-deficiency (Chap. 6)
	B. Downregulation of keratan sulfate and other glycosaminoglycans	

Sarnat and Flores-Sarnat 2004) proposed a molecular genetic classification of CNS malformations. His approach is summarized in Table 3.8. The premises of this classification are as follows: (1) genetic expression in the neural tube follows gradients along the axes that are established during gastrulation (Chaps. 1, 2), vertical (dorsoventral or ventrodorsal), rostrocaudal and mediolateral; (2) overexpression in one of these gradients may result in duplication or hypoplasia of structures, or ectopic expression; (3)

underexpression in a gradient generally results in hypoplasia, non-cleavage in the midline of paired structures or segmental deletion of neuromeres. Some examples are shown in clinical cases in other chapters of this book.

References

Achiron R, Achiron A (1991) Transvaginal ultrasonic assessment of the early fetal brain. Ultrasound Obstet Gynecol 1:336–344

Ahdab-Barmada M, Claassen D (1990) A distinct triad of malformations of the central nervous system in the Meckel-Gruber syndrome. J Neuropathol Exp Neurol 49:610–620

Aicardi J (1998) Diseases of the Nervous System in Childhood, 2nd ed. Mac Keith, London

Amin RS, Nikolaidis P, Kawashima A, Kramer LA, Ernst RD (1999) Normal anatomy of the fetus at MR imaging. Radiographics 19:S201–214

Anderson CE (1995) The genetics of disorders of the developing nervous system. In: Duckett S (ed) Pediatric Neuropathology. Williams & Wilkins, Baltimore, MD, pp 41–53

Antonarakis SE (1991) Parental origin of the extra chromosome 21 as indicated by analysis of DNA polymorphisms. Down Syndrome Collaborative Group. N Engl J Med 324:872–876

Arts NFT, Lohman AHM (1971) The vascular anatomy of monochorionic diamniotic twin placenta and the transfusion syndrome. Eur J Obstet Gynecol Reprod Biol 1:85–93

Bamforth JS (1992) Amniotic band sequence: Streeter's hypothesis re-examined. Am J Med Genet 44:280–287

Barkovich AJ (2000) Pediatric Neuroimaging, 3rd ed. Lippincott, Philadelphia, PA

Barkovich AJ, Linden CL (1994) Congenital cytomegalovirus infection of the brain: Imaging analysis and embryonic considerations. AJNR Am J Neuroradiol 15:703–715

Barkovich AJ, Kjos BO, Norman D, Edwards MS (1989) Revised classification of posterior fossa cysts and cystlike malformations based on the results of multiplanar MR imaging. Am J Roentgenol 153:1289–1300

Barkovich AJ, Kuzniecky RI, Jackson GD, Guerrini R, Dobyns WB (2001) Classification system for malformations of cortical development. Update 2001. Neurology 57:2168–2178

Barth PG (2003) Fetal disruption as a cause of neuronal migration defects. In: Barth PG (ed) Disorders of Neuronal Migration. Mac Keith, London, pp 182–194

Barth PG, van der Harten JJ (1985) Parabiotic twin syndromes with topical isocortical disruption and gastroschisis. Acta Neuropathol (Berl) 67:345–349

Becker LE (1992) Infections of the developing brain. AJNR Am J Neuroradiol 13:537–549

Beltrán-Valero de Bernabé D, Currier S, Steinbrecher A, Celli J, van Beusekom E, van der Zwaag B, Kayserili H, Merlini L, Chitayat D, Dobyns WB, et al. (2002) Mutations in the O-mannosyltransferase gene *POMT1* give rise to the severe neuronal migration disorder Walker-Warburg syndrome. Am J Hum Genet 71: 1033–1043

Benirschke K, Kaufman P (1995) Pathology of the Human Placenta. Springer, Berlin Heidelberg New York

Blaas H-GK (1999) The Embryonic Examination. Ultrasound studies on the development of the human embryo. Thesis, Norwegian University of Science and Technology, Trondheim. TAPIR, Trondheim

Blaas H-GK, Eik-Nes SH (1999) First trimester diagnosis of fetal malformations. In: Rodeck CH, Whittle MJ (eds) Fetal Medicine. Churchill Livingstone, London, pp 581–597

Blaas H-GK, Eik-Nes SH, Kiserud T, Hellevik LR (1994) Early development of the forebrain and midbrain: A longitudinal ultrasound study from 7 to 12 weeks of gestation. Ultrasound Obstet Gynecol 4:183–192

Blaas H-GK, Eik-Nes SH, Isaksen CV (2000) The detection of spina bifida before 10 gestational weeks using two- and three-dimensional ultrasound. Ultrasound Obstet Gynecol 16:25–29

Blaas H-GK, Eriksson AG, Salvesen KÅ, Isaksen CV, Christensen B, Møllerløkken G, Eik-Nes SH (2002) Brains and faces in holoprosencephaly: Pre- and postnatal description of 30 cases. Ultrasound Obstet Gynecol 19:24–38

Bonnemann C, Meinecke P (1990) Holoprosencephaly as a possible embryonic alcohol effect: Another observation. Am J Hum Genet 37:431–432

Borch K, Greisen G (1998) Blood flow distribution in the normal human preterm brain. Pediatr Res 43:28–33

Bordarier C, Robain O (1992) Microgyric and necrotic cortical lesions in twin fetuses: Original cerebral damage consecutive to twinning? Brain Dev 14:174–178

Boyd PA, Keeling JW, Selinger M, MacKenzie IZ (1990) Limb reduction and chorion villus sampling. Prenat Diagn 10:437–441

Braude P, Pickering S, Flinter F, Mackie Ogilvie C (2002) Preimplantation genetic diagnosis. Nat Rev Genet 3:941–953

Brock DJH, Rodeck CH, Ferguson Smith MA, eds (1992) Prenatal Diagnosis and Screening. Churchill Livingstone, Edinburgh

Brown GK, Squier MV (1996) Neuropathology and pathogenesis of mitochondrial diseases. J Inher Metab Dis 19:553–572

Brown GK, Brown RM, Scholem RD, Kirby DM, Dahl H-HM (1989) The clinical and biochemical spectrum of human pyruvate dehydrogenase complex deficiency. Ann NY Acad Sci 573: 360–368

Cairns NJ (1999) Neuropathology of Down syndrome. J Neural Transm 57:61–74

Cardoza JD, Goldstein RB, Filly RA (1988) Exclusion of fetal ventriculomegaly with a single measurement: The width of the lateral ventricular atrium. Radiology 163:187–191

Chambers CD, Johnson KA, Dick LM, Felix RJ, Jones KL (1998) Maternal fever and birth outcome: Prospective study. Teratology 58:251–257

Chattha A, Richardson E (1977) Cerebral white matter hypoplasia. Arch Neurol 34:137–140

Cherstvoy ED, Lazjuk GI, Lurie IW, Nedzved MK, Usoev S (1975) The pathological anatomy of Smith-Lemli-Opitz syndrome. Clin Genet 7:382–387

Chitkara U, Cogswell C, Norton K, Wilkins IA, Mehalek K, Berkowitz RL (1988) Choroid plexus cysts in the fetus: A benign anatomic variant or pathological entity? Report of 41 cases and review of the literature. Obstet Gynecol 72:185–189

Chitty LS, Hunt GH, Moore J, Lobb MO (1991) Effectiveness of routine ultrasonography in detecting fetal structural abnormalities in a low risk population. BMJ 303:1165–1169

Chitty LS, Chudleigh P, Wright E, Campbell S, Pembrey M (1998) The significance of choroid plexus cysts in unselected populations: Results of a multicenter study. Ultrasound Obstet Gynecol 12:391–397

Clarren SK, Alvord EC Jr, Sumi SM, Steissguth AP, Smith DW (1978) Brain malformations related to prenatal exposure to ethanol. J Pediatr 92:64–67

Cohen MM Jr, Shiota K (2002) Teratogenesis of holoprosencephaly. Am J Med Genet 109:1–15

Cunniff C, Kratz LE, Moser A, Natowicz MR, Kelley RI (1997) Clinical and biochemical spectrum of patients with RSH/Smith-Lemli-Opitz syndrome and abnormal cholesterol metabolism. Am J Med Genet 68:263–269

de la Monte SM (1999) Molecular abnormalities of the brain in Down syndrome: Relevance to Alzheimer's neurodegeneration. J Neural Transm 57:1–20

De Reuck J, Chattha AS, Richardson EPJ (1972) Pathogenesis and evolution of periventricular leukomalacia in infancy. Arch Neurol 27:229–236

de Vries LS, Groenendaal F, Eken P, van Haastert IC, Rademaker KJ, Meiners LC (1997) Infarcts in the vascular distribution of the middle cerebral artery in preterm and fullterm infants. Neuropediatrics 28:88–96

de Vries LS, Eken P, Groenendaal F, Rademaker KJ, Hoogervorst B, Bruinse HW (1998a) Antenatal onset of haemorrhagic and/or ischaemic lesions in preterm infants: Prevalence and associated obstetric variables. Arch Dis Childh Fetal Neon Ed 78: F51–F56

de Vries LS, Rademaker KJ, Groenendaal F, Eken P, van Haastert IC, Vandertop WP, Gooskens R, Meiners LC (1998b) Correlation between neonatal cranial ultrasound, MRI in infancy and neurodevelopmental outcome in infants with a large intraventricular haemorrhage with or without parenchymal involvement. Neuropediatrics 29:180–188

de Vries LS, Roelants-van Rijn AM, Rademaker KJ, van Haastert IC, Beek FJ, Groenendaal F (2001) Unilateral parenchymal haemorrhagic infarction in the preterm infant. Eur J Paediatr Neurol 5:139–149

de Vries LS, Gunardi H, Barth PG, Bok LA, Verboon-Maciolek MA, Groenendaal F (2004) The spectrum of cranial ultrasound and magnetic resonance imaging abnormalities in congenital cytomegalovirus infection. Neuropediatrics 35:113–119

Dobyns WB (1989) Agenesis of the corpus callosum and gyral malformations are frequent manifestations of nonketotic hyperglycinemia. Neurology 39:817–820

Donnai D, Winter RM (1989) Disorganisation: A model for 'early amnion rupture'? J Med Genet 26:421–425

Down JLH (1866) Observations on the ethnic classification of idiots. Clin Lect Rep Lond Hosp 3:259

Eberle AM, Levesque D, Vintzileos AM, Egan JF, Tsapanos V, Salafia CM (1993) Placental pathology in discordant twins. Am J Obstet Gynecol 169:931–935

Edwards JH, Harnden DG, Cameron AH, Crosse VM, Wolff OH (1960) A new trisomic syndrome. Lancet 1960 (i):787

Edwards MJ, Shiota K, Smith MSR, Walsh DA (1995) Hyperthermia and birth defects. Reprod Toxicol 9:411–425

Edwards MJ, Saunders RD, Shiota K (2003) Effects of heat on embryos and foetuses. Int J Hyperthermia 19:295–324

Epstein CJ, Erickson RP, Wynshaw-Boris A, eds (2004) Inborn Errors of Development. The molecular basis of clinical disorders of morphogenesis. Oxford University Press, Oxford

Fierro M, Martinez AJ, Harbison JW, Hay SH (1977) Smith-Lemli-Opitz syndrome: Neuropathological and ophthalmological observations. Dev Med Child Neurol 19:57–62

Firth HV (1997) Chorion villus sampling and limb deficiency–cause or coincidence? Prenat Diagn 17:1313–1330

Fitzky BU, Witsch-Baumgarten M, Erdel M, Lee JN, Paik YU, Glossmann H, Uterman G, Moebius FF (1998) Mutations in the delta7-sterol reductase gene in patients with the Smith-Lemli-Opitz syndrome. Proc Natl Acad Sci USA 95:8181–8186

Fitzpatrick D (2001) Genetic metabolic disease. In: Keeling JW (ed) Fetal and Neonatal Pathology, 3rd ed. Springer, Berlin Heidelberg New York, pp 153–174

FitzPatrick DR, Keeling JW, Evans MJ, Kan AE, Bell JE, Porteous MEM, Mills K, Winter RM, Clayton PT (1998) Clinical phenotype of desmosterolosis. Am J Med Genet 75:145–152

Friede RL (1989) Developmental Neuropathology, 2nd ed. Springer, Berlin Heidelberg New York

Gardner RJM, Sutherland GR (1996) Chromosome Abnormalities and Genetic Counselling, 2nd ed. Oxford University Press, Oxford

Garel C (2004) MRI of the Fetal Brain. Normal development and cerebral pathologies. Springer, Berlin Heidelberg New York

Gerards FA, Engels MA, Barkhof, van den Dungen FA, Vermeulen RJ, van Vugt JM (2003) Prenatal diagnosis of aneurysms of the vein of Galen (vena magna cerebri) with conventional sonography, three-dimensional sonography, and magnetic resonance imaging: Report of 2 cases. J Ultrasound Med 22:1363–1368

Gilbert-Barness E (1997) Chromosomal abnormalities. In: Gilbert-Barness E (ed) Potter's Pathology of the Fetus and Infant. Mosby, St. Louis, MI, pp 368–432

Gilbert-Barness E, Van Allen MI (1997) Disruptions. In: Gilbert-Barness E (ed) Potter's Pathology of the Fetus and Infant. Mosby, St. Louis, MI, pp 322–387

Gibson KM, Hoffmann GF, Sweetman L, Buckingham B (1997) Mevalonate kinase deficiency in a dizygotic twin with mild mevalonic aciduria. J Inherit Metab Dis 20:391–394

Glade-Bender J, McFarland JG, Kaplan C, Porcelijn L, Bussel JB (2001) Anti-HPA-3A induces severe neonatal alloimmune thrombocytopenia. J Pediatr 138:862–867

Goodman SI, Frerman FE (2001) Organic acidemias due to defects in lysine oxidation: 2-Ketoadipic acidemia and glutaric acidemia. In: Scriver CR, Beaudet AL, Sly WS, Valle D (eds) The Metabolic & Molecular Bases of Inherited Disease, 8th ed. McGraw-Hill, New York, pp 2195–2206

Gorlin RJ, Cohen MM Jr, Hennekam RCM, eds (2001) Syndromes of the Head and Neck, 4th ed. Oxford University Press, Oxford

Gould SJ, Raymond GV, Valle D (2001) The peroxisome biogenesis disorders. In: Scriver CR, Beaudet AL, Sly WS, Valle D (eds) The Metabolic & Molecular Bases of Inherited Disease, 8th ed. McGraw-Hill, New York, pp 3181–3218

Govaert P, Matthys E, Zecic A, Roelens F, Oostra A, Vanzieleghem B (2000) Perinatal cortical infarction within middle cerebral artery trunks. Arch Dis Child Fetal Neonatal Ed 82:F59–F63

Grandjean H, Larroque D, Levi S, and the Eurofetus Study Group (1999) The performance of routine ultrasonographic screening of pregnancies in the Eurofetus Study. Am J Obstet Gynecol 181:446–454

Grossman RI, Bruce DA, Zimmerman RA, Goldberg HI, Bilaniuk LT (1984) Vascular steal associated with vein of Galen aneurysm. Neuroradiology 26:381–386

Haas D, Kelley RI, Hoffmann GF (2001) Inherited disorders of cholesterol biosynthesis. Neuropediatrics 32:113–132

Hall JG (1988) Review and hypotheses: Somatic mosaicism; observations related to clinical genetics. Am J Hum Genet 43:355–363

Hamel BCJ (1999) X-Linked Mental Retardation. A clinical and molecular study. Thesis, University of Nijmegen

Hamosh A, Johnston MV (2001) Nonketotic hyperglycinemia. In: Scriver CR, Beaudet AL, Sly WS, Valle D (eds) The Metabolic & Molecular Bases of Inherited Disease, 8th ed. McGraw-Hill, New York, pp 2065–2078

Hansen AR, Snyder EY (1998) Medical management of neonatal posthemorrhagic hydrocephalus. Neurosurg Clin N Am 9:95–104

Happle R, Koch H, Lenz W (1980) The CHILD syndrome: Congenital hemidysplasia with ichthyosiform erythroderma and limb defects. Eur J Ped Surg 134:27–33

Herrero RJ, Chitrit Y, Caubel P, Lusina D (2003) Feto-maternal alloimmune thrombocytopenia due to HPA-5b incompatibility: A case report. Eur J Obstet Gynecol Reprod Biol 110:240–241

Higginbottom MC, Jones KL, Hall BD, Smith SW (1979) The amniotic band disruption complex: Timing of amniotic rupture and variable spectra of consequent defects. J Pediatr 95:544–549

Hill A, Rozdilsky B (1984) Congenital hydrocephalus secondary to intra-uterine germinal matrix/intraventricular haemorrhage. Dev Med Child Neurol 26:524–527

Hoffmann GF, Gibson KM, Brandt IK, Bader PI, Wappner RS, Sweetman L (1986) Mevalonic aciduria–an inborn error of cholesterol and nonsterol isoprene biosynthesis. N Engl J Med 314:1610–1614

Hoffmann GF, Charpentier C, Mayatepek E, Mancini J, Leichsenring M, Gibson KM, Divry P, Hrebicek M, Lehnert W, Sarton K, et al. (1993) Clinical and biochemical phenotype in eleven patients with mevalonic aciduria. Pediatrics 91:915–921

Hori A, Orthner H, Kohlschütter A, Schott KM, Hirabayashi K, Shimokawa K (1980) CNS dysplasia in dysencephalia splanchnocystica (Gruber's syndrome). Acta Neuropathol (Berl) 51:93–97

Hubbard AM, Harty MP, States LJ (1999) A new tool for prenatal diagnosis: Ultrafast fetal MRI. Semin Perinatol 23:437–447

Iannetti P, Nigro G, Spalice A, Faiella A, Boncinelli E (1998) Cytomegalovirus infection and schizencephaly: Case reports. Ann Neurol 43:123–127

Inoue K, Osaka H, Sugiyama N, Kawanishi C, Onishi H, Nezu A, Kimura K, Kimura S, Yamada Y, Kosaka K (1996) A duplicated PLP causing Pelizaeus-Merzbacher disease detected by comparative multiplex PCR. Am J Hum Genet 59:32–39

Irons M, Elias ER, Salen G, Tint GS, Batta AK (1993) Defective cholesterol biosynthesis in Smith-Lemli-Opitz syndrome. Lancet 1993 (i):1414

Jackson JC, Blumhagen JD (1983) Congenital hydrocephalus due to prenatal intracranial hemorrhage. Pediatrics 72:344–346

Jaeken J, Carchon H (2001) Congenital disorders of glycosylation: The rapidly growing tip of the iceberg. Curr Opin Neurol 14:811–815

Jaeken J, Matthijs G (2001) Congenital disorders of glycosylation. Annu Rev Genomics Hum Genet 2:129–152

Jaeken J, Matthijs G, Carchon H, Van Schaftingen E (2001) Defects of N-glycan synthesis. In: Scriver CR, Beaudet AL, Sly WS, Valle D (eds) The Metabolic & Molecular Bases of Inherited Disease, 8th ed. McGraw-Hill, New York, pp 1601–1622

Jinnah HA, Friedmann T (2001) Lesch-Nyhan disease and its variants. In: Scriver CR, Beaudet AL, Sly WS, Valle D (eds) The Metabolic & Molecular Bases of Inherited Disease, 8th ed. McGraw-Hill, New York, pp 2537–2570

Jones KL (1997) Smith's Recognizable Patterns of Human Malformation, 5th ed. Saunders. Philadelphia, PA

Kadhim H, Tabarki B, Verellen G, de Prez C, Rona AM, Sebire C (2001) Inflammatory cytokines in the pathogenesis of periventricular leukomalacia. Neurology 56:1278–1284

Källén B, Mastroiacovo P, Robert E (1996) Major congenital malformations in Down syndrome. Am J Med Genet 65:160–166

Kalousek DK (1997) Pathology of abortion: The embryo and the previable fetus. In: Gilbert-Barness E (ed) Potter's Pathology of the Fetus and Infant. Mosby, St. Louis, MI, pp 106–127

Kalousek DK, Fitch N, Paradice BA (1990) Pathology of the Human Embryo and Previable Fetus. An atlas. Springer, Berlin Heidelberg New York

Keeling JW, Boyd PA (2001) Congenital abnormalities and the examination of the fetus following prenatal suspicion of congenital abnormality. In: Keeling JW (ed) Fetal and Neonatal Pathology, 3rd ed. Springer, Berlin Heidelberg New York, pp 111–152

Kelley RI, Hennekam RCM (2000) The Smith-Lemli-Opitz syndrome. J Med Genet 37:321–335

Kelley RI, Herman GE (2001) Inborn errors of sterol biosynthesis. Annu Rev Genomics Hum Genet 2:299–341

Kelley RI, Roessler E, Hennekam RCM, Feldman GL, Kosaki K, Jones MC, Palumbos JC, Muenke M (1996) Holoprosencephaly in RSH/Smith-Lemli-Opitz syndrome: Does abnormal cholesterol metabolism affect the function of *Sonic hedgehog*? Am J Med Genet 66:478–484

Kerrigan JF, Aleck KA, Tarby TJ, Bird CR, Heidenreich RA (2000) Fumaric aciduria: Clinical and imaging features. Ann Neurol 47:583–588

Kinney HC, Back SA (1998) Human oligodendroglial development: Relationship to periventricular leukomalacia. Sem Pediatr Neurol 5:180–189

Kobayashi K, Nakahori Y, Miyake M, Matsumura K, Kondo-Iida E, Nomura Y, Segawa M, Yoshioka M, Saito K, Osawa M, et al. (1998) An ancient retrotransposal insertion causes Fukuyama-type congenital muscular dystrophy. Nature 394:388–392

Koeppen AH, Robitaille Y (2002) Pelizaeus-Merzbacher disease. J Neuropathol Exp Neurol 61:747–759

Kraus I, Jirásek JE (2002) Some observations of the structure of the choroid plexus and its cysts. Prenat Diagn 22:1223–1228

Kuban KC, Gilles FH (1985) Human telencephalic angiogenesis. Ann Neurol 17:539–548

Lammens M (1997) Developmental Neuropathology in Etiology and Pathogenesis of Human Malformations: A personal contribution. Thesis, University of Leuven, Belgium (Acta Biomedica Lovaniensia, Vol 154)

Lammer EJ, Chen DT, Hoar RM, Agnish ND, Benke PJ, Braun JT, Curry CJ, Fernhoff PM, Grix AW, Lott IT (1985) Retinoic acid embryopathy. N Engl J Med 313:837–841

Larroche JC, Girard N, Narcy F, Fallet C (1994) Abnormal cortical plate (polymicrogyria), heterotopias and brain damage in monozygous twins. Biol Neonate 65:343–352

Laxova R (1997) Prenatal diagnosis. In: Gilbert-Barness E (ed) Potter's Pathology of the Fetus and Infant. Mosby, St. Louis MI, pp 182–240

Leegwater PAJ, Könst AAM, Kuyt B, Sandkuijl LA, Naidu S, Oudejans CBM, Schutgens RBH, Pronk JC, van der Knaap MS (1999) The gene for leukoencephalopathy with vanishing white matter is located on chromosome 3q27. Am J Hum Genet 65:728–734

Leegwater PAJ, Vermeulen G, Könst AAM, Naidu S, Mulders J, Visser A, Kersbergen P, Mobach D, Fonds D, van Berkel CGM, et al. (2001) Subunits of the translation initiation factor eIF2B are mutated in leukoencephalopathy with vanishing white matter. Nat Genet 29:383–388

Leigh D (1951) Subacute necrotizing encephalomyelopathy in an infant. J Neurol Neurosurg Psychiatr 14:216–221

Levi S (1998) Routine ultrasound screening of congenital anomalies. An overview of the European experience. Ann NY Acad Sci 847:86–98

Levine D, Barnes PD (1999) Cortical maturation in normal and abnormal fetuses as assessed with prenatal MR imaging. Radiology 210:751–758

Levine D, Barnes PD, Madsen JR, Li W, Edelman RR (1997) Fetal central nervous system anomalies: MR imaging augments sonographic diagnosis. Radiology 204:635–642

Levine D, Barnes PD, Madsen JR, Abbott J, Mehta T, Edelman RR (1999) Central nervous system abnormalities assessed with prenatal magnetic resonance imaging. Obstet Gynecol 94: 1011–1019

Liu AE, Ardinger HH, Ardinger RH Jr, Cunniff C, Kelley RI (1997) Cardiovascular malformations in Smith-Lemli-Opitz syndrome. Am J Med Genet 68:270–278

Lubec G, Engidawork (2002) The brain in Down syndrome (trisomy 21). J Neurol 249:1347–1356

Lyon G, Arita F, Gallodec EL, Vallée L, Misson J, Ferrière G (1990) A disorder of axonal development, necrotizing myopathy, cardiomyopathy, and cataract: A new familial disease. Ann Neurol 27:193–199

Malcolm S (1996) Microdeletion and microduplication. Prenat Diagn 16:1213–1219

Mann DMA (1988) The pathological association between Down syndrome and Alzheimer's disease. Mech Aging Dev 43:99–136

Marín-Padilla M (1972) Structural abnormalities of the cerebral cortex in human chromosomal aberrations. A Golgi study. Brain Res 44:625–629

Marín-Padilla M (1976) Pyramidal cell abnormalities in the motor cortex of a child with Down's syndrome. A Golgi study. J Comp Neurol 167:63–82

Marion RW, Alvarez LA, Marans ZS, Lantos G, Chitayat D (1987) Computed tomography of the brain in the Smith-Lemli-Opitz syndrome. J Child Neurol 2:198–200

Marquardt T, Denecke J (2003) Congenital disorders of glycosylation: Review of their molecular bases, clinical presentations and specific therapies. Eur J Pediatr 162:359–379

McDonald JW, Althomsons SP, Hyrc KL, Choi DW, Goldberg MPC (1998) Oligodendrocytes from forebrain are highly vulnerable to AMPA/kainate receptor-mediated excitotoxicity. Nat Med 4:291–297

McKusick VA (1998) Mendelian Inheritance in Man. Catalogs of human genes and genetic disorders. 12th ed. Johns Hopkins University Press, Baltimore, MD

Miller OJ, Therman E (2001) Human Chromosomes, 4th ed. Springer, Berlin Heidelberg New York

Ming JE, Muenke M (2002) Multiple hits during early embryonic development: Digenic diseases and holoprosencephaly. Am J Hum Genet 71:1017–1032

Miyawaki T, Matsui K, Takashima S (1998) Developmental characteristics of vessel density in the human fetal and infant brains. Early Hum Dev 53:65–72

Moebius FF, Fitzky BU, Lee JN, Paik YK, Glossmann H (1998) Molecular cloning and expression of the human ¢7-sterol reductase. Proc Natl Acad Sci USA 95:1899–1902

Moerman P, Fryns J-P, Vandenberghe K, Lauweryns JM (1992) Constrictive amniotic bands, amniotic adhesions, and limb-body wall complex: Discrete disruption sequences with pathogenetic overlap. Am J Med Genet 42:470–479

Montteagudo A, Timor-Tritsch IE, Mayberry P (2000) Three-dimensional transvaginal neurosonography of the fetal brain: 'Navigating' in the volume scan. Ultrasound Obstet Gynecol 16:307–313

Moore KL, Persaud TVN (1998) The Developing Human, 6th ed. Saunders, Philadelphia, PA

Moore KL, Persaud TVN, Shiota K (2000) Color Atlas of Clinical Embryology, 2nd ed. Saunders, Philadelphia, PA

Moser AB, Rasmussen M, Naidu S, Watkins PA, McGuinness M, Hajra AK, Chen G, Raymond G, Liu A, Gordon D, et al. (1995) Phenotype of patients with peroxisomal disorders subdivided into 16 complementation groups. J Pediatr 127:13–22

Moser HW (1998) Neurometabolic disease. Curr Opin Neurol 11:91–95

Moser HW, Smith KD, Watkins PA, Powers J, Moser AB (2001) X-linked adrenoleukodystrophy. In: Scriver CR, Beaudet AL, Sly WS, Valle D (eds) The Metabolic & Molecular Bases of Inherited Disease, 8th ed. McGraw-Hill, New York, pp 3257–3302

Müller-Eckhardt C, Kiefel V, Grubert A, Kroll H, Weisheit M, Schmidt S, Müller-Eckhardt G, Santoso S (1989) 348 Cases of suspected neonatal alloimmune thrombocytopenia. Lancet 1989 (i):363–366

Narchi H, Kulayat N (1997) High incidence of Down's syndrome in infants of diabetic mothers. Arch Dis Childh 77:242–244

Nelson KB, Lynch JK (2004) Stroke in newborn infants. Lancet Neurol 3:150–158

Nelson MD, Gonzalez-Gomez I, Gilles FH (1991) The search for human telencephalic ventriculofugal arteries. Am J Neuroradiol 12:215–222

Nicolaides KH, Campbell S, Gabbe SG, Guidetti R (1986) Ultrasound screening for spina bifida: Cranial and cerebellar signs. Lancet (1986) ii):72–74

Nicolaides KH, Azar G, Byrne D, Mansur C, Marks K (1992) Fetal nuchal translucency: Ultrasound screening for chromosomal defects in first trimester of pregnancy. Br Med J 304:867–869

Nicolaides KH, Sebire NJ, Snijders RJM (1999) The 11-14 Week Scan: The diagnosis of fetal abnormalities. Parthenon, London

Norman MG (1980) Bilateral encephaloclastic lesions in a 26 weeks gestation fetus. Can J Neurol Sci 7:191–194

Norman MG, Becker LE (1974) Cerebral damage in neonates resulting from arteriovenous malformation of the vein of Galen. J Neurol Neurosurg Psychiatr 37:252–258

Norman MG, McGillivray BC, Kalousek DK, Hill A, Poskitt KJ (1995) Congenital Malformations of the Brain. Pathological, embryological, clinical, radiological and genetic aspects. Oxford University Press, New York

Nyberg DA, Mack LA, Hirsch J, Pagon RO, Shepard TH (1987) Fetal hydrocephalus: Sonographic detection and clinical significance of associated anomalies. Radiology 163:187–191

O'Donnell WT, Warren ST (2002) A decade of molecular studies of fragile X syndrome. Annu Rev Neurosci 25:315–338

OMIM: Online Mendelian Inheritance in Men. http://www.ncbi.nlm.nih.gov/omim

Opitz JM (1993) Blastogenesis and the "primary field" in human development. Birth Defects 29:3–37

Opitz JM, Wilson GN (1997) Causes and pathogenesis of birth defects. In: Gilbert-Barness E (ed) Potter's Pathology of the Fetus and Infant. Mosby, St. Louis, MI pp 44–64

Opitz JM, Zellweger H, Shannon WR, Ptacek LJ (1969) The RSH syndrome. Birth Defects Orig Artic Ser 5:43–52

Opitz JM, Wilson GN, Gilbert-Barness E (1997) Abnormalities of blastogenesis, organogenesis, and phenogenesis. In: Gilbert-Barness E (ed) Potter's Pathology of the Fetus and Infant. Mosby, St. Louis, MI, pp 65–105

Otake M, Yoshimura H, Schull WJ (1989) Prenatal exposure to atomic radiation and brain damage. Cong Anom 29:309–320

Otake M, Schull WJ, Yoshimura H (1991) Brain damage among the prenatally exposed. J Radiat Res Suppl 249–264

Pajkrt E, Mol BW, van Lith JM, Bleker OP, Bilardo CM (1998a) Screening for Down's syndrome by fetal nuchal translucency measurement in a high-risk population. Ultrasound Obstet Gynecol 12:156–162

Pajkrt E, van Lith JM, Mol BW, Bleker OP, Bilardo CM (1998b) Screening for Down's syndrome by fetal nuchal translucency measurement in a general obstetric population. Ultrasound Obstet Gynecol 12:163–169

Parrish M, Roessmann U, Levinsohn M (1979) Agenesis of the corpus callosum: A study of the frequency of associated malformations. Ann Neurol 6:349–352

Passarge E, Lenz W (1966) Syndrome of caudal regression in infants of diabetic mothers: Observations of further cases. Pediatrics 37:672–675

Patau K, Smith DW, Therman E, Inhorn SL, Wagner HP (1960) Multiple congenital anomaly caused by an extra autosome. Lancet 1960 (i):790–793

Pooh RK, Maeda K, Pooh KH (2003) An Atlas of Fetal Central Nervous System Disease. Diagnosis and management. Parthenon, London

Poutamo J, Vanninen R, Partanen K, Ryyanen M, Kirkinen P (1999) Magnetic resonance imaging supplements ultrasonographic imaging of the posterior fossa, pharynx and neck in malformed fetuses. Ultrasound Obstet Gynecol 13:327–324

Quintero RA, Romero R, Mahonev MJ, Vecchio M, Holden JH, Hobbins JC (1992) Fetal haemorrhagic lesions after chorionic villus sampling (letter). Lancet 1992 (i):193

Ramaswamy V, Miller SP, Barkovich AJ, Partridge JC, Ferreiro DM (2004) Perinatal stroke in term infants with neonatal encephalopathy. Neurology 62:2088–2091

Raybaud CA, Strother CM, Hald JK (1989) Aneurysms of the vein of Galen: Embryonic considerations and anatomical features relating to the pathogenesis of the malformation. Neuroradiology 31:109–128

Remes AM, Rantala H, Hiltunen JK, Leisti J, Ruokonen A (1992) Fumarase deficiency: Two siblings with enlarged cerebral vesicles and polyhydramnios in utero. Pediatrics 89:730–734

Robinson BH (2001) Lactic acidemia: Disorders of pyruvate carboxylase and pyruvate dehydrogenase. In: Scriver CR, Beaudet AL, Sly WS, Valle D (eds) The Metabolic & Molecular Bases of Inherited Disease, 8th ed. McGraw-Hill, New York, pp 2275–2295

Rorke LB (1992) Anatomical features of the developing brain implicated in pathogenesis of hypoxic-ischemic injury. Brain Pathol 2:211–221

Ruggieri PM (1997) Metabolic and neurodegenerative disorders and disorders with abnormal myelination. In: Ball WS (ed) Pediatric Neuroradiology. Lippincott, Philadelphia, PA, pp 175–237

Ryan AK, Bartlett K, Clayton P, Eaton S, Mills L, Donnai D, Winter RM, Burn J (1998) Smith-Lemli-Opitz syndrome: A variable clinical and biochemical phenotype. J Med Genet 35:558–562

Sarnat HB (2000) Molecular genetic classification of central nervous system malformations. J Child Neurol 15:675–687

Sarnat HB, Flores-Sarnat L (2004) Integrative classification of morphology and molecular genetics in central nervous system malformations. Am J Med Genet 126A:386–392

Schouten JP, McElgunn CJ, Waaijer R, Zwijnenburg D, Diepvens F, Pals G (2002) Relative quantification of 40 nucleic acid sequences by multiplex ligation-dependent probe amplification. Nucleic Acids Res 30:e57

Schull WJ, Nishitani H, Hasuo K, Kobayashi T, Goto I, Otake M (1992) Brain abnormalities among the mentally retarded prenatally exposed atomic bomb survivors. Radiation Effects Research Foundation, Technical Report Series 13-91:1–16

Scott BS, Becker LE, Petit TL (1983) Neurobiology of Down's syndrome. Prog Neurobiol 21:199–237

Scriver CR, Kaufman S (2001) Hyperphenylalaninemia: Phenylalanine hydroxylase deficiency. In: Scriver CR, Beaudet AL, Sly WS, Valle D (eds) The Metabolic & Molecular Bases of Inherited Disease, 8th ed. McGraw-Hill, New York, pp 1667–1723

Scriver CR, Beaudet AL, Sly WS, Valle D, eds (2001) The Metabolic & Molecular Bases of Inherited Disease, 8th ed. McGraw-Hill, New York

Shepard TH (1998) Catalog of Teratogenic Agents, 9th ed. Johns Hopkins University Press, Baltimore, MD

Shiota K (1991) Development and intrauterine fate of normal and abnormal human conceptuses. Cong Anom 31:67–80

Shiota K (1993) Teratothanasia: Prenatal loss of abnormal conceptuses and the prevalence of various malformations during human gestation. Birth Defects 29:189–199

Sie LTL, van der Knaap MS, van Wezel-Meijler G, Valk J (1997) MRI assessment of myelination of motor and sensory pathways in the brain of preterm and term-born infants. Neuropediatrics 28:97–105

Sismani C, Armour JA, Flint J, Girgalli C, Regan R, Patsalis PC (2001) Screening for subtelomeric chromosome abnormalities in children with idiopathic mental retardation using multiprobe telomeric FISH and the new MAPH telomeric assay. Eur J Hum Genet 9:527–532

Smeitink J, van den Heuvel L (1999) Human mitochondrial complex in health and disease. Am J Hum Genet 64:1505–1510

Smith DW, Lemli L, Opitz JM (1964) A newly recognized syndrome of multiple congenital anomalies. J Pediatr 64:210–217

Smith NM (2001) The reticuloendothelial system. In: Keeling JW (ed) Fetal and Neonatal Pathology, 3rd ed. Springer, Berlin Heidelberg New York, pp 593–604

Snijders RJM, Nicolaides KH (1996) Ultrasound Markers for Fetal Chromosomal Defects. Parthenon, London

Spranger J, Benirschke K, Hall JG, Lenz W, Lowry RB, Opitz JM, Pinsky L, Schwarzacher HG, Smith DW (1982) Errors of morphogenesis: Concepts and terms. J Pediatr 100:160–165

Squier W (2002) Pathology of fetal and neonatal brain damage: Identifying the timing. In: Squier W (ed) Acquired Damage to the Developing Brain: Timing and causation. Arnold, London, pp 110–127

Squier W, Chamberlain P, Zaiwalla Z, Anslow P, Oxbury J, Gould S, McShane MA (2000) Five cases of brain injury following amniocentesis in midterm pregnancy. Dev Med Child Neurol 42:554–560

Strachan T, Read AP (2004) Human Molecular Genetics, 3rd ed. Garland Science, London

Stray-Pedersen B (1993) Toxoplasmosis in pregnancy. Baillières Clin Obst Gynaecol 7:107–137

Streeter GL (1930) Focal deficiencies in fetal tissues and their relation to intrauterine amputations. Contrib Embryol Carnegie Instn 22:1–46

Sunderland S, ed (1993) TORCH Screening Reassessed. Blackmore, Shaftesbury

Sutton LN, Sun P, Adzick NS (2001) Fetal neurosurgery. Neurosurgery 48:124–144

Takanashi J, Barkovich AJ, Ferreiro DM, Suzuki H, Kohno Y (2003) Widening spectrum of congenital hemiplegia: Periventricular venous infarction in term neonates. Neurology 61:531–533

Toda T, Kobayashi K, Takeda S, Sasaki J, Kurahashi H, Kano H, Tachikawa M, Nagay Y, Taniguchi K, Sunada Y, et al. (2003) Fukuyama-type congenital muscular dystrophy (FCMD) and α-dystroglycanopathy. Cong Anom 43:97–104

Tominaga I, Kaihou M, Kimura T, Onaya M, Kashima H, Kato Y, Tamagawa K (1996) Infection foetale par le cytomégalovirus. Porencéphalie avec polymicrogyrie chez un garçon de 15 ans. Rev Neurol (Paris) 152:479–482

Torpin R (1965) Amniochorionic mesoblastic fibrous strings and amniotic bands. Am J Obstet Gynecol 91:65–75

Trauner DA, Chase C, Walker P, Wulfeck B (1993) Neurologic profiles of infants and children after perinatal stroke. Pediatr Neurol 9:383–386

UNSCEAR (1986) Genetic and Somatic Effects of Ionizing Radiation. Report of United Nations Scientific Committee on Effects of Atomic Radiation to the General Assembly. United Nations, New York

Van Allen MI, Curry C, Gallagher L (1987a) Limb body wall complex. I. Pathogenesis. Am J Med Genet 28:529–548

Van Allen MI, Curry C, Walden CE, Gallagher L, Patten RM (1987b) Limb body wall complex. II. Limb and spine defects. Am J Med Genet 28:549–565

van den Hof MC, Nicolaides KH, Campbell J, Campbell S (1990) Evaluation of the lemon and banana signs in one hundred and thirty fetuses with open spina bifida. Am J Obstet Gynecol 162:322–327

van der Knaap MS, Valk J (1990) MR imaging of the various stages of normal myelination during the first year of life. Neuroradiology 31:459–470

van der Knaap MS, Valk J (1995) Myelination and retarded myelination. In: van der Knaap MS, Valk J (eds) Magnetic Resonance of Myelin, Myelination and Myelin Disorders, 2nd ed. Springer, Berlin Heidelberg New York, pp 31–52

van der Knaap MS, Barth PG, Gabreëls FJM, Franzoni E, Begeer JH, Stroink H, Rotteveel JJ, Valk J (1997) A new leukoencephalopathy with vanishing white matter. Neurology 48:845–855

van der Knaap MS, Leegwater PAJ, Könst AAM, Visser A, Naidu S, Oudejans CBM, Schutgens RBH, Pronk JC (2002) Mutations in each of the five subunits of translation initiation factor eIF2B can cause leukoencephalopathy with vanishing white matter. Ann Neurol 51:264–270

van der Knaap MS, van der Voorn P, Barkhof F, Van Coster R, Krägeloh-Mann I, Feigenbaum A, Blaser S, Vles JSH, Rieckmann P, Pouwels PJW (2003) A new leukodystrophy with brainstem and spinal cord involvement and high lactate. Ann Neurol 53:252–258

van Zalen-Sprock RM, van Vugt JMG, van Geijn HP (1995) First and early second trimester diagnosis of anomalies of the central nervous system. J Ultrasound Med 14:603–610

Vissers LE, de Vries BB, Osoegawa K, Janssen IM, Feuth T, Choy CO, Straatman H, van der Vliet W, Huys EH, van Rijk A, et al. (2003) Array-based comparative genomic hybridization for the genomewide detection of submicroscopic chromosomal abnormalities. Am J Hum Genet 73:1261–1270

Volpe JJ (2001a) Neurology of the Newborn, 4th ed. Saunders, Philadelphia, PA

Volpe JJ (2001b) Neurobiology of periventricular leukomalacia in the premature infant. Pediatr Res 50:553–562

Wagenvoort AM, Bekker MN, Go AT, Vandenbussche FP, van Buchem MA, Valk J, van Vugt JM (2000) Ultrafast scan magnetic resonance in prenatal diagnosis. Fetal Diagn 15:364–372

Wanders RJA, Barth PG, Heymans HSA (2001) Single peroxisomal enzyme deficiencies. In: Scriver CR, Beaudet AL, Sly WS, Valle D (eds) The Metabolic & Molecular Bases of Inherited Disease, 8th ed. McGraw-Hill, New York, pp 3219–3256

Warburton D, Byrne J, Canki N (1991) Chromosome Anomalities and Prenatal Development: An atlas. Oxford University Press, Oxford

Warkany J (1971) Congenital Malformations. Year Book, Chicago, IL

Warren ST, Sherman SL (2001) The fragile X syndrome. In: Scriver CR, Beaudet AL, Sly WS, Valle D (eds) The Metabolic & Molecular Basis of Inherited Disease, 8th ed. McGraw-Hill, New York, pp 1257–1289

Wassif CA, Maslen C, Kachilele-Linjewile S, Lin D, Linck LM, Connor WE, Steiner RD, Porter FD (1998) Mutations in the human sterol delta7-reductase gene at 11q12-13 cause Smith-Lemli-Opitz syndrome. Am J Hum Genet 63:55–62

Waterham HR, Wijburg FA, Hennekam RCM, Vreken P, Poll-The BT, Dorland L, Duran M, Jira PE, Smeitink JAM, Wevers RA, Wanders RJA (1998) Smith-Lemli-Opitz syndrome is caused by mutations in the 7-dehydrocholesterol reductase gene. Am J Hum Genet 63:329–338

Waterham HR, Koster J, Romeijn GJ, Hennekam RCM, Vreken P, Andersson HC, FitzPatrick DR, Kelley RI, Wanders RJA (2001) Mutations in the 3-β-hydroxysterol Δ^{24}-reductase gene cause desmosterolosis, an autosomal recessive disorder of cholesterol biosynthesis. Am J Hum Genet 69:685–694

Weindling M (2002) Clinical aspects of brain injury in the preterm infant. In: Lagercrantz H, Hanson M, Evrard P, Rodeck CH (eds) The Newborn Brain – Neuroscience and clinical applications. Cambridge University Press, Cambridge, pp 443–478

Weis S, Weber G, Neuhold A, Rett A (1991) Down syndrome: MR quantification of brain structures and comparison with normal control subjects. AJNR Am J Neuroradiol 12:1207–1211

Wilkins-Haug L, Freedman W (1991) Progression of exencephaly to anencephaly in the human fetus – an ultrasound perspective. Prenat Diagn 11:227–233

Williamson DA (1970) A syndrome of congenital malformations possibly due to maternal diabetes. Dev Med Child Neurol 12:145–152

Yoshida A, Kobayashi K, Manya H, Taniguchi K, Kano H, Mizuno M, Inazu T, Mitsuhashi H, Takahashi S, Takeuchi M, et al. (2001) Muscular dystrophy and neuronal migration disorders caused by mutations in a glycosyltransferase, POMGnT1. Dev Cell 1:717–724

Youssoufian H, Pyeritz RE (2002) Mechanisms and consequences of somatic mosaicism in humans. Nat Rev Genet 3:748–758

Zanders EH, Buist FC, van Vugt JM (2003) Prenatal diagnosis of fetal intracranial hemorrhage at 25 weeks of gestation. Fetal Diagn Ther 18:327–337

Zellweger H (1987) The cerebro-hepato-renal (Zellweger) syndrome and other peroxisomal disorders. Dev Med Child Neurol 29:821–829

Zeviani M, Tiranti V, Piantadosi C (1998) Mitochondrial disorders. Medicine 77:59–72