7
Thin Basement Membranes and Alport's Syndrome

Agnes B. Fogo

Introduction/Clinical Setting

Classical Alport's syndrome is an X-linked disease and is the most common form of Alport's syndrome (90% of patients), with an overall incidence of Alport's syndrome in the United States of 1:5000 to 1:10,000 (1–4). Patients show hematuria in childhood with progressive hearing loss in one third, and ocular defects and progression to renal failure in 30% to 40% by early adulthood. Anterior lenticonus is the most common eye defect.

Alport syndrome is due to mutations of collagen type IV (3–6). Collagen type IV is made up of heterotrimers of alpha chains. These six alpha chains are encoded by genes arranged in pairs on three different chromosomes: *COL4A1* and *COL4A2* are on chromosome 13; *COL4A3* and *COL4A4* are on chromosome 2; and *COL4A5* and *COL4A6* are on the X chromosome. The mutation in the classic form of Alport's occurs in the α5 (IV) collagen chain (*COL4A5*). The autosomal recessive form accounts for most of the remaining patients, and is due to mutations in both alleles of α3 or α4 type IV collagen genes (*COL4A3* or *COL4A4*). Rare cases of autosomal dominant Alport's due to heterozygous mutations in *COL4A3* or *COL4A4* also occur, with a highly variable clinical course and reduced penetrance (7). Alport's syndrome and coexisting diffuse leiomyomatosis is linked to large gene deletions that span the adjacent 5′ ends of the adjacent *COL4A5* and *COL4A6* genes (5).

Pathologic Findings

Light Microscopy

There are no significant light microscopic abnormalities early in the disease (1). At later stages, glomerulosclerosis, interstitial fibrosis, and prominent interstitial foam cells, nonspecific and just indicative of proteinuria, are typical. Glomeruli show varying stages of matrix expansion and sclerosis.

Immunofluorescence Microscopy

Standard immunofluorescence (IF) may show nonspecific trapping of immunoglobulin M (IgM) in the mesangium. Special IF studies for subtypes of type IV collagen on either skin or renal biopsy may be helpful in distinguishing between causes of thin glomerular basement membrane (GBM), which may be the only lesion in early Alport, the carrier state for Alport, or so-called benign familial hematuria (see below) (3,5,8–11).

In kidney biopsies, about 70% to 80% of males with X-linked Alport's lack staining of the GBM, distal tubular basement membrane, and Bowman's capsule for α3, α4, or α5 (IV) chains, and Bowman's capsule and distal tubular basement membrane (TBM) also show lack of α6 (IV) (3,10,11). In autosomal recessive Alport's, where α3 or α4 is mutated, the kidney GBMs usually show no expression of α3, α4, or α5, again because there is an inability to form the normal α3, α4, or α5 type IV collagen heterotrimer of the GBM. In these autosomal recessive cases, in contrast to X-linked cases, α5 and α6 remain strongly expressed in Bowman's capsule, distal tubular basement membrane, and skin, because the $\alpha(1)_2 2/(5)_2 6$ heterotrimers can still be assembled in these patients. Female heterozygotes for X-linked Alport's syndrome frequently show mosaic staining of GBM and distal TBM for α3, α4, and α5 (IV) chains, and skin mosaic staining for α5 (IV). Patients with autosomal dominant Alport's have not been studied immunohistochemically.

Of note, some cases with Alport's syndrome clinically and by renal biopsy showed apparent normal α5 type IV immunostaining pattern. About 20% of male classic Alport patients and affected homozygous autosomal recessive Alport patients show faint or even normal staining of the skin or GBM for α3 and α5 (3). This is postulated to reflect a mutation that results in protein, that albeit abnormal, still expresses the epitope recognized by the available antibodies. Thus, the absence of α5 type IV in the skin biopsy is helpful in indicating a basement membrane abnormality, but an apparent normal staining pattern in either skin or kidney does not definitively rule out Alport's syndrome (10,11). The possible continuum of Alport's syndrome with some cases of apparent benign familial hematuria with thin basement membranes further complicates interpretation of staining patterns (see below).

Electron Microscopy

The diagnostic lesion consists of irregular thinned and thickened areas of the GBM with splitting and irregular multilaminated appearance of the lamina densa, so-called basket weaving (Fig. 7.1) (2). In between these lamina, granular, mottled material is present. In children with classic Alport's, the GBM may show only thinning rather than thickening. Female carriers of the *COL4A5* mutation also show only thin basement mem-

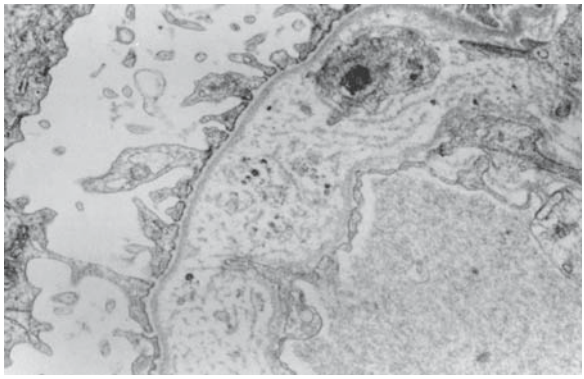

FIGURE 7.1. The glomerular basement membrane (GBM) is thickened with "basket-weaving" appearance, diagnostic of Alport's syndrome (electron microscopy).

branes, as do carriers of the autosomal recessive form of Alport's. The GBM thickness normally increases with age (12–14). Normal thickness in adults in one series was 373 ± 42 nm in men versus 326 ± 45 nm in women. Glomerular basement thickness <250 nm has been used as a cutoff for diagnosis in many series. In children, the diagnosis of thin basement membranes must be made with caution, establishing normal age-matched controls within each laboratory. In our laboratory, we found a range of GBM thickness in normal children from approximately 110 nm at age 1 year to 222 ± 14 nm in 7-year-olds.

Etiology/Pathogenesis

Alport's syndrome results from the inability to form normal type IV collagen heterotrimers. When α5 (or α3 or α4) is mutated, there is an inability to form the normal heterotrimers of the GBM. The organs involved in Alport's syndrome reflect sites where these type IV collagen chains are normally expressed and are essential for function, namely the kidney, eye, and ear. In the kidney, heterotrimers of α3, α4, and α5 type IV collagen are expressed in the GBM, whereas $\alpha(1)_2 2/(5)_2 6$ heterotrimers are expressed in Bowman's capsule and in some tubular basement membranes (5). At birth, $\alpha(1)_2 2$ heterotrimers are normally present in the immature glomerulus in the GBM, with gradual shift to the mature expression pattern. In the normal adult $\alpha(1)_2 2$ remains expressed in the mesangium and also in Bowman's capsule. The switch to normal adult α3, α4, α5 heterotrimers in the GBM cannot occur in Alport due to mutation in one of these chains. The mechanism(s) of progressive renal scarring in Alport's syndrome are unknown. In a report of seven patients with Alport's

syndrome, decreased proteinuria occurred in response to angiotensin-converting enzyme inhibitor (ACEI), and, after an initial decrease of the glomerular filtration rate (GFR), renal function increased toward the starting levels by 24 months (15).

Each Alport kindred reported thus far has presented its own unique mutation. More than 300 mutations in the *COL4A5* gene have been identified (4). The rate of progression to end stage and deafness in hemizygous affected males are mutation dependent. Large deletions, nonsense mutations, or mutations that changed the reading frame were associated with 90% risk of end-stage renal disease before age 30 in affected males with X-linked Alport's, with only 50% risk for patients with missense and 70% risk for those with splice site mutations. Risk for hearing loss before age 30 was 60% in patients with missense mutations, versus 90% risk for all other mutations (16). Ultrastructural features do not strictly correlate with type of mutation, in that some patients with major gene rearrangements had no significant lesions, and varying ultrastructural abnormalities were present even within the same kindred (2).

Transplantation in patients with Alport's syndrome has shed additional light on the molecular basis for this disease. Some patients with Alport's receiving kidney transplants, probably around 5% to 10%, develop antibodies to the normal GBM in the transplant. Occurrence of this posttransplant anti-GBM disease appears more frequent in patients with more extensive deletion of the α5 type IV gene (5).

Thin Basement Membranes

Introduction/Clinical Setting

This basement membrane abnormality has also been described as "benign familial hematuria," and shows autosomal dominant or recessive inheritance (12–14). The clinical manifestation is that of chronic hematuria, either macroscopic or microscopic, intermittent or continuous. This lesion is common, and is present in 20% to 25% of patients biopsied for persistent isolated hematuria in some series, and may occur in more than 1% of the general population (17). The lesion may also coexist with other glomerular disease, commonly diabetic nephropathy or IgA nephropathy (18,19). Occasionally patients with thin basement membranes have nephrotic range proteinuria, with five of eight such cases in one series showing additional focal segmental glomerulosclerosis (FSGS) lesions (20).

Pathologic Findings

Light Microscopy

The light microscopic appearance is unremarkable.

Immunofluorescence Microscopy

Standard IF is negative. Special IF studies for type IV collagen molecules (see above) may identify some of the patients with thin basement membrane lesions as carriers or early-stage Alport (21).

Electron Microscopy

Diffuse, greater than 50%, thinning of GBM indicates possible thin basement membrane lesion, while small segmental areas of thinning are nonspecific (Fig. 7.2). The diagnosis of thin basement membranes is based on morphometric measurements from electron microscopic examination (see above). As mentioned above, thin basement membranes (without lamellation) may also be an early or only manifestation in some kindreds with Alport's syndrome. Thus, the presence of thin basement membranes cannot per se be taken to categorically indicate a benign prognosis.

Etiology/Pathogenesis

Numerous studies indicate that autosomal recessive Alport's syndrome and benign familial hematuria/thin basement membrane disease may represent a spectrum of severe to mild or carrier forms, respectively, of varying molecular defects in the same genes. Linkage of hematuria to mutations in either α4 type IV or α3 type IV has been documented in about 40% of kindreds with apparent thin basement membrane nephropathy clinically (17,21–23). In remaining kindreds without apparent linkage, de novo mutations or incomplete penetrance of the hematuria phenotype is proposed to occur. In one study of patients with thin basement membranes, there was

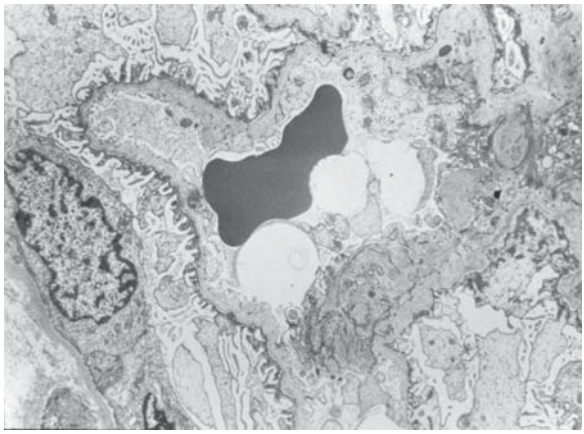

FIGURE 7.2. The GBM is diffusely thin in this adult with hematuria. Family history and immunostaining were consistent with thin basement membrane lesion of benign familial hematuria (electron microscopy).

increased global sclerosis, with later development of hypertension and renal insufficiency in the patients, and also in some relatives (24). However, these patients were not defined molecularly, and were presumed to not have Alport's syndrome based on absence of hearing or eye abnormalities.

References

1. Churg J, Sherman RL. Pathologic characteristics of hereditary nephritis. Arch Pathol 95:374, 1973.
2. Mazzucco G, Barsotti P, Muda AO, et al. Ultrastructural and immunohistochemical findings in Alport's syndrome: a study of 208 patients from 97 Italian families with particular emphasis on COL4A5 gene mutation correlations. J Am Soc Nephrol 9:1023–1031, 1998.
3. Pirson Y. Making the diagnosis of Alport's syndrome. Kidney Int 56:760–775, 1999.
4. Kashtan CE. Familial hematuria due to type IV collagen mutations: Alport syndrome and thin basement membrane nephropathy. Curr Opin Pediatr 16:177–181, 2004.
5. Hudson BG, Kalluri R, Tryggvason K. Pathology of glomerular basement membrane nephropathy. Curr Opin Nephrol Hypertens 3:334–339, 1994.
6. Longo I, Porcedda P, Mari F, et al. COL4A3/COL4A4 mutations: from familial hematuria to autosomal-dominant or recessive Alport syndrome. Kidney Int 61:1947–1956, 2002.
7. Pescucci C, Mari F, Longo I, et al. Autosomal-dominant Alport syndrome: natural history of a disease due to COL4A3 or COL4A4 gene. Kidney Int 65:1598–1603, 2004.
8. Nakanishi K, Yoshikawa N, Iijima K, et al. Immunohistochemical study of alpha 1–5 chains of type IV collagen in hereditary nephritis. Kidney Int 46:1413–1421, 1994.
9. Yoshioka K, Hino S, Takemura T, et al. Type IV collagen α5 chain. Normal distribution and abnormalities in X-linked Alport syndrome revealed by monoclonal antibody. Am J Pathol 144:986–996, 1994.
10. Kashtan CE. Alport syndrome: is diagnosis only skin-deep? Kidney Int 55:1575–1576, 1999.
11. Kashtan CE. Alport syndromes: phenotypic heterogeneity of progressive hereditary nephritis. Pediatr Nephrol 14:502–512, 2000.
12. Yoshiokawa N, Matsuyama S, Iijima K, Maehara K, Okada S, Matsuo T. Benign familial hematuria. Arch Pathol Lab Med 112:794–797, 1988.
13. Tiebosch ATMG, Frederik PM, van Breda Vriesman PJC, et al. Thin-basement-membrane nephropathy in adults with persistent hematuria. N Engl J Med 320:14–18, 1989.
14. Hisano S, Kwano M, Hatae K, et al. Asymptomatic isolated microhaematuria: natural history of 136 children. Pediatr Nephrol 5:578–581, 1991.
15. Proesmans W, Knockaert H, Trouet D. Enalapril in paediatric patients with Alport syndrome: 2 years' experience. Eur J Pediatr 159:430–433, 2000.
16. Jais JP, Knebelmann B, Giatras I, et al. X-linked Alport syndrome: natural history in 195 families and genotype-phenotype correlations in males. J Am Soc Nephrol 11:649–657, 2000.

17. Savige J, Rana K, Tonna S, Buzza M, Dagher H, Wang YY. Thin basement membrane nephropathy. Kidney Int 64:1169–1178, 2003.
18. Matsumae T, Fukusaki M, Sakata N, Takebayashi S, Naito S. Thin glomerular basement membrane in diabetic patients with urinary abnormalities. Clin Nephrol 42:221–226, 1994.
19. Cosio FG, Falkenhain ME, Sedmak DD. Association of thin glomerular basement membrane with other glomerulopathies. Kidney Int 46:471–474, 1994.
20. Nogueira M, Cartwright J Jr, Horn K, et al. Thin basement membrane disease with heavy proteinuria or nephrotic syndrome at presentation. Am J Kidney Dis 35:E15, 2000.
21. Liapis H, Gokden N, Hmiel P, Miner JH. Histopathology, ultrastructure, and clinical phenotypes in thin glomerular basement membrane disease variants. Hum Pathol 33:836–845, 2002.
22. Lemmink HH, Nillesen WN, Mochizuki T, et al. Benign familial hematuria due to mutation of the type IV collagen α4 gene. J Clin Invest 98:1114–1118, 1996.
23. Buzza M, Wang YY, Dagher H, et al. COL4A4 mutation in thin basement membrane disease previously described in Alport syndrome. Kidney Int 60:480–483, 2001.
24. Nieuwhof CMG, de Heer F, de Leeuw P, van Breda Vriesman PJC. Thin GBM nephropathy: premature glomerular obsolescence is associated with hypertension and late onset renal failure. Kidney Int 51:1596–1601, 1997.