3

Death in a Head-Down Position

Achim Th. Schäfer, MD

CONTENTS

INTRODUCTION
TEN CASE REPORTS
DISCUSSION
PATHOPHYSIOLOGICAL CONSIDERATIONS
CONCLUSION
REFERENCES

SUMMARY

Although deaths of persons in a head-down position are rare events, there can be no doubt that they occur from time to time, most often accidentally. The prolonged head-down position itself may lead to fatal outcome. The common features of such cases are as follows: *(a)* the finding of a body in an inverted or head-down tilted position; *(b)* marked ("monstrous") congestion of face, scalp, neck, and other dependent parts of the body (e.g., hands, shoulders); *(c)* accompanying effects of internal congestion with swelling of and petechial bleedings at the affected parts as well as edema of the brain and lungs; and *(d)* lack of a definite pathoanatomical cause of death. In some cases, one may find traces of self-rescuing attempts on the deceased's body as well. Because postmortem examinations are unlikely to reveal the cause of death in such cases, additional pathophysiological considerations are required to make this determination. This chapter examines 10 cases in which the deceased was found in a head-down position. Based on these cases, it is observed that eld-

From: *Forensic Pathology Reviews, Vol. 3*
Edited by: M. Tsokos © Humana Press Inc., Totowa, NJ

erly people, and in particular elderly with preexisting cardiovascular diseases, seem to be more prone to death in a head-down position than others. This suggests that final heart failure is the cause of death rather than cerebral or pulmonary dysfunction. Results from human and animal experiments and observations under true and simulated microgravitational conditions confirm this assumption, suggesting that a prolonged, markedly elevated burden of work for the heart because of increased volume load in an inverted body position eventually leads to death by heart failure. Other mechanisms, such as suffocation ("positional asphyxia"), reduced blood reflux to the heart attributable to vanishing of blood in the venous system, decreased oxygen supply to the brain after reduced arteriovenous pressure difference, and carotid sinus or baroreceptor reflexes as well as other factors seem to play only a minor role, if any, in deaths in head-down position.

Key Words: Head-down position; positional asphyxia; inverted suspension; cardiovascular dysfunction; heart failure; blood distribution; congestion.

1. Introduction

In August 1997, in an amusement park in Belgium, a roller coaster failed, and a group of visitors was trapped in the wagon in a head-down position for 90 minutes before rescue could be achieved. It appears that none of the victims suffered harm resulting from this accident, indicating that human beings can survive at least 1.5 hours in such an uncomfortable position.

There are, nevertheless, some rare reports of fatalities from an inverted body position. Most of these reports describe cases in which the deceased were accidentally trapped by their feet and left to hang, head-down, for a prolonged period of time before being found dead. Normally, postmortem examination reveals no obvious pathoanatomical cause of death in such cases, aside from signs of severe congestion in the region of the head and upper torso. Such observations prove that an inverse body position may have a fatal outcome, particularly if endured for a considerable period of time.

Some authors ascribe the term "inverse (or reverse) suspension" to such deaths. The word "suspension," however, includes an element of "hanging" or "being fixed" in some way. Although this may be the most frequent underlying mechanism in such fatalities, other mechanisms have been observed as well. For example, one may fall head-down into a narrow, deep hole, get stuck there, and die. In other cases, the victims have been found lying on a kind of declined plane, for example, on a stairwell with their head facing down on the half-landing, rather than in an inverted vertical position. Because "suspension" is not a necessary condition for this kind of accident, this author prefers

as the more neutral expression "head-down (or inverted) position." Similarly, the expression "positional asphyxia" is sometimes used to describe the cause of death in such cases. By applying this term, it is suggested that "asphyxia" (suffocation) is the cause of death, which is, as evidenced from the review of the following 10 cases, most doubtful in the most cases. If real asphyxia is not obvious, for example, by compression of the thorax, this term should be avoided as well.

A number of pathophysiological considerations and even experimental approaches have been published to theoretically assess the cause of death in head-down position. Here, a survey of the results already known is provided, including some modern insights from space medicine, for example, the examination of physiology under microgravitational conditions.

2. *Ten Case Reports*

In the following, 10 well-documented case reports where the deceased was found in a head-down position are portrayed. Excluded from this review are certain cases from the earlier literature, which, although interesting, lack relevant information such as autopsy results; these are:

- The case of a 77-year-old man who was found dead hanging over a window sill, with his head and arms hanging down outside, after having called a doctor because of an asthma attack (case 356 in ref. *1*).
- The case of an elderly woman who was found hanging head-down on the outside house wall with her left foot caught between the window and its frame (Fig. 184 in ref. *2*).
- The case of a 73-year-old man who was hanging head-down, naked, with his feet fixed by ropes at the uppermost rung of a ladder (of what appeared to be a self-constructed "slaughtering bench"). He had a self-inscribed writing on his abdominal region: "Schlachtsau, Handelsklasse II" (pig for slaughtering, grade II) (case 13 in ref. *3*).

Some better documented cases are discussed here.

2.1. Case 1

The body of a middle-aged man was found on a staircase, with his legs and nearly his entire body laying lengthwise on the stair. His head was located at the lowest position on a half-landing. Because of acute alcohol intoxication (blood alcohol level [BAL] = 346 mg/dL), he must have lost his balance and fallen into this position, where he stayed for an undetermined period of time until he died. Autopsy revealed no signs of external violence and no definite

pathoanatomical cause of death. Marked congestion of the head and upper parts of the trunk, brain edema, and hemorrhagic edema of the upper parts of the lungs were the most striking findings (author's own case).

2.2. Case 2

An elderly man was at the pub one night. The next morning, he was found dead, sticking head-down in a narrow hole on the ground of a building site. He must have fallen into the hole at night on his way home from the pub. Unable to rescue himself, he died during the night and was found about 6 hours later. Postmortem examination showed no external injuries or any internal cause of death. A marked congestion of the head, edema of the brain, and hemorrhagic edema of the upper parts of the lungs were the most prominent findings. His BAL was 341 mg/dL (author's own case).

2.3. Case 3

A similar case is described by Yoshida et al. *(4)*, in which a 74-year-old man lived in a house where one room was filled with trash, the latter forming 1 to 1.8 m high "mountains." While climbing over this trash, the man fell head-over-heels into a hole and got stuck with his body nearly perpendicular to the floor. He was found dead between 20 to 48 hours later. Upon autopsy, the man had a pressure mark on the top of his head that was caused by a pan that was situated at the bottom of the hole. No other signs of external injuries and no definite pathoanatomical cause of death could be identified. The body showed severe congestion of the head and the upper part of the trunk, petechial hemorrhages in the oral and bronchial mucosae, brain edema, and congestion of cerebral vessels.

2.4. Case 4

Purdue *(5)* reported the case of a 48-year-old man who tried to climb over a 3-meter-high security fence to steal some goods from a warehouse yard. Approximately 2 hours after he was last seen alive, a yell for help was heard, but a police officer who investigated the area neither heard nor saw anything out of the ordinary. The man was found dead the next morning, hanging perpendicular to the ground by his right foot attached to the fence. His foot had been caught between two spikes of the fence and the body hung freely downward without any support. Some blood-stained liquid had issued from his mouth and nostrils. Upon autopsy, diverse superficial bruises and abrasions were found, but no signs of severe trauma or underlying internal diseases were identified. Soft tissues of neck and face showed marked swelling and congestion,

as did the lungs and brain. The gastric mucosa exhibited numerous tiny (stress) hemorrhages and the blood from mouth and nose derived from the stomach. BAL was 129 mg/dL.

2.5. Case 5

An 11-month-old baby was found dead one morning hanging from its crib with one foot caught between the crib's rods. The body was hanging freely, without head contact to the floor. Autopsy revealed congestion of the head, petechial hemorrhages in the soft tissues, and some atelectatic alveoli in the lungs (from ref. *6*).

2.6. Case 6

On the way home from the pub, a 67-year-old man fell over a thorn hedge that was separating the road from a ditch. He was caught there, hanging in a head-down position over the ditch. The man was stuck in this position by the thorns and was unable to rescue himself. He was found dead the next morning. Autopsy showed severe swelling and congestion of neck and head with marked edema of the conjunctivae, diverse non-lethal underlying diseases, and a BAL of 230 mg/dL (from ref. *6*).

2.7. Case 7

An 85-year-old woman was admitted to a hospital with vague abdominal pain. A barium enema was applied for diagnostic radiography and, after this, the woman was positioned in a 30° head-down position for better distribution of the medium, when she suffered sudden cardiac arrest. At autopsy, advanced general atherosclerosis was found with "calcified aortic stenosis with aortic insufficiency, hypertrophy and dilatation of left ventricle and insufficiency of the mitral valve." In addition, dilation of the atrium of the left heart and a pulmonary edema was noted. Left heart failure was determined as cause of death (from ref. *7*).

2.8. Case 8

After not having been seen for 2 days, a 56-year-old man was found dead hanging head-down, perpendicular to the floor in a sack. The sack itself was fixed by ropes to a rod that was extended over a door and a cupboard. Beside the sack, there were two chairs, one of them overturned. The man must have been standing on the chairs, preparing some autoerotic act with the sack pulled over his head and trunk. He must have lost balance and fallen head-over-heels into the sack, which then turned around, resulting in the head-down position.

Fig. 1. Case 9. **(A)** Death scene. The body of a 64-year-old man is hanging head-down from a railing that separates the yard of a house from a staircase leading down to the cellar. **(B)** Death scene. Closer view of the man's right knee jammed into a gap between the railing and the wall. Note waste bin, apparently used as a step stool, and the bleeding wound seen on the left calf. **(C)** Hemorrhagic congestion of conjunctiva and sclera. **(D)** Marked congestion of lips and bloody fluid seen in the oral cavity. (Courtesy of Dr. Wolfgang Huckenbeck, Düsseldorf, Germany.)

He held a pair of scissors in his hand, obviously prepared to rescue himself in case of an accident, but he had only managed to cut a small hole into the sack. Postmortem examination showed severe congestion of the skin of the head and arms and of the internal organs and structures of head, neck, and thorax. In addition to brain and lung edema, subcutaneous hemorrhages in the arms, microscopically accompanied by a polymorphonuclear leukocyte infiltration,

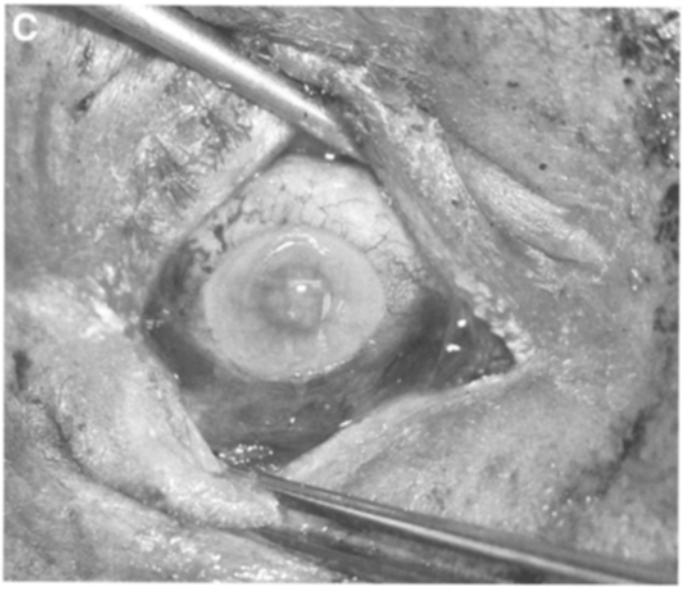

Fig. 1. *(Continued)*

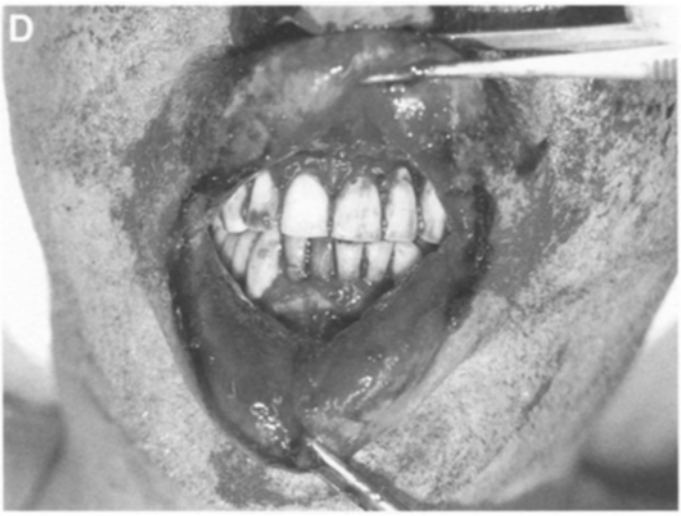

Fig. 1. *(Continued)*

were observed. A hypoxic vacuolization of liver cells was detected microscopically (from ref. 7).

Cases 9 and 10 represent the most recent cases.

2.9. Case 9

A 64-year-old man was found dead, hanging head-down from a railing that separated the yard of his house from the staircase leading down to the cellar (Fig. 1A). His right knee was jammed into the gap between the end of the staircase railing and the wall of the house (Fig. 1B). A fresh wound was found on his left calf. Next to the wall, nearly under the kitchen's window, stood a waste bin. It was concluded that the victim had forgotten his key when leaving the house and that he tried to enter the house through the window, using the dustbin as a step stool. Doing so, he lost balance and fell backward over the railing, accidentally jamming his knee into the gap between the end of the staircase railing and the wall of the house. The period of time that he had remained hanging in this position could not be estimated. Autopsy showed congestion of head (Fig. 1C), neck and arms, and also of the brain and upper parts of the lungs. The mucous membranes of the upper airways were severely congested, with some bloody fluid coming out of his mouth and nostrils (Fig. 1D). Further findings were superficial lacerations of the skin, numerous petechial hemorrhages of the gastric mucosa, fresh bleeding into the abdominal wall muscles, general atherosclerosis, biatrial dilatation of the heart, and fatty

degeneration of liver cells (ref. *8* and W. Huckenbeck, Düsseldorf, Germany, personal communication, 2004).

2.10. Case 10

A 77-year-old man was found dead in his home, laying completely naked in a supine position on his kitchen table, head and lower legs hanging down over the table's edges. He had last been seen alive 24 hours before. The man was known to be a chronic alcoholic, but an autopsy blood sample was found to be free of alcohol. Besides severe congestion of the dependent parts of the head accompanied by numerous, partly confluent, petechial skin bleedings (Fig. 2A,B) and brain edema, marked general atherosclerosis and narrowing of the coronary vessels due to sclerosis were found, as well as signs of older myocardial infarctions. No signs of external violence were detected at autopsy. A fresh myocardial infarction was ruled out by routine histological examination as well as immunohistochemistry. It remained unclear whether the man may have believed himself to be in bed, possibly following delirious disorientation. It was concluded that the cause of death most probably was cerebral hypoxia as a sequel of insufficient cerebral blood flow due to head-down position (M. Tsokos, Hamburg, Germany, personal communication, 2004).

3. Discussion

The most obvious observation derived from the case reports presented here is that men seem to be more prone to death in a head-down position than are women (of the 10 cases, 8 were males, 1 was a female, gender of the infant is unknown) and that in some cases high BALs constitute an additional relevant factor. This may be explained by different behavioral patterns of men and women. Women are generally more cautious; they are less likely to fall into holes (case 2) or over hedges (case 6) on their way home from pubs or drinking halls. They rarely climb over fences to steal goods (case 4). Women typically do not construct strange devices for autoerotic practices (case 8). Men, particularly after drinking, tend to be more daring and thus are more prone to accidents, including the rare case of being caught in a head-down position.

More striking is the observation that elderly people seem to have an increased risk of dying in a head-down position when compared with younger persons (at least six of the victims were older than 50, and among these were three persons who were older than 70 years [in two cases, the exact age remained unknown]); this could be owing to two different reasons. First, younger people are more agile and may be able to rescue themselves more easily if they acci-

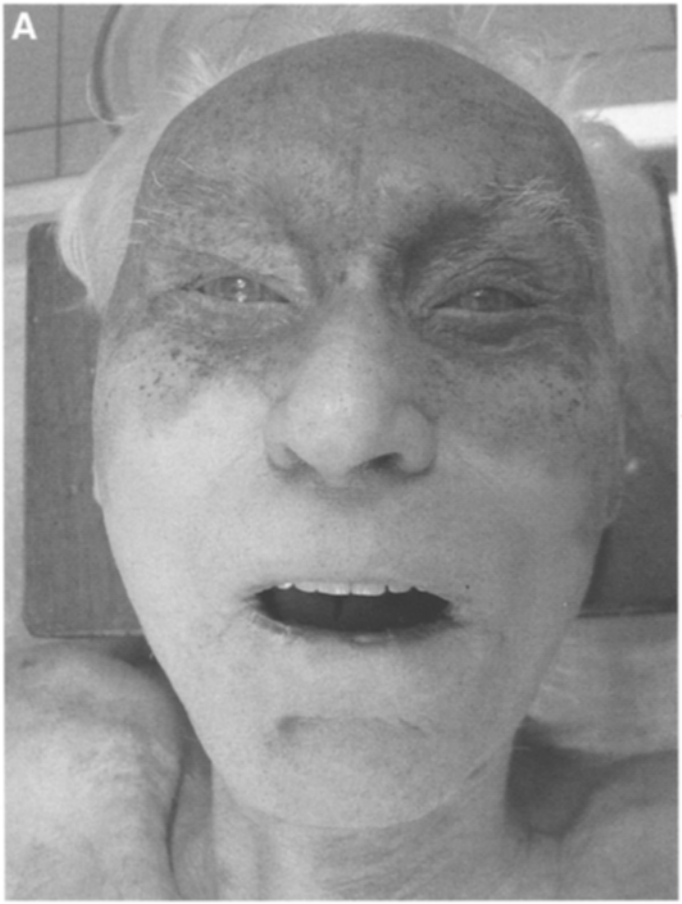

Fig. 2. Case 10. Autopsy features. **(A)** Enormous congestion of the dependent (upper) parts of the head due to the hanging down of this 77-year-old man's head over the edge of a table. **(B)** A sharp demarcation is seen between dependent and nondependent parts of the face. Note the numerous, partly confluent, petechial skin bleedings. (Courtesy of Dr. Michael Tsokos, Hamburg, Germany.)

dentally come into such a body position. Second, the cardiovascular system of elderly people is less resistant to unfamiliar stress and may fail earlier than that of younger persons. In other words, the elderly appear to die before they can be found and rescued, whereas younger persons may survive for a longer period of time and thus have a greater chance to be saved. However, case 5 (the infant) shows that head-down death is possible in any age group.

Fig. 2. *(Continued)*

Some of the cases reported here show that a strictly vertical body position is not necessarily needed to die in a head-down position. A declivity of 45° (estimated in case 1), 30° (case 7), or the isolated hanging down of the head may lead to death, particularly if, as demonstrated in cases 7 and 10, there is severe preexisting cardiovascular insufficiency. This observation suggests that the cardiovascular system may play a major role among the mechanisms of death in head-down position, an aspect that is further elaborated below.

All head-down victims exhibited some common, characteristic features among which are the severe congestion of head, neck and, depending on their posture, arms and upper part of the trunk is the most striking finding. Such congestion has been described by some authors as "hypostasis" or "livores," and it may well appear as such after death. But because this congestion already begins while the affected persons are still alive, it should not be confused with livores. The polymorphonuclear leukocyte infiltration of subcutaneous bleedings in the arms in case 8 could have developed only while the victim was still alive and thus indicates that the man must have survived the formation of the bruises for at least some time.

The grade of congestion in such cases is severe, sometimes even "monstrous," and leads to a bluish-violaceous discoloration of face, neck, and scalp, combined with marked swelling of the soft tissues, mucous membranes, and anatomical structures of the eyes. Additional phenomena after such congestion are petechial bleedings in skin, conjunctivae, and mucous membranes of

mouth and nose (sometimes presenting as confluent hemorrhages), brain edema, congestion of brain vessels, and pulmonary edema, particularly in the upper parts of the lungs, which also may appear hemorrhagic. If arms and shoulders constituting dependent body parts in a given case, the same phenomena may be observed in these body parts as well. Such congestion is easily understood to be a consequence of increased hydrostatic blood pressure in the affected body parts owing to the victim's inverse body position.

In some cases, petechial hemorrhages of the gastric mucosa were observed, too (cases 4 and 9). These may be interpreted as being induced by stress, as similar effects have been identified in victims of severe blunt trauma, infection, or burns. This indicates a prolonged phase of agony in head-down position. Whether histopathological changes of liver cells (hypoxic vacuolization as seen in case 8, fatty degeneration as found in case 9) belong to the postural effects in inverse position or represent preexisting pathological conditions remains unclear.

More typical are bruises, skin lacerations, wounds, and similar aftereffects of falling and self-rescue attempts. Such were the abrasions and bruises observed in case 4, diverse scratches found in case 8, and the wounds and lacerations detected in case 9. The latter case also is remarkable because of the bleeding into the victim's abdominal wall muscles, which probably was caused by the victim's attempts to reach some support with the hands. Broken fingernails and similar traces may be observed in such cases as well. Such findings indicate that the victims were not unconscious immediately after they came into the head-down position, but that they rather were conscious for a considerable period of time and were obviously aware of their situation. In other cases, however, no such traces can be found, be it due to alcohol intoxication (cases 1 and 2), to rapid death (case 7), or to loss of consciousness by unknown causes (case 10).

4. Pathophysiological Considerations

Definite pathoanatomical causes of death, such as myocardial infarction, pulmonary embolism, airway obstruction, and cerebral bleeding, normally are not observed in head-down deaths, although in some of the cases presented here severe cardiovascular diseases (cases 7 and 10) or alcohol intoxication (cases 1 and 2) may have contributed to fatal outcome. In other cases, the head-down position itself must have been the only determining factor of death. The question is, how can this abnormal body position lead to death and what are the underlying pathophysiological mechanisms?

Earlier animal experiments *(9)* with rabbits, dogs, frogs, and even snakes that have been fixed lengthwise on a board and then brought into different

body positions show that abnormal postures lead to a decrease of arterial blood pressure and to marked circulatory disturbances. More recent experiments by Uchigasaki et al. *(10)* revealed that 14 rabbits that were subjected to head-down position died after 26 *(17–44)* hours. Prior to death, a slight increase of respiratory frequency and a gradual decrease of amplitude of respiratory movements, of arterial oxygen saturation, and of blood pressure were observed. The authors interpret their observations as "resulting from hindered respiratory movements" and conclude therefore that "positional asphyxia" was the cause of death.

Besides the many problems of transferring results of animal experiments to humans, observations and experiments involving humans have revealed further possible mechanisms of death induced by the inverted body position. As early as 1968, Marshall *(6)* listed the three most likely mechanisms. In addition to real "positional asphyxia," Marshall noted *(a)* insufficient oxygen supply of the brain as a result of reduced cerebral blood flow, following diminished arteriovenous pressure difference (venous pressure is elevated by the additional hydrostatic pressure of blood in an inverted body position), and *(b)* cardiac insufficiency and eventual cardiac arrest resulting from increased blood flow to the heart and, therefore, increased volume load, and increased burden of work that cannot be tolerated by the victim for a prolonged period of time.

Is one of these the dominant cause of death in head-down cases?

Wilkins et al. *(11)* subjected 42 healthy volunteers to a short period of being positioned head-down. Besides general muscular tension and discomfort, the volunteers reported feelings of congestion of head and face, impediment of respiration, swelling of nasal mucosa and nasal mucous flow, ocular tearing, and sweating of the face and neck. Objectively, jugular venous pressure was increased and femoral arterial pressure diminished. Right atrial pressure, ventricular stroke volume, and cardiac output were increased (indicating increased burden of work for the heart). In another experiment, Deklunder et al. compared –70° head-down position to +70° head-up position (all angles measured from the horizontal) in 12 healthy male volunteers *(12)*. They observed in the head-down posture an increased passive filling of the left ventricle and increased cardiac output, increased arterial pressure, and tachycardia. These authors concluded that "in man, the cardiac responses to the changes in posture appear to be related more to the passive changes in ventricular filling due to the blood shift than to the nervous regulation by the arterial baroreflexes...."

Experiments with centrifuges may mimic a broad range of gravitational influences by extent and by direction, respectively. Such experiments simu-

lating head-down positions showed complex cardiovascular responses to this altered circulatory situation *(13,14)*. Both venous and arterial pressure in the head region increase, but the arteriovenous pressure difference decreases, resulting in an inadequate cerebral blood flow. The venous system reacts to the increased internal pressure with a reflex vasodilation whereas, in contrast, the arteries react by reflex vasoconstriction (the latter representing the so-called "Bayliss effect"). The intrathoracic pressure and the volume load of the heart are increased and so are the cardiac stroke and output volumes. Furthermore, such situations provoke dramatic carotid sinus reflexes; bradycardia and even asystole may occur. Thus, the cardiovascular reaction to a head-down position seems to be governed by a series of different, interacting reflexes and reactions, all of which are induced by an increased blood volume in the upper half of the body.

Experiments under microgravity conditions, be they real or simulated, provide further insight into the effect of altered blood distribution in the human body. Preliminary investigations have shown that a head-down tilt of –5° to –6° is equivalent to the microgravity conditions in space. Although more rare, water immersion is also used for simulating weightlessness *(15)*. Under such conditions, a redistribution of body fluids from the lower to the upper parts of the body and from blood vessels into the interstitial spaces, which can be observed as swelling of facial tissue and shrinking of soft tissues of lower limbs, is found *(16)*. Under simulated hypoxic conditions, this effect is even more pronounced *(17)*, but the healthy human seems to be able to adapt to such conditions *(18)*. For space missions, a trouser-like device has been developed that applies negative pressure to the lower body parts in order to reduce or prevent such fluid redistribution *(19)*.

Other effects are identified in conjunction with the shift of body fluids. The intraocular pressure rises *(20)* after only 20 seconds of microgravity exposure *(21)*. Diuresis is forced and humans under prolonged microgravity conditions loose body weight (7.7% in one case *[16]*), at least partially by water loss. This effect seems to be forced by an increase of serum atrial natriuretic peptide that could be observed in six subjects (*17*), indicating an elevated volume load to the heart which, just under such a condition, emits atrial natriuretic peptide. Other researchers, however, could not confirm the aforementioned findings *(22)*. Increase of serum dopamine, reduction of blood velocity in the middle cerebral artery, and changes to the arterial baroreflex control of heart rate, all with complex but limited influence on the cardiovascular function, have been observed as well *(23–26)*. The more subtle effects of microgravity conditions include reduced glucose tolerance *(27)* and difficulties of circadian rhythm adaptation *(28)*.

It is well known from long-term observations in space and from simulation experiments that the human organism may adapt to microgravity conditions and does not suffer severe health defects from them *(29)*. However, the pathophysiological changes as well as long-term effects induced by microgravity seem to be of minor interest for our reflection on the lethal mechanisms of the head-down position. Nevertheless, it should be mentioned that the first and most prominent effect of microgravity is a redistribution of body fluids from the lower to the upper parts of the body. A similar but far more substantial fluid shift to the head is caused by the head-down position. This fluid shift is therefore to be discussed as the leading lethal mechanism in such cases.

The observation that persons with cardiovascular diseases may die rapidly in a head-down position (case 7) and even under moderate head-down tilt (case 10) supports the opinion that disturbed cardiac function plays an important role as cause of death in inverted body positions. The increased blood flow to the heart and the increased volume load require considerable more work from the heart, which it, eventually, cannot withstand. This understanding of the cardiac role in such deaths is compatible with all experiments and observations mentioned above and helps to explain as well the fact that elderly people, whose hearts may be less resistant to unfamiliar stresses, seem to be more prone to death in head-down position than are younger persons.

It has been claimed that quite the contrary effect, namely a reduced blood reflux to the heart following a "vanishing" of blood in the veins of the head and upper torso (which do not support blood flow owing to the absence of a muscle pump), contributes to heart failure in a head-down position *(30)*. Such an assumption, however, does not fit the experimental results cited above that show an increase in passive filling of the heart and of atrial pressure in head-down position *(11,12)*. Whether slowing down of the heart beat rate following carotid sinus reflex to elevated hydrostatic pressure in the arterial system has an influence on lethal outcome remains unclear. As to this author's opinion, this effect cannot be too marked; otherwise, the victims could not survive some hours in an inverted body position.

Reduced oxygen supply to the brain as the result of reduced arteriovenous pressure difference and hindrance of respiration by the pressure of abdominal intestina on the lungs may play additional, but less important, roles. If the brain was insufficiently supplied with oxygen, rapid loss of consciousness should be expected, but marked traces of self-rescuing efforts in some of the cases presented previously in this chapter (cases 4, 8, and 9) show that this is not necessarily the case. Moreover, if the thorax and lungs, respectively, are

compressed over a considerable period of time, cries for help (as observed in case 4) would be impossible.

Thus, it appears that death in a head-down position is a death of gradual (occasionally sudden) heart failure and not a kind of cerebral death or death by suffocation ("asphyxia"). Of course, asphyxia should be discussed as an additionally factor influencing lethal outcome in cases where the victim is caught in very tight openings or similar structures that prevent proper breathing by thorax compression. However, asphyxia should not generally be assumed in all cases of head-down deaths. In one of the most recent contributions to the literature, Glatter and Karch (2004) correctly warn against the application of the term "positional asphyxia" to any otherwise unexplained death *(31)*.

5. Conclusion

Although head-down fatalities are rare events and are infrequently reported in the literature, some authors *(6,7)* mention that in the past inverted suspension was a common torture and death penalty method. St. Peter is said to have been crucified in a head-down position because he himself desired not to die in the same manner as Jesus (crucifixion in upright body position). Even until World War II, such torture was applied from time to time and probably still takes place in some countries nowadays. As the forensic examiner must, on occasion, examine victims of torture, it may be useful to remember the after-effects and objective traces, if any, of such a torture method. To this author's knowledge, detailed descriptions on this point are missing in literature.

Another point of uncertainty is the survival time after coming into an inverted body position. Reports in the earlier literature (cited in ref. *7*) claim that agony after head-down hanging may last many hours up to 1 day. The cases described in this chapter suggest a similar survival time, at least of some hours in most cases. Apparently, the survival time depends on the strength and endurance of the victim's cardiovascular system. The period of time needed after that sudden death of a person with preexisting severe cardiovascular disorders (as in case 7) has to be expected after this person has been tilted down remains entirely unclear.

References

1. Schwarz F (1970) Der außergewöhnliche Todesfall. Enke, Stuttgart.
2. Prokop O, Radam G (1987) Atlas der gerichtlichen Medizin. Karger, Basel.
3. Hilgermann R, Richter O (1973) Einige besondere Fälle aus dem rechtsmedizinischen Obduktionsgut. Beitr Gerichtl Med 30, 163–174.

4. Yoshida K, Harada K, Sorimachi Y, Makisumi T (1995) Death in head-down position: An autopsy report with reference to physiological mechanism. Jpn J Legal Med 49, 33–36.
5. Purdue B (1992) An unusual accidental death from reverse suspension. Am J Forensic Med Pathol 13, 108–111.
6. Marshall TK (1968) Inverted suspension. Med Sci Law 8, 49–50.
7. Madea B (1993) Death in a head-down position. Forensic Sci Int 61, 119–132.
8. Thiel I, Huckenbeck W (2003) Der kalte Tod an der Treppe. SeroNews 8, 32–34.
9. Kauffmann F (1927) Einfluss des hydrostatischen Drucks auf die Blutbewegung, Anpassung der Gefäße. In Bethe A, Bergmann G v, Embden G, Ellinger A, eds., Handbuch der normalen und pathologischen Physiologie, Vol. VII, part 2. Springer, Berlin, pp. 1414–1439.
10. Uchigasaki S, Takahashi H, Suzuki T (1999) An experimental study of death in a reverse suspension. Am J Forensic Med Pathol 20, 116–119.
11. Wilkins RW, Bradley SE, Friedland CK (1950) The acute circulatory effects of the head-down position (negative G) in normal man, with a note on some measures designed to relieve cranial congestion in this position. J Clin Invest 29, 940–949.
12. Deklunder G, Lecroart JL, Chammas E, Goullard L, Houdas Y (1993) Intracardiac hemodynamics in man during short periods of head-down and head-up tilt. Aviat Space Environ Med 64, 43–49.
13. Folkow B, Heymans C, Neill E (1965) Integrated aspects of cardiovascular regulation. In Hamilton WF, Dow P, eds., Handbook of Physiology, Sect. 2, Vol. III. American Physiological Society, Washington DC, pp. 1787–1823.
14. Gauer OH, Thron HL (1965) Postural changes in the circulation. In Hamilton WF, Dow P, eds., Handbook of Physiology, Sect. 2, Vol. III. American Physiological Society, Washington DC, pp. 2409–2439.
15. Shulzhenko EB, Panfilov VE, Gogolev KI, Aleksandrova EA (1979) Comparison of physiological effects of head-down tilting and immersion on the human body. Aviat Space Environ Med 50, 1020–1022.
16. Kirsch KA, Baartz FJ, Gunga HC, Röcker L, Wicke HJ, Bünsch B (1993) Fluid shifts into and out of superficial tissues under microgravity and terrestrial conditions. Clin Invest 71, 687–689.
17. Loeppky JA, Roach RC, Selland MA, Scotto P, Luft FC, Luft UC (1993) Body fluid alterations during head-down bed rest in men at moderate altitude. Aviat Space Environ Med 64, 265–274.
18. Loeppky JA, Roach RC, Selland MA, Scotto P, Greene ER, Luft UC (1993) Effects of prolonged head-down bed rest on physiological responses to moderate hypoxia. Aviat Space Environ Med 64, 275–286.
19. Baisch FJ, Petrat G (1993) Body fluid distribution in man in space and effect of lower body negative pressure treatment. Clin Invest 71, 690–699.
20. Draeger J, Schwartz R, Groenhoff S, Stern C (1993) Self-tonometry under microgravity conditions. Clin Invest 71, 700–703.
21. Mader TH, Gibson CR, Caputo M, Hunter N, Taylor G, Charles J, et al. (1993) Intraocular pressure and retinal vascular changes during transient exposure to microgravity. Am J Ophthalm 115, 347–350.

22. Drummer C, Heer M, Dressendörfer RA, Strasburger CJ, Gerzer R (1993) Reduced natriuresis during weightlessness. Clin Invest 71, 678–686.
23. Lacolley PJ, Pannier BM, Cuche JL, et al. (1993) Microgravity and orthostatic intolerance: carotid hemodynamics and peripheral responses. Am J Physiol 264, H588–H594.
24. Frey MAB, Mader TH, Bagian JP, Charles JB, Meehan RT (1993) Cerebral blood velocity and other cardiovascular responses to 2 days of head-down tilt. J Appl Physiol 74, 319–325.
25. Harrison MH, Rittenhouse D, Greenleaf JE (1986) Effect of posture on arterial baroreflex control of heart rate in humans. Eur J Appl Physiol 55, 367–373.
26. Yamazaki F, Matsumura N, Nagata J, Ando A, Imura T (2001) Spontaneous arterial baroreflex control of the heart rate during head-down tilt in heat-stressed humans. Eur J Appl Physiol 85, 208–213.
27. Trumbach S (1988) Glukose-Toleranz und Insulin-Sekretion unter simulierter Schwerelosigkeit. Medical Thesis, RWTH Aachen, Germany.
28. Allmers H (1992) Zirkadiane Rhythmik bei der Simulation eines D-2 Weltraumfluges. Medical Thesis, RWTH Aachen, Germany.
29. Lathers CM, Diamandis PH, Riddle JM, Mukai C, Elton KF, Bungo MW, et al. (1990) Acute and intermediate cardiovascular responses to zero gravity and to fractional gravity levels induced by head-down or head-up tilt. J Clin Pharmacol 30, 494–523.
30. Schmidt P, Madea B (2004) Tod in abnormer Körperposition—Physical restraint. In Madea B, ed., Praxis Rechtsmedizin. Springer, Berlin, pp. 204–208.
31. Glatter K, Karch SB (2004) Positional asphyxia: inadequate oxygen, or inadequate theory? Forensic Sci Int 141, 201–202.