42 Composite Facelift

Sam T. Hamra, Ramsey J. Choucair

42.1 Introduction

Facelift surgery has always been a significant part of the practice of plastic surgery from the early part of the twentieth century. In spite of the dramatic advances that have been made in the last 20 years with body contouring and rhinoplasty, much of the basic principles of facelift surgery have remained the same since the introduction of facelift techniques.

Two factors strongly influenced the changes in plastic surgery techniques. First is the demand for surgery by the general population. With the younger and more affluent population more preoccupied with fitness and health, body contouring has continued to evolve significantly owing to the expectations of patients. The second factor that allows development of better techniques is the disappointment from results obtained with traditional techniques. The most obvious example would be rhinoplasty surgery where newer techniques have advantages over the shortcomings of older techniques that left patients with suboptimal results. However, in spite of the recognition of poor results that have driven improvements in body contouring and rhinoplasty, plastic surgeons' frequent fear of using of newer facelift techniques has prevented widespread use of more complicated and advanced facelift procedures.

The advantage of simpler techniques in facelift surgery has continued to be based on the acceptable results seen in the early postoperative period when patients have some degree of edema helping an early reentry into normal lifestyle. Unfortunately these results may fade early as the unwanted appearances of patients who once had facelifts become obvious to their friends and the public at large as a very unattractive result. Up to recently, these results have been very difficult to correct.

The composite facelift has evolved over a 30 year period, by gradually adding and developing various techniques which influence separate parts of the face. Evolution that began with a simple subcutaneous lift has become a comprehensive or global procedure that influences essentially every deep structure of the aging face whose character influences the topography of the face. While facelifts in general appear to be similar to the public and even to aesthetic surgeons who are not actively involved in a facelift practice, there are very definite and clear differences between conventional facelifts and composite facelifts.

42.2 Differences in Technique

Because of the confusion in various words in the facelift literature, both patients and surgeons may not have a clear understanding of the potential result of various techniques since descriptions have overlapping meanings. Historically, one thinks of the traditional facelift as a subcutaneous dissection where the skin is lifted off the deep structures of the face and redraped in a superior lateral vector. In the mid-1970s the tension was directed to the platysma muscle of the lower face in the manner of Skoog [1]. Skoog is clearly the first surgeon who developed the technique where the deep structure was moved as well as the skin. In the Skoog technique the skin of the lower face remains attached to the platysma of the lower face, which he called superficial fascia. Lemmon and Hamra [2] presented the only large series of Skoog facelifts which was done between 1973 and 1978. Following the basic principles of the Skoog technique, Tessier coined the expression superficial musculo-aponeurotic system (SMAS) and Mitz and Peyronie [3], working under the direction of Tessier published the paper on SMAS techniques.

Following the emphasis on neck procedures in the early 1970s the second step in the development of composite rhytidectomy was the triplane facelift technique [4] published in 1982. In this technique, the Skoog flap of the face is separated from a preplatysma neck dissection . The maintenance of the meso-mandibularis mesentery separated the face from the neck dissections since the neck dissection was preplatysmal and the face dissection was subplatysmal. This mesentery was a structure that included the rami-mandibularis but allowed movement of the neck and

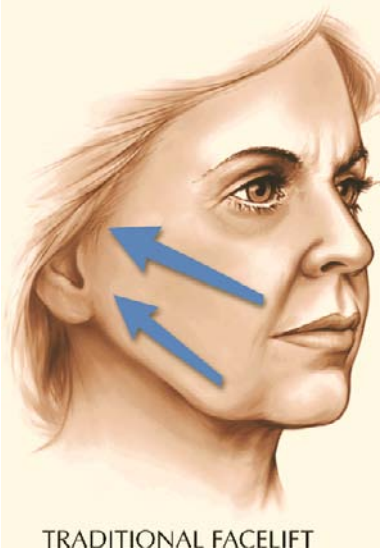

Fig. 42.1. Traditional facelift. The direction of lift in the traditional facelift is singular and lateral toward the ear. This is the only direction of pull. (Courtesy of S. Hamra, Dallas)

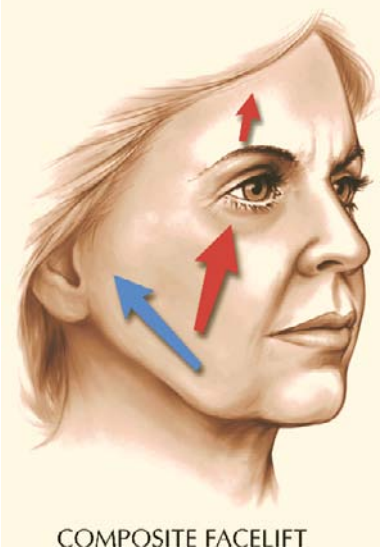

Fig. 42.2. Composite facelift. The composite facelift direction of lift is multidirectional and oblique toward the eye and ear rather than just toward the ear. The movement of the cheek returns the aging eyelid muscle and cheek fat to their original positions, preventing the pull toward the ear. The forehead also is lifted up. (Courtesy of S. Hamra, Dallas)

face tissues without inhibition owing to the principle of mesentery movement. In 1985, the third structure in composite rhytidectomy was included, which was the fat overlying the zygomaticus major and minor muscles. It was clear that the safety of elevation of the fat overlying the muscles allowed inclusion of the cheek fat or "malar fat" in the deep subcutaneous plane facelift flap which now included the fat of the naso-labial fold and the platysma muscle and the skin. This technique, which was called a deep plane facelift [5] was published in 1990 and ushered in an era of "malar fat" procedures championed by many authors and surgeons [6–10]. Thus, when one mentions conventional facelifts they may be subcutaneous lifts, SMAS lifts or deep plane facelifts. It should be noted that these are all lateral vector facelifts and in spite of various names and acronyms all basically accomplish the same correction of the face from the bottom portion of the soft tissue orbit to the jawline. Thus, when one uses the term "conventional facelifts" the reference will include either subcutaneous facelifts, or deep plane (malar fat) facelifts or SMAS lifts, as seen in Fig. 42.1.

It was at this point in 1990 that the continuation of the evolution of the composite facelift took a major turn away from the conventional technique. In 1992 the composite [11, 12] facelift was published which incorporated the orbicularis oculi muscle with the facelift flap so that the orbicularis, malar fat, and platysma muscle would all be left with the skin and the repositioning of all three deep anatomical parts of the aging face could be accomplished while maintaining their intimate relationship with one another. One should remember that when the surgeon or the patient simulates a facelift by putting pressure with their hands on the face in an upward direction, they are essentially doing a composite movement of the underlying tissues rather than just a movement of skin lift or a deep plane facelift. When one thinks in terms of a composite facelift, the vectors are dramatically different from the vectors of a conventional facelift since there is a strong superior medial vector of the upper face (Fig. 42.2) and an obligatory medial vector of the forehead lift as opposed to the superior lateral vector of the face with conventional facelifts or conventional forehead lifts.

Even though the orbicularis muscle became the fourth part of the composite facelift there was still a suboptimal lower eyelid created by conventional blepharoplasties whether transconjuncital or transcutaneous, since conventional lower blepharoplasties have always called for removal of some of the lower-eyelid fat. (Fig. 42.3) In 1995 the lower eyelid fat was preserved with a technique called the arcus marginalis release [13] that advocated repositioning the lower-eyelid fat over the orbital rim. (Fig. 42.4). In this way the junction of the lower eyelid and cheek could be totally camouflaged, achieving a much more youthful contour of the upper face. As the composite facelift continued to be developed, the zygomaticus musculature was included with the orbicularis movement with development of a zygomaticus–orbicularis flap

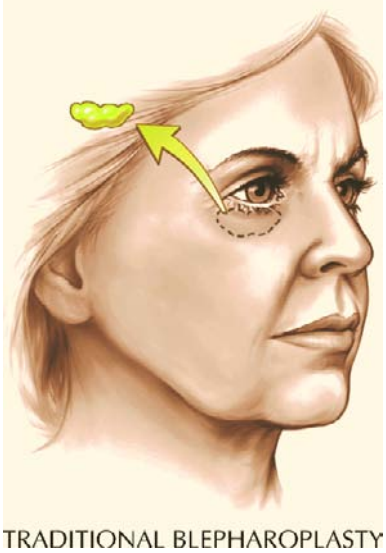

Fig. 42.3. Traditional blepharoplasty. In traditional facelifts, the lower-eyelid lift, or lower blepharoplasty, is optional. Typically, in a lower-eyelid procedure, the fat pads that cause puffines are removed without regard to the possible long-term effects. Over time, this wholesale removal of fat can create a hollow or concave appearance of the eye. (Courtesy of S. Hamra, Dallas)

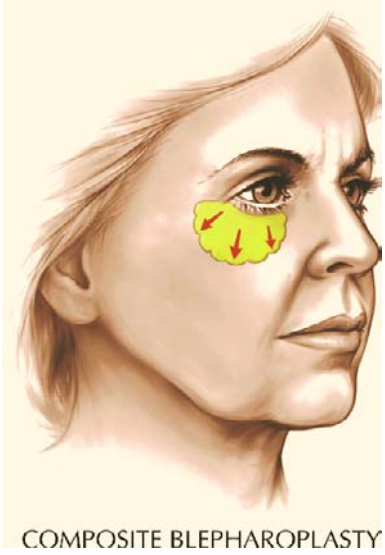

Fig. 42.4. Composite blepharoplasty. The lower blepharoplasty is an integral part of the composite facelift. To create a natural transition between the soft under-eye tissue and the cheekbone, the composite facelift incorporates a special technique in which the fat under the eye is preserved and repositioned over the orbital bone. This method creates a smooth youthful contour. (Courtesy of S. Hamra, Dallas)

called "a zygorbicular flap" [14]. This created a second mesentery with a facelift called a meso-zygomaticus. In addition, the lower-eyelid fat was kept attached to the septum orbitale so that a septum orbitale reset could be accomplished following the arcus marginalis release.

It is this final maneuver which has created the present state of the art for composite facelifting.

42.3 Harmonious Facial Rejuvenation

An aging face is more than just separate parts of the face. As humans age, every part of the face undergoes changes almost simultaneously. Whereas eyelid changes may start in the third decade, by the mid-40s the average person usually has a uniform and harmonious appearance of normal aging. When we analyze the patient in the standing position, the vectors of aging are well known because the forehead, cheek, and jowl areas descend downward in a predictable manner (Fig. 42.5a). Loss of contour of the youthful neck has long been understood as have recognizable changes in the naso-labial fold and jowl area. While lower facial aging has been reversed with conventional facelifts for many decades, the peri-orbital area was an area that was poorly understood and frequently ignored except for removal of lower-eyelid fat with traditional blepharoplasty techniques. The removal of this lower-eyelid fat did little to give true peri-orbital rejuvenation. As the peri-orbital area ages, the changes are inevitable because of normal skeletonization that occurs as the patient enters the fourth decade. (Fig. 42.6a).

From the front view, the peri-orbital diameter becomes wider because the youthful eye usually shows no signs of bony anatomy and becomes wider with aging. The youthful eyelid shows no signs of the underlying bony anatomy. The peri-orbital diameter is very narrow with a very convex appearing lower youthful eyelid. As one ages the appearance is of a deeper and concave lower eyelid compared with the convexity seen in the lower eye. Just for that reason, the arcus marginalis release with preservation of the lower-eyelid fat is obligatory in composite rhytidectomy in order to create a more youthful appearing lower eyelid (Fig. 42.6b).

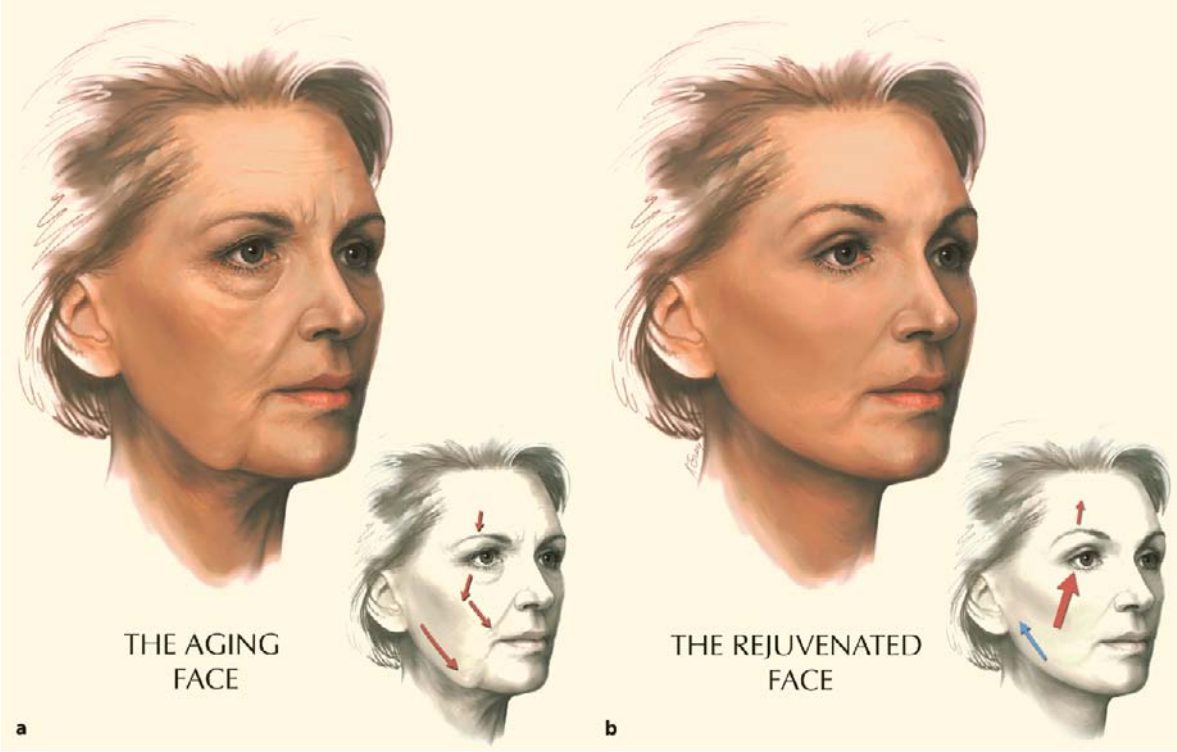

Fig. 42.5. **a** The aging face. *Arrows* demonstrate the normal gravitational direction of aging. **b** The rejuvenated face. The normal direction of aging must be reversed to achieve optimal results. The *arrows* demonstrate the two-direction lift of the composite facelift (Courtesy of S. Hamra, Dallas)

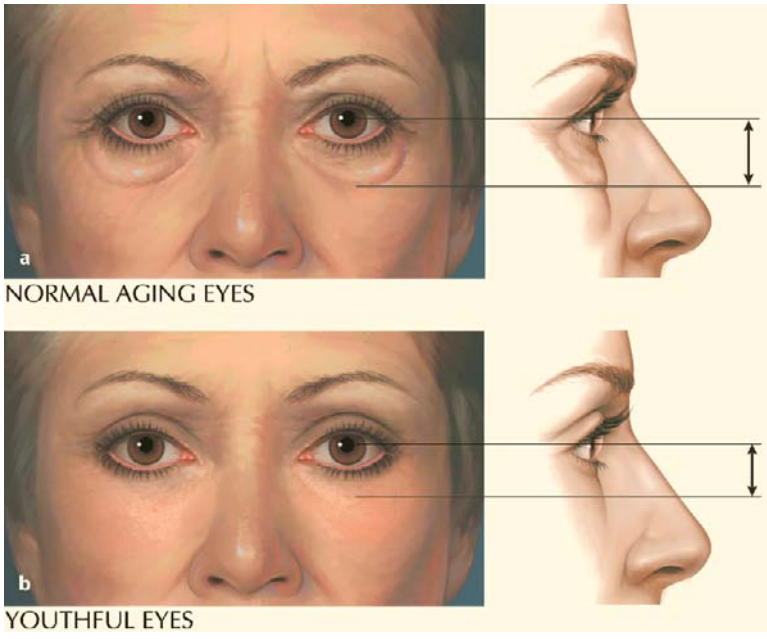

Fig. 42.6. **a** Normal aging eyes. Contours have become wider and deeper. **b** Youthful eyes. Narrow, shallow, youthful contours are restored with a composite blepharoplasty. (Courtesy of S. Hamra, Dallas)

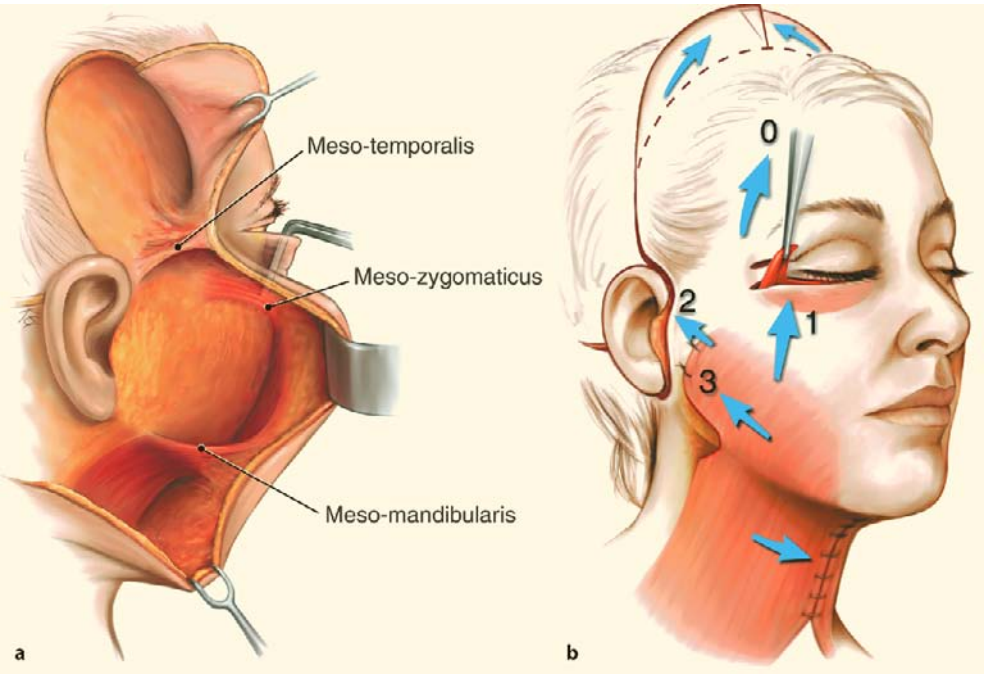

Fig. 42.7. **a** The three mesenteries are created during the composite facelift dissection. The meso-temporalis contains the branches of the frontal nerve. The meso-zygomaticus contains the nerve branches to the zygomaticus musculature and the meso-mandiublaris contains the rami-mandibularis. **b** The mesenteries permit superiomedial movement of the face and forehead without restriction. The tension on point *1* must be stronger than the tension on points *2* and *3* to prevent a lateral sweep. (Courtsey of S. Hamra, Dallas)

42.4 Composite Repositioning

In conventional rhytidectomy one utilizes a lateral vector, which allows a surgeon to do a facelift without a blepharoplasty since the skin can be redraped toward the temple or helix of the ear. This is impossible in composite rhytidectomy since the strong superior medial movement of the upper face dictates a superior movement of the forehead. As discussed earlier, there are three distinct mesenteries (Fig. 42.7) created that contain the facial nerves. Because of the theory of mesentery movement, the surgeon can effectively move the tissues of the face in an uninhibited fashion (Fig 42.7b) which is done in a superior medial direction rather than in a vertical or superior-lateral direction. The meso-temporalis mesentery has long been recognized and is it contains the frontal branch of the facial nerve. The meso-zygomaticus and meso-mandibularis are unique to the composite facelift. As opposed to the composite movement of the SMAS, malar fat, and orbicularis muscle, the neck continues to be done much like the original triplane facelift procedure except that much more vertical movement can be accomplished in the lower face area at the junction of the face and neck. Since the dissection is in a preplatysmal plane the amount of fact that is present can be evaluated after elevation of the flap and then defatting can be done with a scissor technique. Following defatting and reapproximation of the anterior bands, the neck skin is redraped in a posterior direction, while the skin and muscle of the jowl and lower face are moved in a more superior direction. The platysma of the neck is moved in a medial direction toward the midline. One should remember that the evaluation of the aging neck is done when the patient is in a standing position and it is the gravitational force of aging that creates the midline looseness of the neck which one can correct with excision of extra muscle and fat and approximation of the platysma bands.

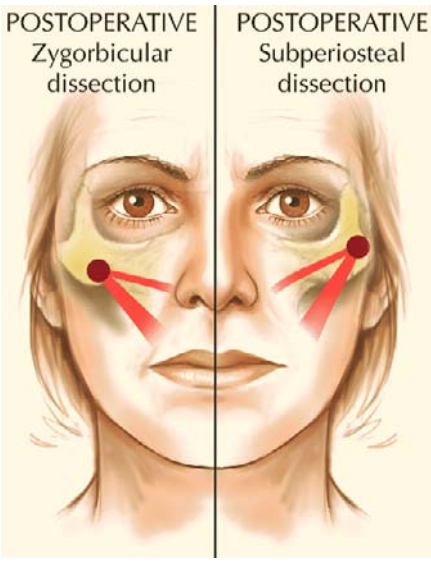

Fig. 42.8. The origin of the zygomaticus muscle does not change following a composite facelift. The origin does change following subperiosteal cheeklift or facelift by widening the soft tissue intermalar distance, which thereby changes the patient's appearance. (Courtesy of S. Hamra, Dallas)

The more impressive and predictable results with composite facelifts have been accomplished since 1996 after development of the zygorbicular dissection of the midface. Subperiosteal facelifts may create the appearance of a more widened inframalar distance owing to repositioning of the origin of the zygomaticus major and minor (Fig. 42.8). This will not occur with composite rhytidectomy. In composite rhytidectomy, the origin of the zygomaticus musculature is not disturbed as the zygorbicular flap dissection extends both medial and lateral to the osseous origin of the zygomaticus major and minor. As the muscle origin stays intact, the meso-mandibularis and meso-zygomaticus allow composite movement of the orbital area in a superior medial direction.

While subperiosteal dissections are of great benefit in secondary facelifts requiring reconstruction of the lower eyelid, they are not routinely practiced in composite facelift since the tissues of the face appear to reveal more aging of the skin down to fat and muscle rather than the periosteum. While the periosteum does furnish a strong platform for movement of the cheek, the stretch of the soft tissues of the zygorbicular flap create a normal and softer appearance of the upper cheek and lower eyelid.

The rejuvenation of the face following composite facelifts can produce a very harmonious appearance (Fig. 42.9) [2] The best way to assay the effects of rejuvenative facelift surgery is with a half-and-half photograph showing the preoperative hemiface juxtaposed with the postoperative same-side hemiface photograph as shown in Fig. 42.9. Up to this point there has been no quantitative procedure to evaluate facelift results. Because of the harmonious appearance of the youthful orbit as seen in the frontal views, a very definite difference can be now understood between conventional rhytidectomy and composite rhyitdectomy. Following conventional rhytidectomy, there will be no changes in the vertical height of the soft tissue orbit. If malar fat procedures or a SMAS procedure is utilized with a conventional blepharoplasty, one cannot achieve a shortened vertical height of the lower eyelid. Moreover, if lower eyelid fat is removed it is quite possible that a normal concave lower eyelid will appear more hollow, which will never be the case with preservation of the lower-eyelid fat in composite rhytidectomy (Fig. 42.10).

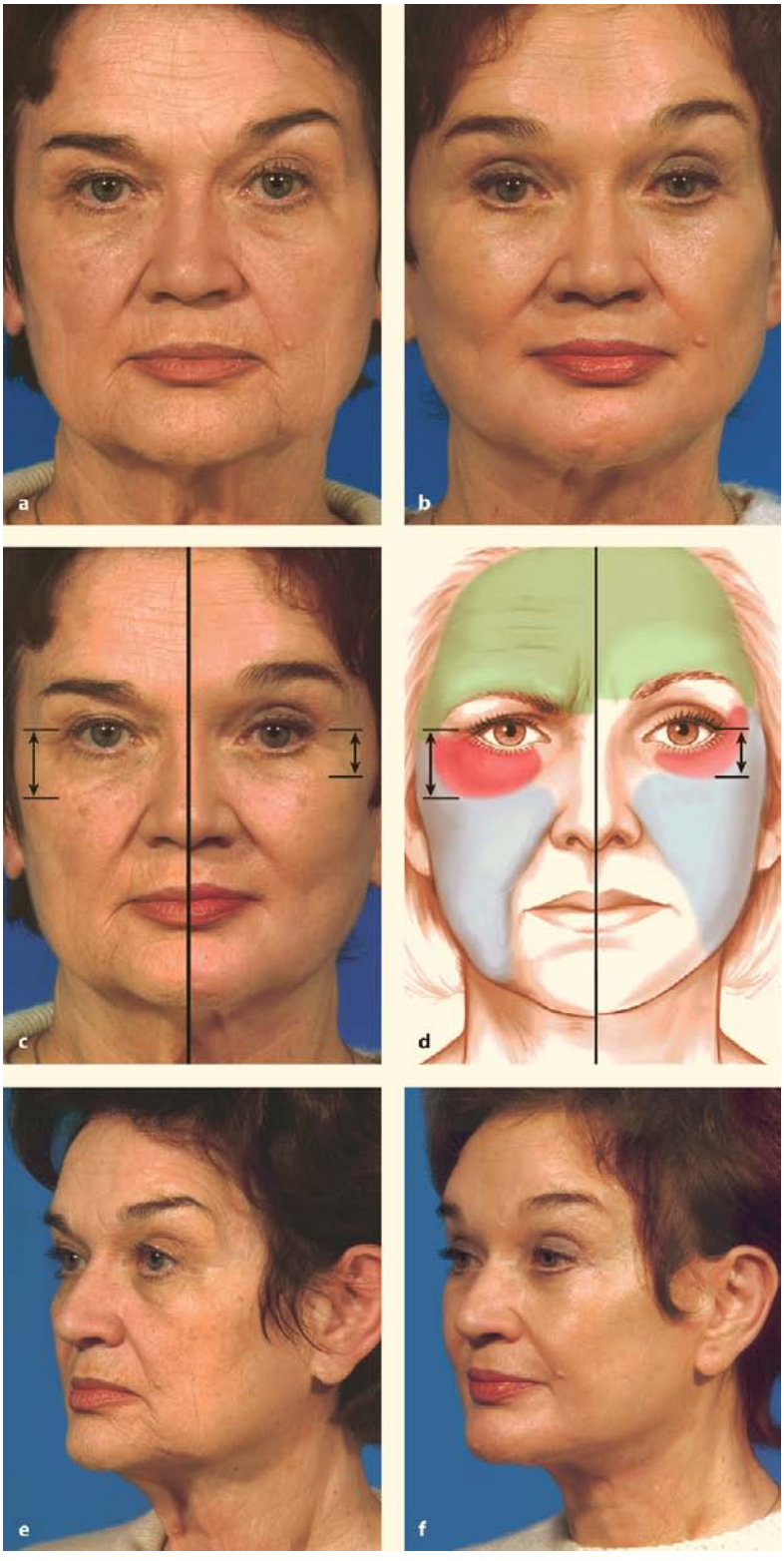

Fig. 42.9. **a** Preoperative patient with a negative lower-eyelid vector with typical signs of aging. **b** Postoperative primary composite facelift, browlift and blepharoplasty with arcus marginalis release. All orbital fat was preserved. **c** Preoperative right hemiface compared with postoperative right hemiface. **d** The hemiface comparisons prove that all three zones have been rejuvenated significantly for facial harmony. (Courtesy of S. Hamra, Dallas).

Fig. 42.10. A preoperative view of a 44-year-old with normal signs of aging. One-year post-operative views showing no signs of underlying orbital anatomy following arcus release and septal reset in composite facelift. Hairline forehead lift narrowed the hairline 2 cm.

42.5 Utilization of Composite Rhytidectomy to Correct the Unfavorable Outcomes Following Facelift Surgery

If one examines the typical surgical appearance of patients who have had facelifts, it becomes easy to analyze the problems and why they result. The best way would be to understand the long-term changes of the vectors of conventional facelifts as shown in Fig. 42.11.

If one judges the vectors of aging of patients in the standing position, they are the same for all humans and are predictable for every person after a certain age (Fig. 42.11a). Without question the conventional facelift can create an excellent jawline but in most cases the tension on the SMAS flap is a shorter, more vertical vector and tension on the upper portion of the conventional flap including the malar fat procedure is less vertical and more superior lateral in spite of claims of vertical "malar fat repositioning." While malar fat techniques and deep plane facelifts have been an improvement over the subcutaneous procedures, the basic problem is still giving an unpredictable result to any patient undergoing conventional techniques. By omitting the surgery of the lower eyelid, the surgeon clearly can promise the patient an early return to social activity often within days. One must remember that a facelift cannot be judged over the first few months since the final results may develop over many months or even several years. With the vectors of the conventional facelift (Fig. 42.11b) there is unopposed tension of the lower face vector. The long upper face vector, however, is more horizontal and is too long to be maintained over the course of time as normal aging proceeds. Thus, the potential progressive relaxation of the orbicularis oculi muscle and cheek and malar fat tends to descend downward in time, creating the "lateral sweep" typically seen with a facelifted person (Fig. 42.11c). If a forehead lift is not done with a conventional rhytidectomy, the forehead also becomes more ptotic in time, creating further disharmony since the patient may eventually have a straight jawline with a very ptotic forehead and looseness of the upper face tissues.

Many patients have a normal crescentric anatomical pattern on the upper cheek area called a malar crescent (Fig. 42.12). The problem with this excessive orbicularis muscle that may become a malar mound or festoon is that it is made even worse with a simple superior lateral facelift, since it is not changed and is in fact made more obvious. While it appears quite normal on a normal unoperated aging face, it becomes a distinct stigma of previous surgery. Of greater significance is the potential for a deeper concavity of the lower eyelid created by orbital indiscriminate lower-eyelid fat (Fig. 42.13). The triad of an unoperated forehead, hollow lower eyelid, and a lateral sweep is pathogenomoic of previous facelift surgery [15]. Frequently, a second facelift is done to correct this stigma of the facelifted appearance but the same lateral vector technique may enforce the undesirable appearance. The effective tightening of the SMAS, which has more longevity than the operated upper facelift tissues in facelift surgery, can create the "pull" of the lower face. Thus, many patients who have undergone two or three facelifts look progressively more distorted in spite of the best attempts by the surgeon to correct the earlier problems. It is for this reason that a composite facelift can be utilized as the best way to reverse the stigmata of previous facelift surgery [16]. While examining a patient with a "facelifted" appearance, superior-medial tension on the patients face with the examiner's fingers will correct this appearance (Fig. 42.11d). This strong tension will counter the tension of the lower face but the flap must include the orbicularis and malar fat to be effective. Because of the need for strong superior medial movement of the face on secondary-facelift patients, the forehead lift must be done otherwise there would be bunching of the tissue in the temporal area after movement of the orbicularis oculi muscle.

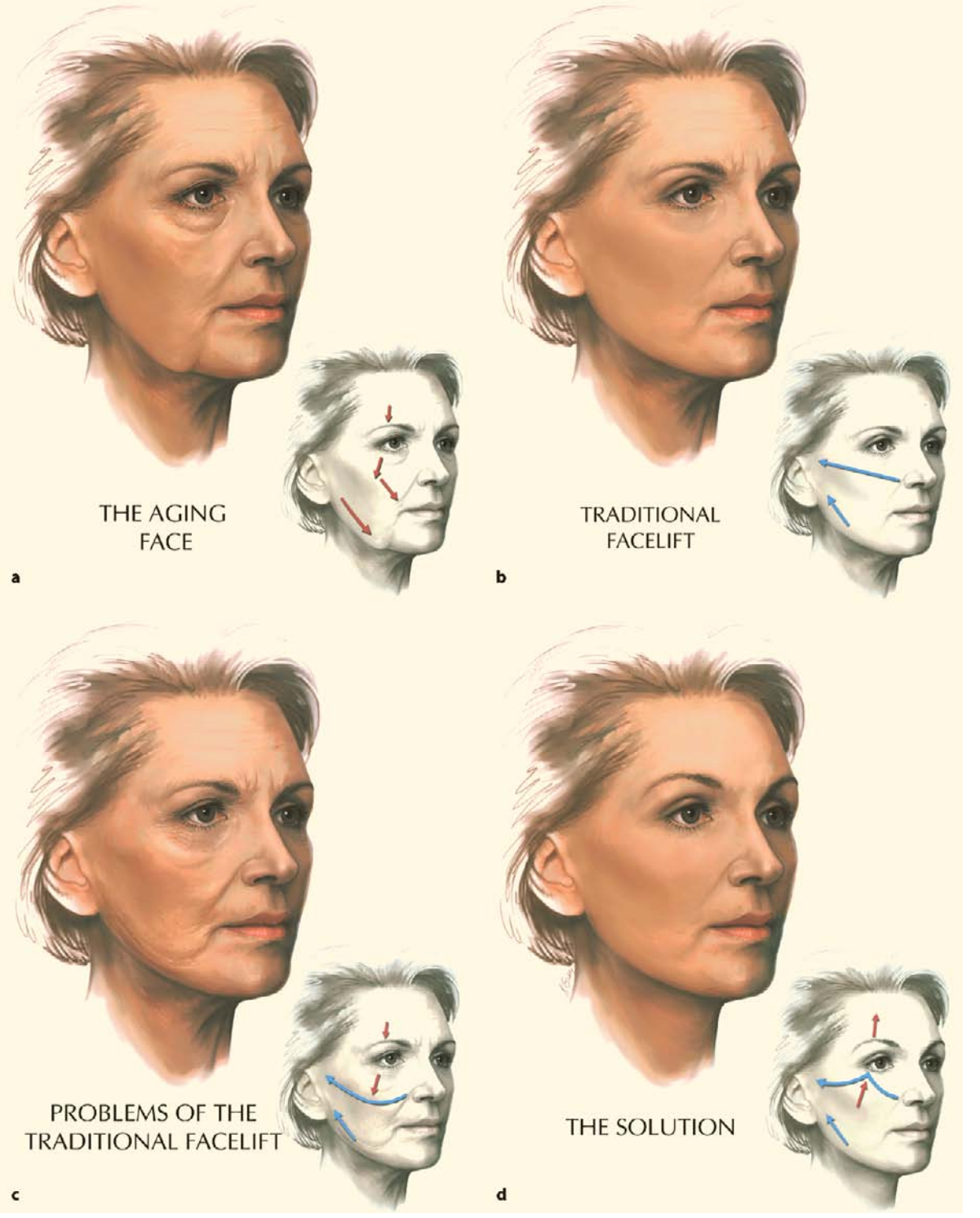

Fig. 42.11. **a** The aging face. *Arrows* demonstrate the normal gravitational direction of aging. **b** Traditional facelift. *Arrows* show the single direction of lift, toward the ear, of the traditional facelift. **c** Problems of the traditional facelift. Over time, the results of the traditional facelift begin to show signs of tension and pull. The lower pull (*short blue arrow*) stays tight, while the upper cheek (*long blue arrow*), which had only a horizontal lift, continues to fall. Areas typically not addressed by a traditional facelift (*red arrows*) continue to descend. **d** The solution. The composite facelift can correct unwanted results by lifting the muscle and fat of the cheek (*red arrows*) in the correct direction, toward the eye rather than toward the ear, which is the natural youthful position. (Courtesy S. Hamra, Dallas)

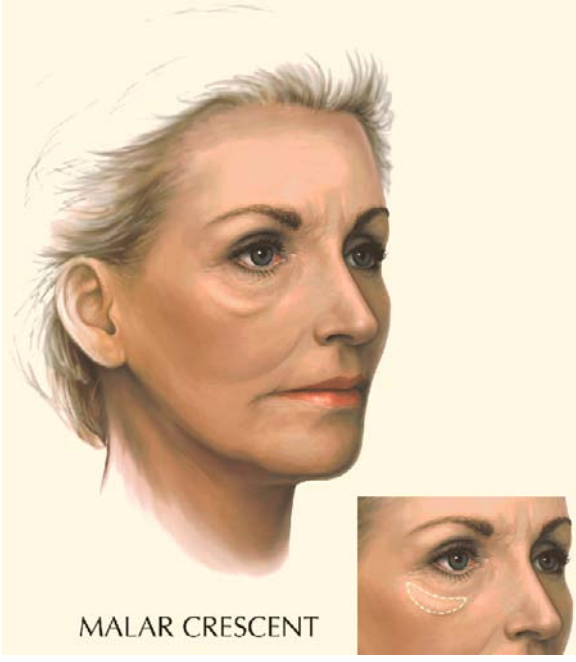

Fig. 42.12. Malar crescent. This crescent-shaped fullness corresponds to the lower eyelid muscle (orbicularis muscle) and occurs along the upper cheek area. Because the orbicularis muscle is not addressed in a traditional facelift, it appears more pronounced next to the hollowness created by the traditional lower-eyelid lift and the pull of the traditional facelift. (Courtesy of S. Hamra, Dallas)

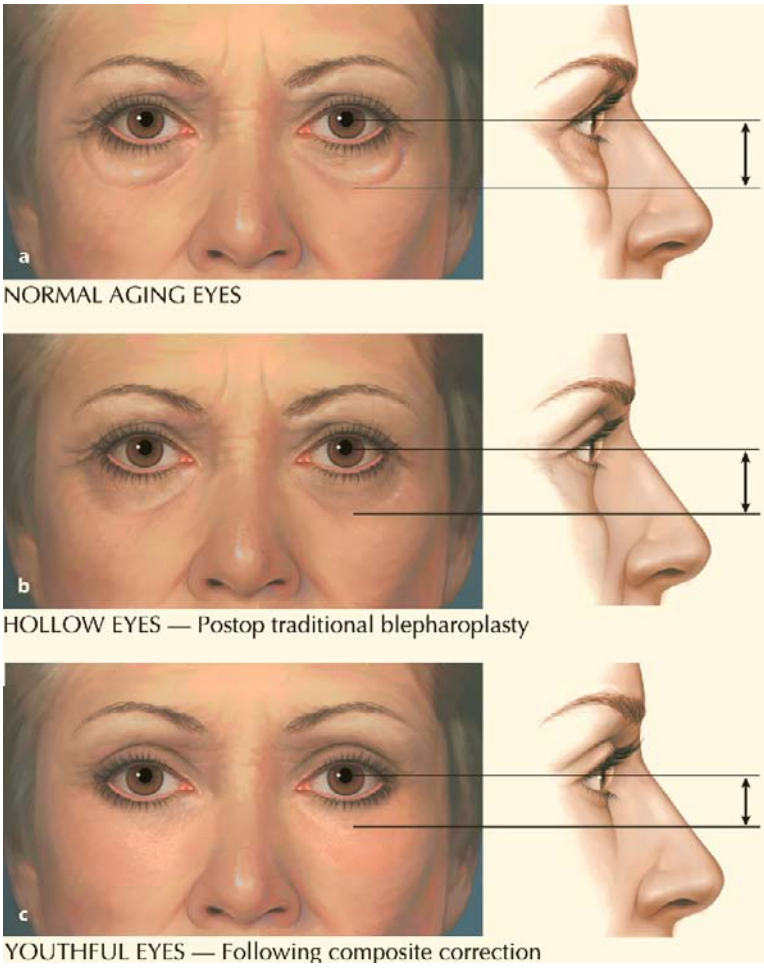

Fig. 42.13. **a** Normal aging eyes. Contours have become wider and deeper. **b** Hollow eyes. The area beneath the eye appears more concave or hollow than before. The soft-tissue diameter of the peri-orbit remains the same. **c** Youthful eyes. Narrow, shallow, youthful contours are restored with a compsite blepharoplasty. The diameter is narrowed. (Courtesy of S. Hamra, Dallas)

42.6 Stigmata of Previous Facelifts

42.6.1 The Lateral Sweep

The lateral sweep (Figs. 42.11c, 42.16) continues to be a postfacelift deformity which is most recognized by the lay public. This is an appearance seen frequently at affluent social gatherings since it is the affluent population of the USA that has undergone most facelift procedures. It is an appearance most often recognized by people and seen frequently by celebrities and is usually called the "pulled" look. It is an appearance that seems more obvious in patients with sun-damaged skin or excessive rhytids or in the direction of the rhytids and clearly delineates the lateral sweep deformity.

42.6.2 Malar Crescent

The malar crescent (Fig. 42.12) is an obvious topographical landmark that cannot be corrected without repositioning the total orbicularis oculi muscle. The malar crescent is the inferior portion of the orbicularis oculi muscle which is never moved in conventional facelift techniques. If it preexists, it will become more obvious after facelifts. Strong vectors created by malar fat procedures can create what appears to be a crescent that was not present prior to surgery. This deformity can be totally corrected by repositioning the orbicularis oculi muscle with the zygomaticus muscle.

42.6.3 Unoperated Forehead

In most facelift surgeries today, the forehead lift is not a consistent part of facial rejuvenation. Since many surgeons and many patients omit this procedure for various reasons, while a patient may undergo a subcutaneous facelift with minimal changes in their early 40s, it would be illogical to assume that the changes are long-lasting. If they are long-lasting then one would agree that the unoperated forehead will become more ptotic, thereby creating a disharmonious appearance in time. On the other hand, if the facelift is considered a "light" procedure with a short longevity, then the patient normally becomes disenchanted with the results which accomplish little of what was expected. Unfortunately, many patients have had an excessive amount of skin removed from the upper eyelid, making a forehead lift often impossible since eye closure would be a problem.

42.6.4 The Pulled Mouth

The pulled mouth appears frequently and is one of the most recognizable signs of surgery to the lay public. With continuing tension on the SMAS, the looser upper cheek tissues seem redundant compared with the very tight tension on the modiolus. Frequently one must release this tight SMAS when doing a secondary facelift.

42.6.5 Hollow Eyes

Because blepharoplasty is done frequently without facelifts and orbital fat is usually removed in standard conventional blepharoplasty, a more concave or hollow-appearing lower eyelid is commonly seen. If one examines typical photographs of pre-and postoperative patients who have undergone a blepharoplasty, either conjunctival or transcutaneous, there is never a postoperative difference in the vertical height of the lower eyelid compared with the preoperative diameter (Fig. 42.13). Laser blepharoplasty, which has become a highly marketed procedure in the last few years, has been promoted as a scarless procedure for peri-orbital rejuvenation; however, many problems are now seen owing to the indiscriminate removal of lower-eyelid fat and the inability to move the cheek in an upward position. The removal of the lower-eyelid fat creates a more concave appearance than before as the skin drops into this concavity and wrinkling may occur. It is for this that the surgeon uses laser techniques to remove the excessive wrinkling that was created by the transconjunctival fat removal. The surgeon then advocates a canthopexy to prevent the "round eye" appearance. If one examines the eyes of the patient when she/he was younger there is usually a convex lower eyelid with a very short vertical height of the lower eyelid. The idea of the surgery is to make youthful contours. It is easy to see why standard blepharoplasties may fail in rejuvenation and may in fact create an unfavorable result since the youthful lower eyelid is not only convex but has a shortened vertical height. One can apply the composite principles to create this. The proof that an arcus marginalis release and zygorbicular advancement is ideal for the primary patient can be seen when approaching the secondary hollow lower eyelid. In many cases the hollow lower eyelid from previous conventional bleparoplasty can be made or totally corrected and the unfavorable appearance can be totally negated by a secondary procedure. (Figs. 42.14–42.16) If the hollow lower eyelid can be corrected, one can only assume that this procedure as a primary procedure will prevent that patient from the ill effects that are possible with conventional blepahroplasty surgery. This repositioning

Fig. 42.14. This 52-year-old had a conventional blepharoplasty 4 years prior to correction with composite facelift and arcus release. Adequate fat was recruited from the subseptal area, to correct the hollow lower eyelid

Fig. 42.15. Correction of the hollow eyes created by a conventional blepharoplasty by composite rhytidectomy, coronal browlift and chin implant

Fig. 42.16. Correction of lateral sweep and hollow lower eyelids in this 62-year-old who had undergone conventional facelift, blepharoplasty and coronal browlift 6 years previous

of the fat and the septum is a permanent change and will give the patient a lifetime without any negative or unattractive appearance that was acquired after cosmetic surgery.

42.7 Summary

Because of the great demand in the last several years for aesthetic surgery and because of the impact of managed care in medicine in the USA, there have been many unforeseen changes. Managed care with its long-reaching problems has encouraged surgeons and doctors from other specialties to perform cosmetic procedures without adequate training. In addition, the need for marketing has sold the public on the advantage of short and simple procedures in facelifting that may allow only a few days of convalescence. With more public awareness of poor results, there appears to be less enthusiasm for facelift surgery as there has been a progressive drop in the number of facelifts in the USA for the past 50 years as compared with the increased popularity of breast implants, liposuction and other nonfacial techniques. Unfortunately the steeper learning curves for more sophisticated techniques make widespread use of these techniques impractical. However, surgeons with adequate facelift practices and experience can learn composite facelifting, which is a simple application of the principles of soft tissue surgery that most well-trained surgeons can easily perform. Suboptimal results following body contouring or breast surgery do exist but are usually guarded as a personal problem with no public awareness. The ability to create a harmonious and attractive result with composite facelifts may well be the ideal marketing tool since these unique results are obvious to the patient and others as well. A surgeon who learns composite facelifting will be served well by performing primary and secondary procedures since the composite facelift appears to be the only documented and published procedure that can correct problems created by conventional techniques. While facelift deformities are not the fault of the surgeon but are unintentional sequelae of older techniques, it is therefore the techniques which must be examined and changed. Composite rhytidectomy as a primary procedure will create a harmonious facial rejuvenation which will disallow the appearance of unwanted deformities.

References

1. Skoog T. Plastic Surgery: New Methods and Refinements. Philadelphia: Saunders, 1974.
2. Lemmon MD, Hamra S.T. Skoog Rhytidectomy: A Five Year Experience. Plast Reconstr Surg 65:3, 1980.
3. Mitz V, Peyronie M. The superficial musculaponeurotic system (SMAS) in the parotid and cheek area Plast Reconstr Suirg 58:80, 1976.
4. Hamra ST. The tri-plane facelift dissection. Ann Plast Surg 12:268–74, 1984.
5. Hamra ST. The deep plane rhytidectomy. Plast Reconstr Surg 86:53, 1990.
6. Owsley JQ Jr, Zweifler M. Midface lift of the malar fat pad. Technical advances. Plast Reconstr Surg 110:674–85, 1992
7. Barton FE Jr. Rhytidectomy and the naso-labial fold. Plast Reconstr Surg 90;601–7, 1992.
8. Mendelson BC. Correction of the nasolabial fold: extended SMAS dissection with periosteal fixation. Plast Reconstr Surg 89 822–33, 1992.
9. Aston S. F.A.M.E. facelift-finger assisted malar elevation. Presented at the annual meeting of the American Society for Plastic and Reconstructive Surgery, New Orleans, LA, Sept. 1993.
10. Stuzin JM, Baker TJ and Gordon HL. The relationship of the superficial and deep facial fascias. Relevance to rhytidectomy and aging. Plast Reconstr Surg 89:441, 1992.
11. Hamra ST. Compostie rhytidectomy. Plast Reconstr Surg 90:1, 1992.
12. Hamra ST. Repositioning of the orbicularis oculi in composite rhytidectomy. Plast Reconstr Surg 90:14–22 , 1992.
13. Hamra ST. Arcus marginalis release and orbital fat preservation in midface rejuvenation. Plast Reconstr Surg 96:354–62, 1995.
14. Hamra ST. The zygorbicular dissection in composite rhytidectomy: an ideal midface plane. Plast Reconstr Surg, 102:5, 1998.
15. Hamra ST. Frequent facelift sequelae: hollow eyes and the lateral sweep: cause and repair. Plast Reconstr Surg 102:1658, 1998.
16. Hamra ST. Correcting the unfavorable outcomes following facelift surgery, Clin Plast Surg 28:621, 2001.