SMAS for Face and Neck Lifts

38

Bruce F. Connell

38.1 The Importance of the Superficial Musculoaponeurotic System in Rejuvenation of the Face

Skin is elastic and accommodates changes in the shape of our faces during movement and expression. It cannot provide sustained support for sagging deeper facial tissues (Fig. 38.1). Skin is a covering, not a support.

The superficial musculoaponeurotic system (SMAS) is closely connected to sagging facial tissues and is a logical vehicle to reposition them. The SMAS is *in*elastic and can provide a strong and sustained support of the midface, cheek and jowl and periorbital area (Figs. 38.2–38.4). Pulling on the skin flattens facial contours, whereas pulling on the SMAS enhances contours.

Using the SMAS to reposition sagging deep facial tissue allows skin to be redraped under normal tension, which preserves normal skin function and results in a natural appearance (Figs. 38.1, 38.5). Healing of skin incisions is without tension. Preauricular natural contours are preserved. In addition, using the SMAS extends the longevity of a facelift.

Fig. 38.1. **a** Detailed knowledge of the anatomy including frontal and zygomatic branches of the facial nerve is required for high superficial musculoaponeurotic system (*SMAS*) transection at the top of the zygomatic arch, which permits a more cephalad vector for midface, lid–cheek junction, nasojugal groove, elevation at the angles of the mouth and eversion of upper-lip vermilion. **b** One year postoperatively with improvement by SMAS support and release of the crow's-feet, which enabled the skin to shift the nasojugal groove from diagonal of old age to horizontal of youth and give the appearance of youthful shorter lower eyelids

Fig. 38.2. **a** Preoperative view of a 19-year-old patient whose neck contour was interfering with her modeling career. A necklift can be performed without a facelift by utilizing a submental incision, combined with an incision above the occipital hair so that the short platysma muscle could be transected along the anterior border of the sternocleidomastoid and across the neck at the cricoid. **b** One year later showing improvement made by removal of subcutaneous cervical fat by open liposuction, removal of subplatysmal submental fat by scissor dissection along with transection of the platysma muscle along the anterior border of the sternocleidomastoid and across at the cricoid. The platysma muscle was shifted laterally over the fascia of the sternocleidomastoid in the upper neck. No skin was excised and no chin implant was used

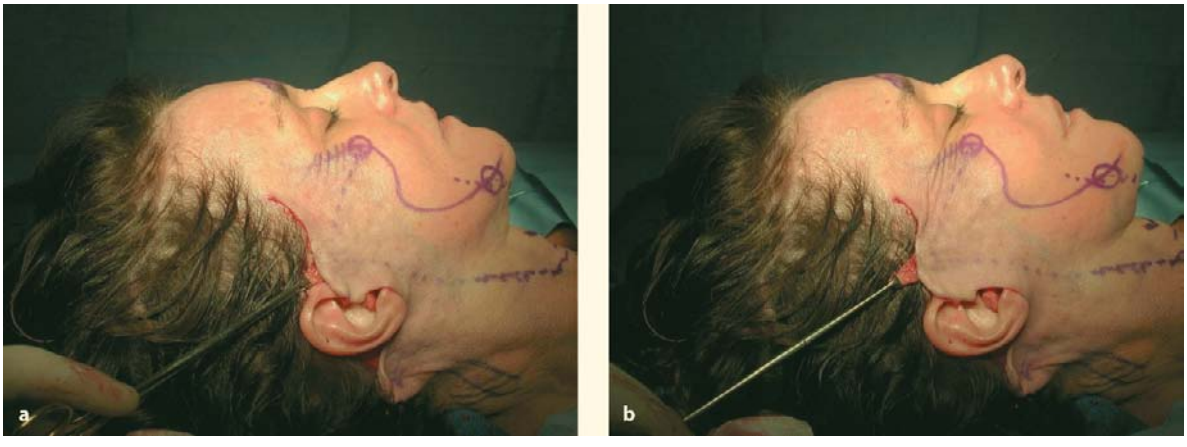

Fig. 38.3. **a** The two *circles* show the point of rotation of the SMAS at the malar bone and the attachment of the osseocutaneous mandibular ligament, which is to be released for the SMAS to have a supportive affect across the midline of the chin. The markings locate the crow's-feet to be freed from the attachment to the orbicularis oculi muscle so that the facelift skin shift can extend across the entire lower eyelid. The *dotted line* on the neck is the location of the incision of SMAS and platysma muscle and follows the anterior border of the sternocleidomastoid and crosses at the cricoid. **b** Only one Allis clamp pulling on the SMAS flap shows shortening of the appearance of the lower eyelid, shift of the skin past the crow's-feet into the lower eyelid, elevation of the angle of the mouth, eversion of the lateral vermilion of the upper lip, shifting of the skin beyond the malar ligament and beyond the mandibular ligament along with a slinglike submental support

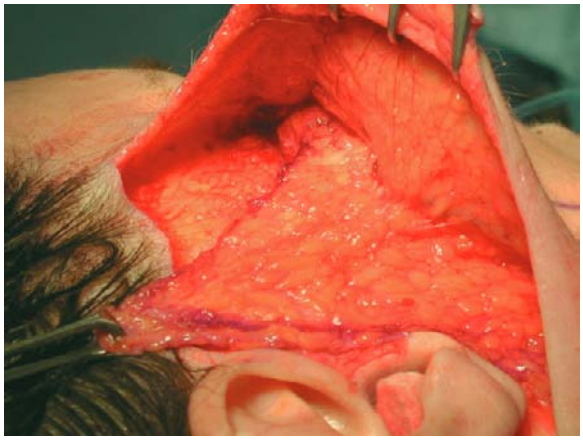

Fig. 38.4. Overlapping that is frequent with shifting of the platysma muscle in a precise vector to achieve the desired results

Fig. 38.5. **a**, **c** The release of osseocutaneous submental creases along with transection of the short platysma muscles, correction of sagging skin of the face and neck and lateral brow ptosis are corrected by utilizing deep-layer SMAS support and appropriate vectors for both the SMAS and the skin. **b**, **d** One year later the improvement has been accomplished by releasing the crow's-feet attachment to permit shifting of the skin across the entire lower eyelid and redirection of the nasojugal groove from diagonal to horizontal, high SMAS incision at the top of the zygomatic arch along with complete transection of the platysma muscle along the anterior border of the sternocleidomastoid and across at the cricoid for correction of the short playtsma. In addition, there has been release of the osseocutaneous malar ligament and the submental creases. No chin implant was used

38.2 Techniques for SMAS Utilization

Experience has confirmed the utility of the SMAS in rejuvenating the face and it has come to be an integral part of many techniques. How the SMAS is used, however, determines its overall effectiveness, and not all procedures can be expected to produce equivalent results.

Many techniques have evolved for utilization of the SMAS. These include Skoog or composite dissections in which the SMAS and skin are elevated as a single unit and advanced along the same vector, "bidirectional" dissections in which skin and SMAS layers are elevated independently and advanced along different vectors, plication techniques in which the SMAS is not elevated but is invaginated with sutures, and SMASectomy procedures in which the SMAS is partially resected and then repaired. High SMAS dissections in which the SMAS flap overlaps the zygomatic arch provide an effect on the midface and recruit and redistribute tissue over the upper malar region.

Composite and Skoog-type dissections are quick to perform and result in a thick, durable flap of both skin and the SMAS. The flap raised in these procedures has good blood supply. Consequently these techniques might be safer in smokers or when skin resurfacing is performed at the same time. They have the disadvantage, however, that skin and the SMAS must be advanced along the same vector and suspended under more or less the same amount of tension. Skin and the SMAS age at different rates and descend along different vectors. Therefore, optimal treatment of each layer is not possible. Skin overtightening, hairline displacement, "wrinkle shift" from the neck to the cheek and other unnatural appearances can result. In addition, if the orbicularis oculi is included in a "composite" flap, its motor nerve supply is often divided and lid dysfunction can result.

Separation of the skin from the SMAS has the advantage that skin and the SMAS can be moved along separate vectors and suspended under different tensions. This produces a better rejuvenation, a natural appearance and fewer secondary deformities. These two directional techniques require a high degree of surgicial skill to elevate the skin flaps without thinning the SMAS flap and are time-consuming (Table 38.1).

Plication techniques are quick to perform and do not require the level of technical skill necessary for a more tedious and potentially more hazardous SMAS elevation. Properly performed plication at multiple

Table 38.1. Superficial musculoaponeurotic system *(SMAS)* suppor

SMAS support goal	SMAS support produced by:
1. Submental area	1. SMAS separated from parotid and masseter muscle
2. Tissues at the hyoid.	2. Preauricular SMAS flap to mastoid fascia
3. Anterior cheek	3. Support anterior cheek tissues a) Large SMAS flap posterior–superior shift b) Sometimes sutures to the malar bone periosteum c) Separate superior transposition flap with vector directed toward angle of mouth d) Release of malar retaining ligament adjacent to zygomaticus major muscle
4. Angle of the mouth elevation	4. Same as point 3
5. Lower nasolabial fold	5. Posterior-superior SMAS shifting perpendicular to the fold
6. Upper nasolabial fold	6. a) Major flap incised above zygomatic arch for support of upper nasolabial fold b) Separate transposed flap of the superior portion of the SMAS c) Suture to the malar bone with support directed toward the upper fourth of the nasolabial fold d) Combination approach
7. Nasojugal groove change from aged oblique direction to youthful, horizontal direction	7. High location of SMAS transection at or above the upper border of the zygomatic arch or third flap for upper vector directed toward lower eyelid and upper nasolabial fold
8. Decrease lower-eyelid excessive skin and support by facelift skin shift	8. Release of all of the attachments of the orbicularis oculi muscles to the skin (smile crease)
9. Support to the periorbital fat of the lower lid	9. Extension of SMAS flap and transection into the lateral portion of the orbicularis oculi muscle and shifting upward in a lateral direction with a high SMAS transection or a third flap component

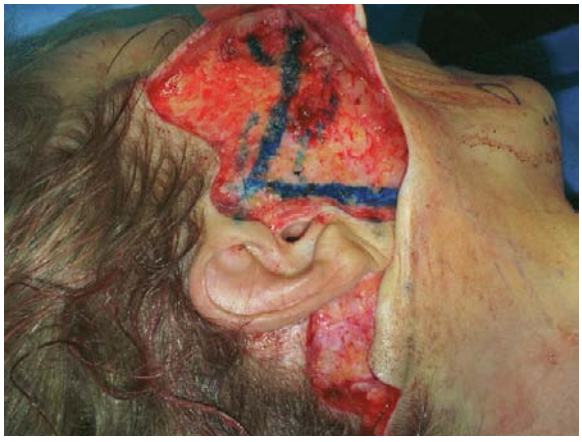

Fig. 38.6. Incision on the upper part of the zygomatic arch can often be made high enough so that a third flap is not necessary to achieve the desired vectors for the cephalad support of the cheek, jowl, midface, submental area, periorbital region, lid-cheek junction and angle of the mouth

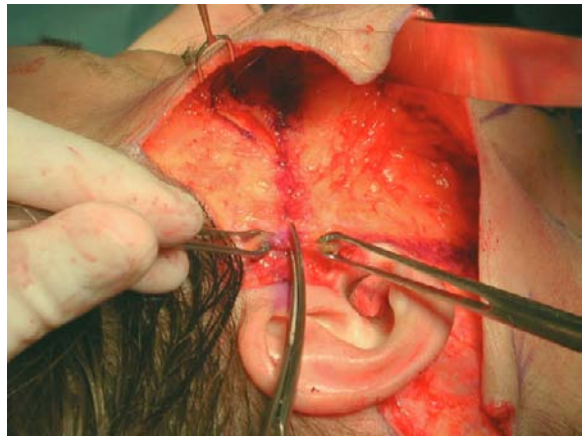

Fig. 38.7. High SMAS flap transection is safe with a detailed knowledge of the anatomy of the frontal and zygomatic branches of the facial nerve. The elevation with Allis clamps gives a clearance over the motor nerves of more than 1 cm

sites and along multiple vectors can produce long-lasting improvement in patients with moderate deformities. It has the disadvantage, however, that cheek skin must be widely undermined, and plicated tissue may result in visible contour irregularities. Plication techniques often only result in elevation of perioral tissues and the jowl, and provide limited improvement in the midface, cheek, and infraorbital and submental region. Usually plication techniques do not distribute tissue over the upper malar region where it is often needed most.

SMAS excision (SMASectomy) techniques are similar to SMAS plication, except that tissue is excised rather than invaginated. SMASectomy procedures are, however, often limited to tightening of the deep tissues along one vector only. SMASectomy and plication procedures may result in similar changes in the topography of the face. Plication at multiple sites and in multiple directions may produce better results than SMASectomy alone.

The technique we use most often liberates the SMAS from its attachments to the parotid gland, masseter muscle, zygoma and mandibular ligament and offers the advantage that the full potential of the SMAS can be realized and maximum repositioning of ptotic tissue to its youthful position can be obtained. If the SMAS is not fully released and mobile, its effectiveness will be compromised. More extended dissections with a high SMAS incision (Figs. 38.3, 38.6–38.8) have the disadvantage that it is time-consuming, technically demanding and, theoretically at least, the facial nerve branches are placed at a potentially greater risk.

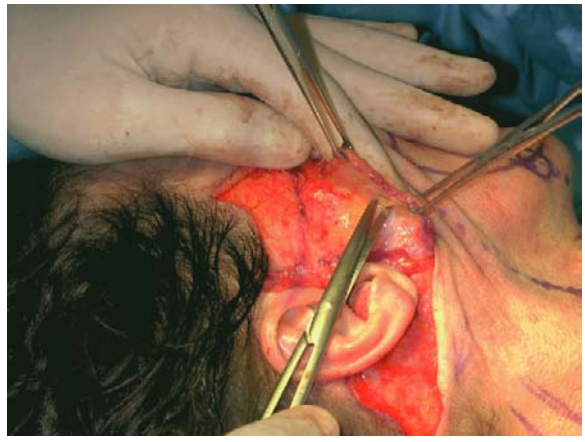

Fig. 38.8. Sharp scissor dissection is used to separate the SMAS from the parotid gland and masseter muscle and the SMAS malar connection. The SMAS flap is always adequate for support of the face unless damaged by the surgical technique of elevation of the skin overlying the SMAS

SMAS flaps are planned with a transverse incision over the upper part of the zygomatic arch, as opposed to too low, which loses 75% of the SMAS support potential. This has the distinct advantage that a more cephalad effect can be obtained on the cheek, jowl, midface, periorbital region and lid–cheek junction, and tissue can be redistributed over the upper malar region (Figs. 38.1, 38.55). The high flaps require detailed knowledge of the anatomy of the frontal and zygomatic branches of the facial nerve (Figs. 38.7, 38.8).

38.3 An Overview of Surgical Strategy

The surgical procedure described comprises a variety of designs, which must be applied as indicated by the patient's specific needs. Each patient will present with a unique set of problems, which require precise anatomical diagnosis and an appropriately planned and individualized repair.

The SMAS and the platysma are used to reposition ptotic tissues and reestablish a more youthful cervicofacial contour and make a deep support to the submental area, which skin tension alone is not capable of producing.

The skin and the SMAS are elevated independently, and the SMAS is advanced along a mostly *superior* vector. Composite tissue shifts do not permit the restoration of the beauty of the patient's younger face and neck as well as separate skin and SMAS flaps.

Additional modifications are made to the platysma and other deep-layer structures, including the orbicularis oculi muscles, submandibular glands and digastric muscles, when indicated. If problems of these structures are not identified and addressed, improvement will be compromised (Fig. 38.9).

Skin is redraped under normal tension along diagonal or *posterior* vectors. Skin tension is unnecessary for rejuvenating the face. Dismissing the skin tension concept exists as a major stumbling block to achieving a natural postoperative appearance (Fig. 38.5b).

Skin is trimmed in such a manner that wound edges touch and no gaps are present before sutures are placed to make one-layer closure, which approximates the deep and superficial skin edges without any buried suture. Support of ptotic tissue and improvement in face and neck contour are by modification of the SMAS, platysma and other deep-layer structures, and not by pulling on the skin. The use of incisions along hairlines, rather than within the scalp, may prevent objectionable hairline displacement. Hairline displacement is a major shortcoming of poorly planned incisions and is a common cause of unnatural appearances. Incisions made along hairlines will result in scars, which are usually difficult to detect once healed when deep-layer support is provided by the SMAS and skin incisions are carefully planned, placed, made and closed under no tension. A fine scar along the hairline is less noticeable and is preferable to deforming hairline displacement.

The SMAS, which has been used for more than two decades, is safe and can restore a natural youthful appearance as well as produce new, beautiful contours. This basic technique is modified for each patient and for each side of the face according to the specific and precise anatomical findings. The patient's younger photographs are reviewed for designing a natural-appearing surgical rejuvenation [1–3].

Fig. 38.9. **a** The transverse sausage like fullness in the submental area is typical of a very large anterior belly of the digastric muscle. **b** A face and neck lift using a high SMAS flap and a rotated flap from anterior to the ear under the angle of the jaw and sutured to the mastoid area along with tangential excision of 90% of the large anterior belly of the digastric muscle

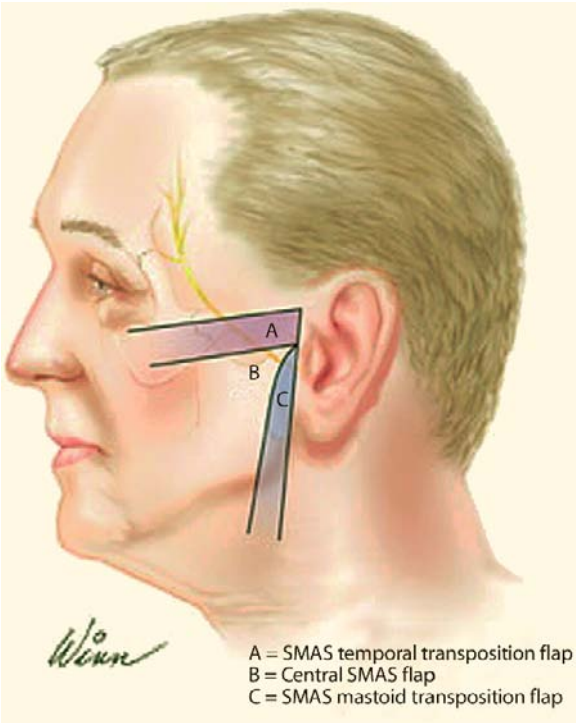

Fig. 38.10. On rare occasions when the transverse transection of the SMAS at a high level does not permit a precise vector to elevate the angle of the mouth, upper nasolabial fold and nasojugal groove, a third flap can be made from the upper portion of the SMAS to move to the desired precise vector needed for elevation. Excellent surgeons use this design for almost all facelift patients

Unfortunately utilization of the SMAS for rejuvenation is not an easy surgical technique. Skill for precise separation of the overlying tissues from the SMAS is essential [4]. This dissection must neither thin the SMAS nor injure the subdermal plexus of arteries and veins. The SMAS is always thick enough to hold sutures unless the dissection thins or removes some of the SMAS while elevating the skin flap. If during the surgical dissection the ability to recognize the SMAS layer and to precisely surgically uncover the intact SMAS is lacking, then some other less efficient technique for deep-layer support must be used [1, 5].

For all except those with only excessive skin, a satisfactory facelift result requires modification of the deep-layer support composed of the SMAS, which includes fascia and the platysma [6–8]. When utilized appropriately, the SMAS will move cheek fat into the eyelid–cheek depression and change the direction of the nasojugal groove from diagonal of old age to horizontal as it was at a younger age (Figs. 38.3, 38.10).

Rotation and posterior–superior cheek SMAS shift can provide support to the cheeks, restore the jowl fat to the youthful cheek contours, eliminate the hanging jowls, flatten nasolabial folds and even form a sling support to the submental area across the midline between the hyoid and chin (Fig.38.5). If the transverse incision of the SMAS is made over the upper part of the zygomatic arch, a very good support to many additional areas is possible. These areas include the orbicularis oculi and orbital septum, nasojugal groove, movement of cheek fat into the depressed lid–cheek junction, the upper nasolabial fold, and exposure of more vermillion of the lateral upper lip. Also, elevation of the angle of the mouth can change a down-in-the-mouth or "fish mouth" to a more pleasant and content appearance [9, 10].

Patients with vertically short platysma muscles or tight bands are treated by muscle interruption and release at the level of the cricoid cartilage. The vertical SMAS incision overlying the parotid is about 1 cm anterior to the ear and continues to become the platysma incision anterior to the sternocleidomastoid muscle. When complete platysma transection is planned, the incision is passed within the approximately 1 cm wide avascular area anterior to the anterior border of the sternocleidomastoid muscle and crosses the neck at the cricoid level. Usually anterior submental platysma muscle invagination is planned. Approximation of the platysma muscle completes the three-vector sling formed by upward cheek-SMAS shift and rotated SMAS flap to mastoid fascia [11].

Bulges in the submental area must be assessed as to bands or sagging platysma muscles, fat, digastric muscles or submandibular glands (Figs. 38.9; 38.11) [12]. As indicated by the anatomical findings, the SMAS sling support is used for sagging platysma muscles, transection for platysma bands, partial excision of fat and submandibular glands and tangential transection of large digastric muscles [13]. The osseocutaneous connections of the mandibular ligament and mental crease should be completely liberated for the SMAS support to extend to the midline of the chin and submental area (Fig. 38.11).

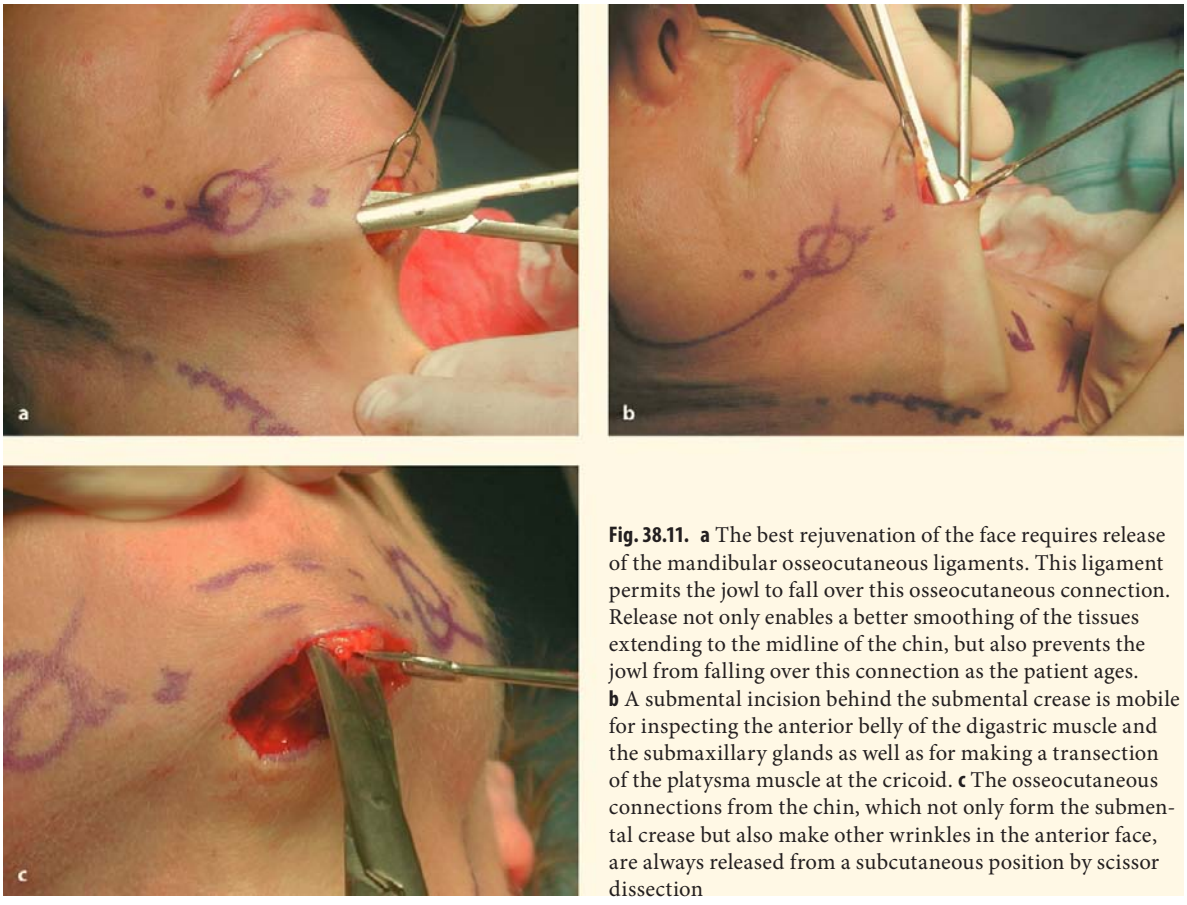

Fig. 38.11. **a** The best rejuvenation of the face requires release of the mandibular osseocutaneous ligaments. This ligament permits the jowl to fall over this osseocutaneous connection. Release not only enables a better smoothing of the tissues extending to the midline of the chin, but also prevents the jowl from falling over this connection as the patient ages. **b** A submental incision behind the submental crease is mobile for inspecting the anterior belly of the digastric muscle and the submaxillary glands as well as for making a transection of the platysma muscle at the cricoid. **c** The osseocutaneous connections from the chin, which not only form the submental crease but also make other wrinkles in the anterior face, are always released from a subcutaneous position by scissor dissection

38.4 Cheek and Neck Exposure of the SMAS

The most common cause of damage to the SMAS or to making the SMAS appear thin is a lack of precision in elevating the skin. If the dissection is not precise, part of the SMAS may be carried upward with the skin flap and the utilization of the SMAS will be limited and then the less efficient method of plication or other techniques may have to be used. This precision and elevation of the skin-cheek without damaging the SMAS is greatly helped by transillumination of the skin; however, for surgical elevation of the skin over the mastoid, direct illumination is preferred because the mastoid fascia is followed and skin is left as thick as possible.

Special technique is required to separate the skin from the SMAS overlying the sternocleidomastoid muscles because of the retaining ligaments connecting the skin to the sternocleidomastoid muscles. These sternocleodomastoid retaining ligaments are thick and run parallel to the muscles. For right-handed persons, the surgeon's body should be shifted while dissecting over the right muscle so that the sharp scissor dissections is parallel to these ligaments, which can be demonstrated by blunt dissection. If the dissection is directed perpendicular to these ligaments, injury to the greater auricular nerve and exposure of raw muscle is very likely.

Skin flaps should be elevated sharply under direct vision, preserving approximately 3 mm of subcutaneous fat. In areas of firm skin attachments, shoving scissors or blunt dissection may be traumatic to the subdermal microcirculation and might produce focal areas of raw dermis or destroyed SMAS.

Preservation of the anterior cheek-SMAS-cutaneous skin supporting ligaments ("fingers") will produce a pleasing effect on the cheek unobtainable by other methods. These variable fascial condensations anchor the SMAS and upper platysma to the dermis of the cheek and provide a means of creating a youthful slight concavity beneath the zygoma. This also results in an attractive enhancement of the malar projection (Figs. 38.1, 38.3).

For utilizing SMAS support for rejuvenation, all patients will benefit from release of the SMAS retaining ligaments at the malar bone, masseteric muscle,

parotid gland and the mandibular ligament [14]. These releases are necessary to obtain the good results seen at surgery by a SMAS posterior shift and upward rotation (Fig. 38.3). A key in the SMAS incision is selecting the malar pivot point upon which the flap will rotate (Fig.38.3). By placing the flap pivot point at the malar eminence, fullness gained during rotation is converted to a significant augmentation of this region; consequently, the need for malar implants is usually eliminated. This point will produce to the high projection and must be chosen individually for each face and each side of the face. It lies about one finger breadth below and lateral to the lateral canthus. Likewise, overlap of the SMAS along the zygomatic arch enhances the skeletal projection. From this malar pivot point, a methylene blue line is drawn laterally over the upper part of the zygoma to a point 1 cm in front of the tragus. This line is turned inferiorly and passed 1 cm in front of the ear. At the tail end of the parotid, the line continues within the avascular muscle 1 cm anterior to the sternocleidomastoid muscle to the level of the cricoid cartilage. If complete platysmal transection is planned, the mark is then passed transversely to join a line of similar design on the opposite side.

When continuing the incision from the tail of the parotid to the anterior border of the sternocleidomastoid, a safety space from the marginal mandibular nerve is maintained by using blunt dissection. This dissection is more precarious and thus tedious with secondary procedures where the anatomy may be distorted. The external jugular vein and the transverse cervical nerves are large and easy to identify. The anterior border of the sternocleidomastoid muscle is relatively avascular and a visible cut edge would blend with the muscle border. By transecting the platysma low in the neck, accentuation of the larynx is avoided and there will be a smooth transition with a concave curve from neck to submental area.

Tracing the SMAS/platysma incision locations with methylene blue insures that each cut edge of the flap will be marked for identification. SMAS scissor incision and dissection over the zygoma is begun just anterior to the ear. Allis clamp traction to elevate and provide tension to the SMAS layer will make dissection safe and easy because scissors will follow the tense plane, leaving the nerve down (Fig. 38.7). The vertical limb SMAS incision is then made in a similar manner. With the assistant stabilizing the SMAS flap with two Allis clamps, we carefully elevate the SMAS flap until the desired result and motion at the upper nasolabial fold, philtrum, outward turning of the lateral vermillion of the upper lip, elevation of the angle of the mouth, elimination of jowls and support to the submental area are achieved (Fig. 38.3). Usually, this does not require an extended dissection across the cheek because most retaining fibers lie just anterior to the zygomaticus major muscle malar attachment.

Once elevated, the posterior edge of the flap is then grasped by three Allis clamps to see which directional shift produces the best facial result. This direction is often posteriorly with a superior rotation about its malar pivot point (Fig. 38.4). The superior SMAS flap margin is sutured to the deep temporal fascia or the superficial temporal fascia. This latter fascia may require fixation to the deep temporal fascia if it appears mobile. The SMAS overlapping augments the zygomatic arch and adds fullness to the temporal concavity, which becomes deeper with aging. This SMAS cheek flap moves thick SMAS over and below the zygomatic arch where a secondary SMAS incision could be made through thick SMAS fibrous tissue. Folding the upper edge of the flap has not been found to be needed to provide thicker fixation tissue or to augment the zygomatic arch and will limit the proper direction shift.

38.5 Occipital SMAS Flap

If there is a need to provide support to the hyoid area or maximum support to submaxillary glands, an occipital transposed cheek SMAS flap may be useful [11]. A flap as wide as possible is made from the posterior margin of the SMAS flap by closure of the donor site before cutting the flap. The donor site closure is made from the posterior margin of the SMAS flap anterior to the tragus of the ear and below the mandibular angle (Fig. 38.12). This SMAS flap is rotated to the mastoid area and sutured in place with the chin-neck angle at 90° so that when the patient looks upward there is no increased tension along the direction of the SMAS flap. When looking downward, there is submental support across to the opposite SMAS flap. The support produced by submental platysmal invagination completes the hammocklike support to the upper part of the neck and submental area. The SMAS flap rotated to the occipital area completes a three-direction support which has increased SMAS tension directed toward the temporal area, toward the occipital area and toward the midline muscle approximation in the submental area. This rotated mastoid SMAS flap produces a wide choice of direction and precision support individualized to each patient's need and avoids shifting of the sternocleidomastoid muscles (Fig. 38.12d).

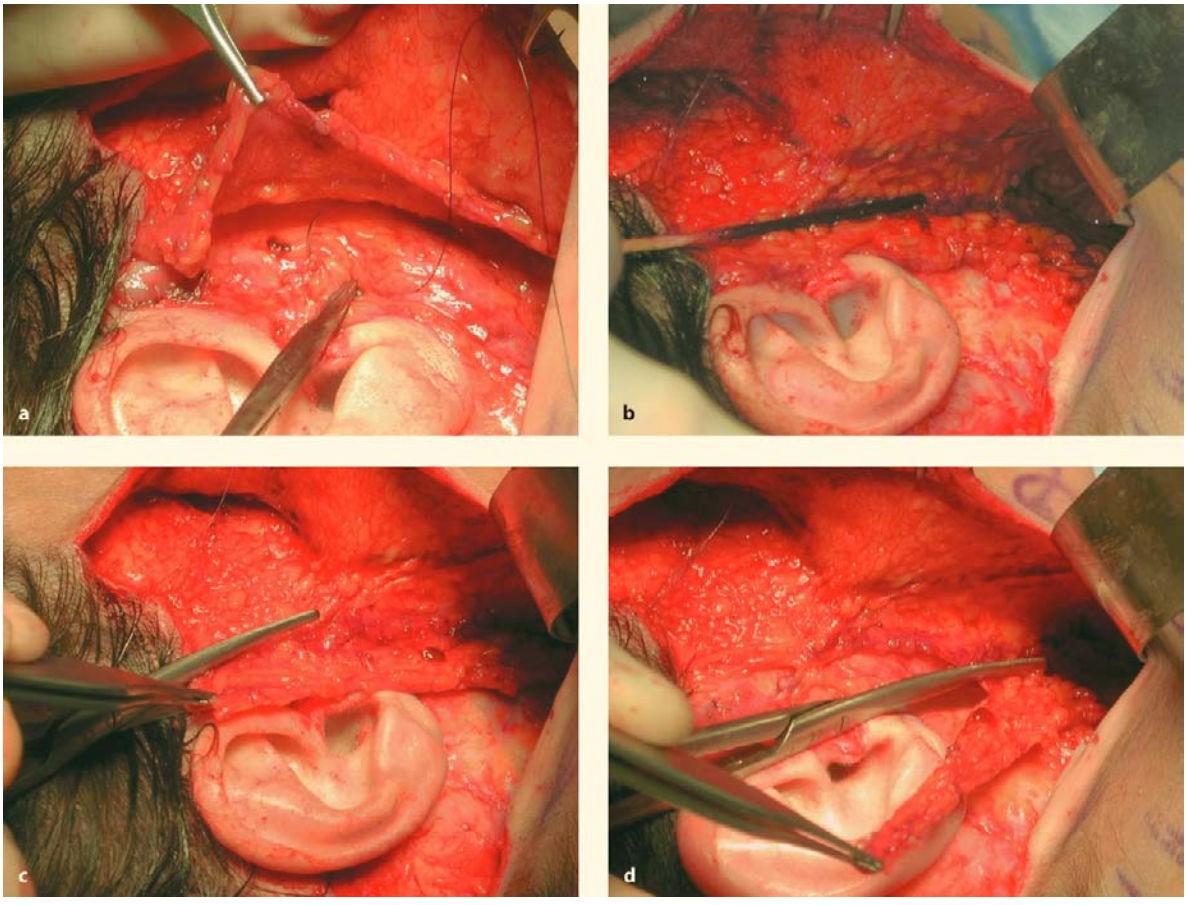

Fig. 38.12. **a** The occipital flap is formed after elevation of the SMAS by closing the donor site before the flap is excised. **b** The flap as outlined by the sutures closing the donor site is marked and then this flap, which is usually 1.5 cm in width, is separated down below the angle of the jaw so that the flap can be rotated underneath the angle of the jaw and sutured to the mastoid fascia. **c** Formation of SMAS flap. **d** Rotation of flap to mastoid fascia

38.6 Platysma Muscle Transection

Appropriate division of the short platysma muscle or platysmal muscle bands at the level of the cricoid is sometimes necessary for a beautiful neck. Wide undermining of the platysma is not necessary because no ligaments exist in the neck to restrain it.

38.7 Suture Closure

The addition of the SMAS/platysmaplasty deep-layer support has made possible precision closure of facelift incisions under minimal tension with no tension at the helix, tragus and earlobe. This produces a great reduction in detectable scars (Fig. 38.9). Nonetheless, attention to detail is the key to a top-quality result.

38.8 Dressings

Once, dressings were thought to prevent edema, seromas and hematomas. Most surgeons now acknowledge this to be not true. Some surgeons claim their dressings provide increased patient comfort and improvements in neck contour. Experience and common sense argue against these convictions.

There are many rational arguments against the use of a facelift dressing. The most obvious of these is the danger in placing pressure on delicate skin flaps. None will reduce edema and most, in fact, create a tourniquet effect, decreasing venous return and contributing to edema. Finally, little about a facelift dressing is comfortable.

38.9 Postoperative Care

Proper postoperative care of the facelift patient will insure the best result with the fewest complications. All patients are discharged to the overnight care of a skilled nurse well versed in the postoperative plan of care. A physician is always available.

All patients return the day after surgery and are carefully examined. The drain is removed if the output is less than 20 ml. Any sutures appearing unduly tight are snipped and left in situ. This avoids tension alopecia but averts annoying bleeding from the stitch hole. All flaps are carefully inspected. Patients are forbidden to hold a book or magazine in their hands, sit up straight without a headrest or lay supine or on their side without the chin–neck angle being more than 90° for 10 days. These activities all result in inadvertent neck flexion. Patients must rely on a second-party observer to remind them to keep the chin elevated since proprioception of the chin–neck angle is lacking. A good position that insures an open cervicomental angle is one in which the patient sits with "elbows on knees." This posture allows reading, writing, eating, TV watching, etc. Any time compromise of the postauricular flap is noted, and a check should be made to insure that a tight closure has not created lateral tension across its base strangling it. If in doubt, offending sutures should be removed without hesitation, as secondary healing is always superior to slough.

Sutures are removed as indicated usually in stages over a period of 6–9 days. Fine sutures are removed from areas of low tension first, usually on postoperative days 3 and 5. Half-buried vertical mattress sutures are removed later over postoperative days 5–10. Sutures in relatively higher tension areas at the sideburn and behind the ear are removed last.

38.10 Complications

Our experience has shown that longer and more extensive facelift procedures have not resulted in an increased rate of complications. Hematomas, the most common complication reported in the literature, are thought to be more common in men. Because our procedures are long and tend to outlast the effect of epinephrine, bleeding is usually discovered and corrected before wound closure. During the past 30 years in our practice only one male patient and no female patient undergoing facelift has been returned to surgery from the recovery room for evacuation of a hematoma.

There have been no zygomatic buccal nerve injuries, one marginal mandibular nerve palsy and one permanent injury to the frontotemporal branch of the facial nerve during this period. Three patients experienced temporary unilateral weakness of the frontalis muscle, but all recovered without residual effects within 12 weeks. Four patients had temporary unilateral weakness of the lower-lip depressor muscle even though we do not require patients to stop smoking.

Skin necrosis is extremely rare and in only five cases has it exceeded 1 cm, all less than 2 cm. We attribute this to precise planning, atraumatic and gentle skin handling, lack of skin tension due to support of the SMAS, and a thoughtful postoperative plan of care including no pressure dressings for all patients.

38.11 Summary

SMAS utilization is of two types: adequate to obtain the best results possible and limited utilization. This concept directs attention to the artistic goal rather than focusing on technique by using terms such as high, low or extended SMAS. If the SMAS is utilized with precision, there can be great periorbital rejuvenation along with decreasing the excessive lower-eyelid skin, supporting the periorbital fat of the lower eyelids, improving smile creases and restoring the nasojugal grove to the horizontal direction of youth from the diagonal direction of the aged appearance along with changing the long oval older appearance of the lower eyelid to a shorter youthful appearance.

For the maximum sling support to the submental neck, the SMAS must be freed from the osseocutaneous restraining ligament at the malar bone and the anterior mandibular jowl border along with release of the restricting connections to the parotid fascia and masseter muscles.

The contour correction in the submental area always gives the appearance of stronger chin projection and release of the submental osseocutaneous ligament permits a great improvement of the ptotic chin appearance.

Occasionally, excision of ptotic chin muscle is indicated. Also at times a chin implant of alloplastic material or injected fat transfer may improve the vertical height of the chin and lower lip as well as being indicated for improving the mandibular angles and jaw line.

A youthful-appearing neck as well as rejuvenation of the upper third of the face is very important for patient satisfaction following a facelift procedure.

References

1. Connell B, Miller SR, Gonzalez-Miramontes H: Skin and SMAS Flaps for Facial Rejuvenation. In: Guyuron B, (ed) Plastic Surgery: Indications, Operations, and Outcomes. St. Louis, Mosby; 2000:2583–2607.
2. Connell BF: Facial Rejuvenation. In Brent B, (ed) The Artistry of Reconstructive Surgery. St. Louis: Mosby; 1987:365–381.
3. Ristow B: Milestones in the Evolution of Facelift Techniques. In Grotting JC, (ed). Reoperative Aesthetic and Reconstructive Plastic Surgery. St. Louis: Quality Medical Publishing; 1995:191.
4. Stuzin JM, Baker TJ, Gordon HL: The Relationship of Superficial and Deep Fascia Fascias Relevance to Rhytidectomy and Aging. Plast Reconstr Surg 1992;89:3.
5. Connell BF, Marten TJ: Facelift. In Cohen M, (ed) Mastery in Plastic Surgery. Boston: Little, Brown & Co.; 1994:1873–1902.
6. Guerrerosantos J: The Role of the Platysma Muscle in Rhytidoplasty. Clin Plast Surg 1983;10:449.
7. Guyuron B: Problem Neck, Hyoid Bone and Submental Myotomy. Plast Reconstr Surg 1992;90:830.
8. Hamra ST: The Deep Plane Rhytidectomy. Plast Reconstr Surg 1990;86:53.
9. Connell BF, Marten TJ: Deep Layer Technique in Cervicofacial Rejuvenation. In Psillakis J, (ed) Deep Facelifting Techniques. New York: Thieme; 1994:161–190.
10. Connell BF, Marten TJ: Surgical Correction of Crow's Feet. Clin Plast Surg 1993;20:295.
11. Connell BF, Semlacher RA: Contemporary Deep Layer Facial Rejuvenation. Plast Reconstr Surg 1997;100(G):1513–1523.
12. Connell BF, Shamoun JM: The Significance of Digastric Muscle Contouring for Rejuvenation of the Submental Area of the Face. Plast Reconstr Surg 1997;99(6):1886–1950.
13. Connell BF, Hosn W: Importance of the Digastric Muscle in Cervical Contouring: An Update. Aesthetic Surg J 2000;20:12–16.
14. Furnas D: The Retaining Ligaments of the Cheek. Plast Reconst Surg 1987;11:163.