

# Arthroscopic Wrist Anatomy

Jonathan H. Lee, Nathan L. Taylor, Ryan A. Beekman,  
and Melvin P. Rosenwasser

**W**rist arthroscopy allows excellent visualization of the articular surfaces of the carpal bones and ligaments that is not possible via an open arthrotomy.<sup>1</sup> Arthroscopy of the wrist is now a primary method of evaluating and treating many intra-articular wrist conditions, including triangular fibrocartilage complex tears, chondral injuries, distal radius fractures, carpal fractures, wrist ligament injuries, loose bodies, and ganglia (Table 2.1).<sup>2</sup> A thorough knowledge of overall wrist anatomy, including topographic landmarks, extracapsular tendon and neurovascular structures, and intracapsular ligamentous and osseous structures is essential to proper diagnosis and treatment.<sup>3</sup> Chapter 1 outlined the basic setup and surface topography of the wrist joint, as well as the creation of the standard radiocarpal and midcarpal portals. This chapter will focus on the internal anatomy of the radiocarpal, midcarpal, distal radioulnar joint, and thumb carpometacarpal joint.

A thorough understanding of the topographic anatomy of the wrist and appropriate portal placement greatly influences the surgeon's view of internal anatomy.<sup>4</sup> We must emphasize that all external anatomical landmarks and all portals must be marked after traction is applied but before starting the arthroscopic procedure. Important points to remember when creating the portals include (1) proper portal placement by careful palpation of the surrounding tendinous and bony landmarks, (2) incision only through the skin, and (3) blunt dissection to the capsule. To avoid iatrogenic cartilage injuries when entering the joint, the capsule should be distended by insufflating the joint with saline, and only blunt instruments should be used to pierce the capsule.<sup>4</sup> This technique can also provide some information on intercarpal ligamentous integrity if the fluid does not leak out of its respective compartment.

A systematic approach must be used when performing wrist arthroscopy to avoid missing any pathology and to properly view normal anatomy.<sup>1</sup> Certainly the order of visualizing structures is not critical, but one should develop a consistent pattern to avoid overlooking subtle abnormalities. Another important practice in wrist arthroscopy is switching

viewing portals to visualize all structures from various angles. More than one viewing portal is always necessary during wrist arthroscopy. In contrast to knee and shoulder arthroscopy, there is an almost complete absence of in-and-out movement of the arthroscope when performing wrist arthroscopy. The inexperienced surgeon often makes the mistake of inserting the arthroscope too far so that the tip is against the volar capsule or of pulling the arthroscope back too much so that it is no longer in the joint. Because the anterior-posterior depth of the wrist joint is small, the arthroscope can only be moved in or out by approximately 1.5 cm. Pressurized saline irrigation maintains excellent viewing, especially through the small inflow available with wrist arthroscopes.

## RADIOCARPAL ARTHROSCOPIC ANATOMY

In general, make the first portal away from the site of major symptoms to ensure that any pathology encountered will be untainted by portal entry injury. All portals are first checked with an 18-gauge needle to correctly determine angle of insertion and adequacy of traction. The 3-4 portal is created first and is usually the main viewing portal. The 4-5 portal is created next for instrumentation. The inflow tubing is attached to the arthroscope sheath to keep soft tissue away from the viewing field. Outflow is then created through the 6-U portal. This is done after the 6-U region is palpated from outside while viewing the prestyloid recess arthroscopically to confirm proper location.

The articular surfaces of the scaphoid and lunate, as well as the intervening scapholunate interosseous ligament are first visualized by rotating the field of view of the arthroscope to look distally (Figure 2.1). Be careful to maintain perspective with a visible horizon such as the distal radius and proximal carpal row. The volar and dorsal margins of the articular surfaces of the two bones can be inspected by flexing and extending the wrist slightly. The proximal articular surface of the lunate has two distinct segments. The lateral portion articulates with the lunate fossa of the

TABLE 2.1. Arthroscopic Portals for Various Diagnoses.

Diagnosis	Primary portals		Secondary portals		Treatment
	Viewing	Instrumenting	Viewing	Instrumenting	
Dorsal ligament injury/ganglion	1-2	3-4	6-R		Debride, excise
Radial styloiditis	3-4	1-2	1-2	3-4	Debride
Intra-articular distal radius fracture	3-4	4-5	4-5	3-4	Arthroscopically assisted reduction/pinning
Scaphoid fracture	3-4	1-2	1-2 RMC	3-4	Arthroscopically assisted reduction/fixation
Acute scapholunate ligament injury	3-4	4-5	4-5 RMC	3-4	Inspect/probe, debride, internal fixation
Volar radiocarpal ligament injury	3-4	4-5	—	—	Inspect/probe
Lunotriquetral ligament injury	4-5	6-U	6-U UMC	4-5	Inspect/probe, debride, internal fixation, ulnar shortening
TFCC tear					
Class IA	4-5	6-U	6-U	4-5	Debride
Class IB	6-U	4-5	—	—	Repair
Class IC	4-5	6-U	6-U	4-5	Debride
Class ID	6-U	3-4	6-U	3-4	Debride, repair
STT joint pain	RMC	STT	—	—	Inspect for staging, debride, fixation
Midcarpal pain	RMC	UMC	—	—	Inspect/probe, debride
DRUJ pain	DRUJ	DRUJ	—	—	Inspect, debride
Ulnar impaction syndrome	DRUJ	DRUJ	—	—	1. TFCC injury: Ulnar shortening 2. No TFCC injury: DRUJ arthroscopy
CMC arthritis/fracture	TM (CMC) volar	TM (CMC) dorsal	TM (CMC) dorsal	TM (CMC) volar	Synovectomy, debridement, removal of loose bodies
Dorsal capsule contracture	Volar radial	Any dorsal port	—	—	Dorsal capsulotomy, inspect S-L volar ligament

distal radius, and the medial portion articulates with the triangular fibrocartilage complex (TFCC). The surface of the scaphoid can be followed radially up the wrist, at which point capsular attachments prevent further visualization. The articular cartilage should be off-white and smooth and should feel firm on palpation with a probe. Cartilage softening, fragmentation, or fissuring indicate chondromalacia and should be graded and recorded. The scapholunate interosseous ligament may not be immediately obvious in some cases because it has the appearance of cartilage. It can

appear as a localized valley in an otherwise smooth cartilaginous surface. The location of the ligament is confirmed by palpating it with the probe, because the ligament is softer than the surrounding cartilage. The ligament has three distinct segments: (1) dorsal, (2) proximal or membranous, and (3) volar. Probing may also show tears that were not noticed initially (Figure 2.2). Partial tears often involve the proximal aspect of the ligament because it is fibrocartilaginous,

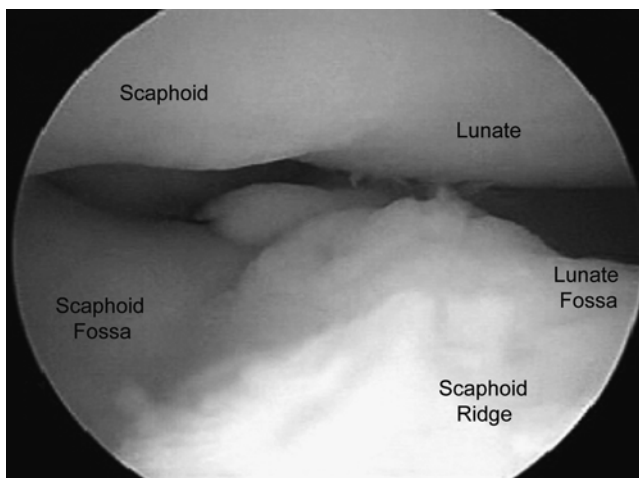


FIGURE 2.1. The 3-4 portal allows excellent visualization of the scapholunate ligament as well as the scaphoid and lunate fossae seen here.

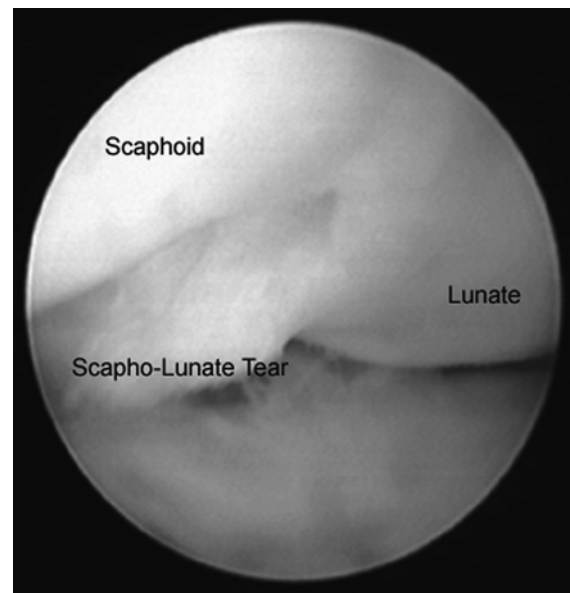


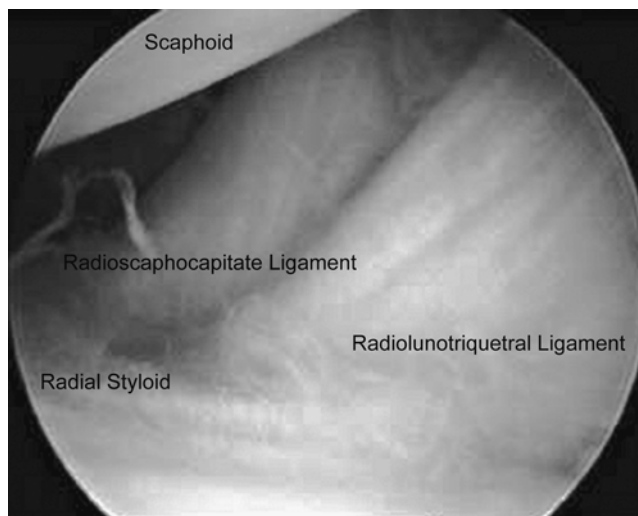
FIGURE 2.2. Obvious disruption of the scapholunate ligament.

unlike the dorsal and palmar aspects of the ligament.<sup>5</sup> It is impossible to fully visualize the volar aspect of the scapholunate ligament arthroscopically, but the membranous (proximal) and dorsal portions can be seen in their entirety.

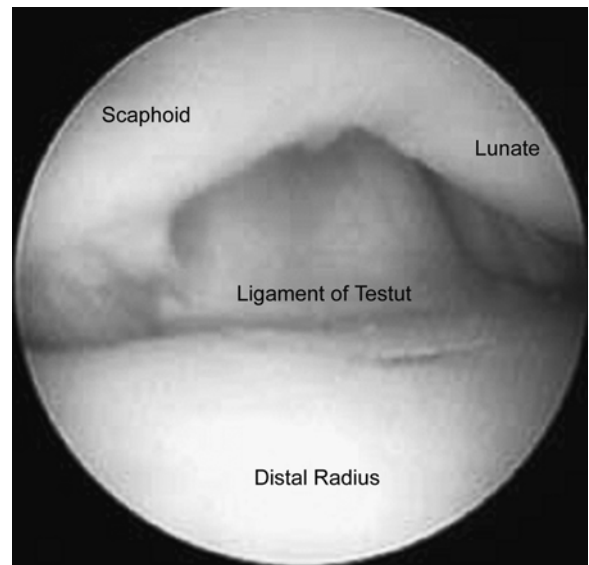
The arthroscope is then rotated proximally, showing the lunate and scaphoid fossae of the distal radius (Figure 2.1). The two fossae are separated by a sagittal ridge. The scaphoid fossa can be followed radially up to the radial styloid (Figure 2.3). Air bubbles that obscure the view are frequently found in this region, because it is the highest portion of the radiocarpal joint with the forearm in the vertical position. Placing an egress needle here facilitates egress of bubbles.

The volar carpal ligaments are evaluated next and consist of the radioscaphocapitate (RSC), radiolunotriquetral (RLT), and radioscapholunate (RSL) ligaments. The latter two are also known as the long radiolunate (LRL) and short radiolunate (SRL) (Figure 2.3).<sup>6</sup> The RSC ligament is the most radial, arising from the radial styloid process and inserting onto the waist of the scaphoid as well as progressing distally to the capitate.<sup>7</sup> The orientation of the fibers is not longitudinal but oblique in the ulnar direction.<sup>8,9</sup> The ligament should feel taut on palpation with a probe because traction is being applied to the wrist.

The RLT ligament is just ulnar to the RSC ligament and is slightly broader and more obliquely oriented.<sup>8</sup> The ligament is also referred to as the radiolunate ligament because many question the importance of the lunotriquetral portion.<sup>10,11</sup> The RLT and RSC ligaments are separated by an interligamentous sulcus, which provides a useful arthroscopic landmark. The ulnar portion of the ligament may be covered with a synovial tuft, which originates from the radioscapholunate ligament.



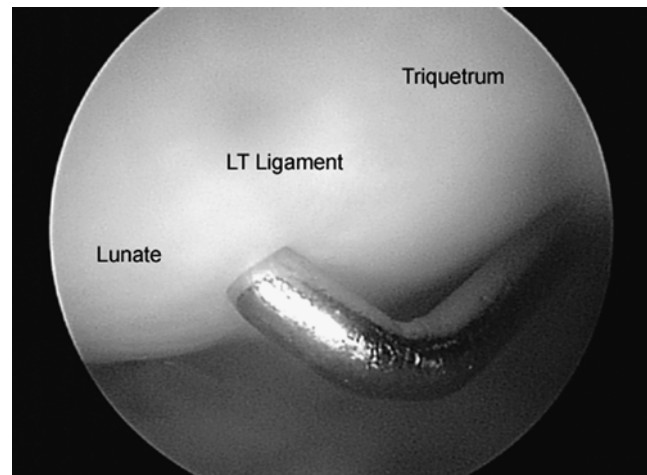
**FIGURE 2.3.** The radioscaphocapitate originating from the radial styloid lies just radial to the radiolunotriquetral ligament also known as the long radiolunate ligament.



**FIGURE 2.4.** The ligament of Testut (radioscapholunate ligament) is a vestigial neurovascular structure just radial to the scapholunate ligament.

The radioscapholunate ligament (ligament of Testut) is visualized with the arthroscope pointed directly volar (Figure 2.4). The ligament can be identified by a synovial tuft covering a portion of it. There is a natural redundancy to the ligament that should not be mistaken for a tear. The fibers of the ligament course slightly in a radial direction and form a 60- to 80-degree angle to that of the RL ligament. The structure is weak and considered to be more of a neurovascular connection to the scaphoid and lunate rather than a ligament.<sup>12</sup>

The arthroscope is again directed at the articular surface of the lunate, which is then followed ulnarly to the triquetrum to view the lunotriquetral (LT) interosseous ligament (Figure 2.5). Deviating the wrist ulnarly can help in visualizing the triquetrum, but oc-



**FIGURE 2.5.** Concave surface of the lunotriquetral ligament is noted between the lunate and the triquetrum.

asionally the arthroscope must be moved to a more ulnar portal to see the triquetrum well. The lunotriquetral interosseous ligament is often more difficult to detect than the scapholunate interosseous ligament. There may again be a small valley at the site of the LT ligament, but probing the ligament is the best way to localize it.

The arthroscope is then rotated proximally to view the TFCC (Figure 2.6). The TFCC consists of the triangular fibrocartilage (TFC) or articular disk, the dorsal and palmar distal radioulnar ligaments, the floor of the extensor carpi ulnaris (ECU) sheath, and ulnocarpal ligaments. The TFC is wedge-shaped in the coronal plane with an ulnar base that is attached to the styloid process and a radial tip that merges with the articular surface of the distal radius. The junction between the TFCC and the distal radius can be difficult to visualize. In some cases, there may be a color change or crease at the junction. Palpation with a probe will show the junction with a change from the firm resistance of the lunate fossa to the softer resilience of the articular disk of the TFCC.<sup>11</sup> The resilient “trampoline” of the TFC on palpation (Figure 2.7) is an important finding because it indicates that the supporting structures are intact.<sup>13</sup> With a significant tear of the TFCC, this resilience is lost, and the TFC becomes soft and compliant with bulging in the middle.

Tears of the central avascular portion of the TFCC are common, particularly in older patients.<sup>14</sup> Ordinarily the ulnar head is not visible from the radiocarpal joint, but with a full-thickness tear of the TFCC, the ulnar head can be visualized through it (Figure 2.8). Congenital perforations of the central region are occasionally observed.<sup>15</sup> Also a ballooning bucket-handle tear may obscure visibility here. Always use the probe to ascertain if a cleavage tear is present.

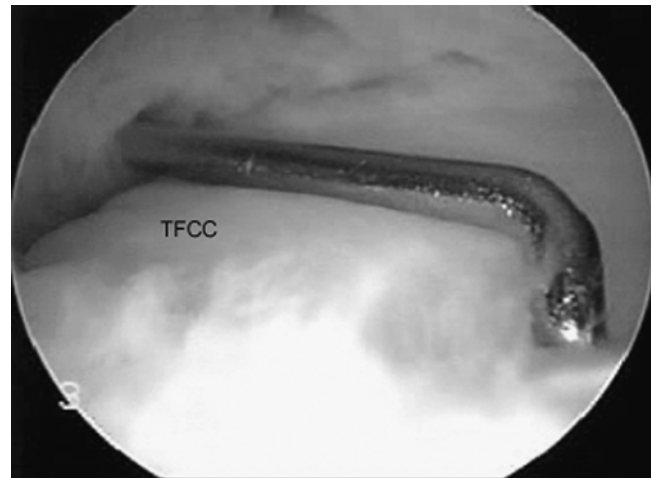


FIGURE 2.7. TFC trampoline effect.

The periphery of the TFCC should be examined and probed as well. The peripheral 15% to 20% of the TFCC is vascularized and therefore has healing potential if torn. The dorsal and palmar radioulnar ligaments are thickenings of the periphery of the TFCC and attach to the ulnar styloid and distal radius.<sup>16</sup> One has to differentiate deep radioulnar ligaments attaching to the fovea from superficial ones attaching to the styloid. Only foveal ligaments are seen. The palmar radioulnar ligament is taut in pronation, and the dorsal margin becomes taut in supination. The prestyloid recess (Figure 2.9) is located volar to the ulnar styloid and is a synovium-lined pocket that can be confused with a TFCC tear. It can also lead to confusion with imaging modalities because the recess fills with contrast in arthrography, and in wrists with effusions can appear as a bright signal on T2-weighted MRI. As noted earlier, the 6-U portal enters the joint above the

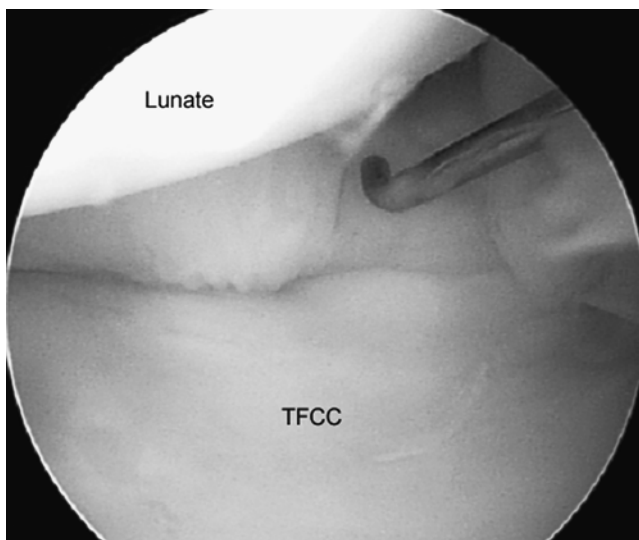


FIGURE 2.6. The normal smooth articular surface of the TFC.

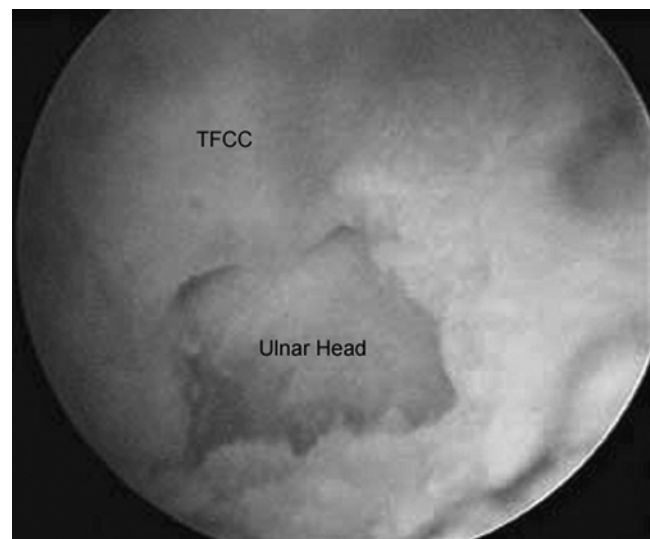
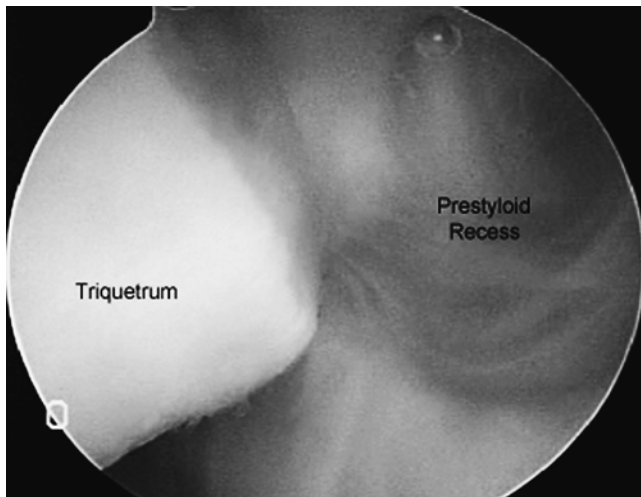


FIGURE 2.8. Central disruption of the TFC with ulnar head protrusion.





**FIGURE 2.9.** Prestyloid recess with adjoining articular surface of triquetrum and insertion of TFC.

prestyloid recess, and the surgeon must be certain that this is above the TFC articular disk.

The ulnocarpal ligaments (Figure 2.10) consist of the ulnolunate and ulnotriquetral ligaments. They both originate from the ulnar styloid, where they blend together with fibers of the TFCC.<sup>15</sup> They pass volar to the palmar distal radioulnar ligament and insert on the volar surfaces of the lunate and triquetrum, respectively. They limit wrist extension and radial deviation. These ligaments should be palpated with a probe to ensure their competence. It should be noted that the lunotriquetral interosseous ligament can be located by following distally the interval between the ulnolunate and ulnotriquetral ligaments.

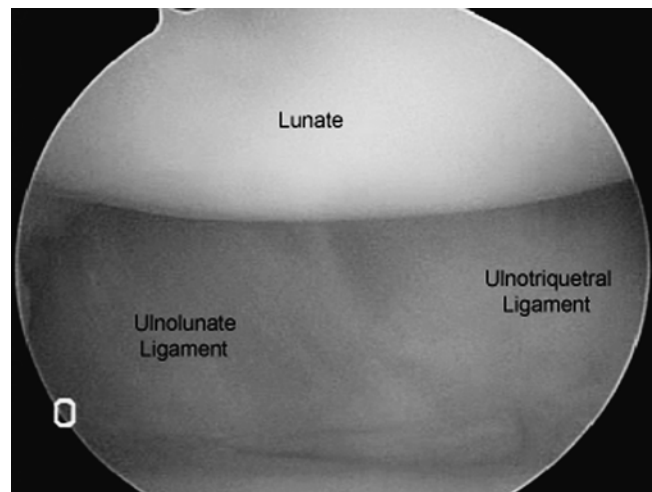
The floor of the ECU sheath and the dorsal ulnotriquetral ligament are strong structures on the dorsal aspect of the TFCC. They are often covered with synovial tissue and therefore not immediately visualized arthroscopically. The synovial tissue should be removed and the structures inspected and followed along their course in patients with dorsoulnar wrist symptoms, because injuries are frequently seen, such as partial tears with surrounding synovitis.

When indicated, a new volar radial (V-R) portal can be used for specific indications such as viewing the dorsal capsule and palmar scapholunate (SL) ligament.<sup>17</sup> This may allow safer dorsal capsulotomies, assessment of scapholunate injuries, and perhaps volar carpal ganglionectomies. Slutsky recommends creating this portal from outside-in for any patient with radial-sided wrist pain.<sup>18</sup> The V-R portal can also be created from inside-out as described by Tham.<sup>19</sup> While viewing through the V-R portal and instrumenting the standard dorsal portals, a dorsal capsulotomy or bony debridement can be performed for dorsal capsule contracture or impingement.

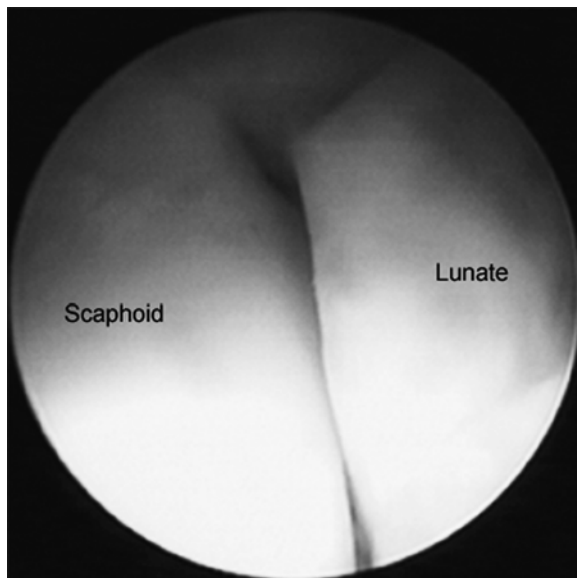
## MIDCARPAL ARTHROSCOPIC ANATOMY

The midcarpal joint is initially distended with 2 to 3 cc of saline injected through the radial midcarpal (RMC) portal to begin midcarpal arthroscopy. The depth of the midcarpal joint is less than half that of the radiocarpal joint, and great care must be taken when entering the joint. One must also be careful when creating this portal, because the space is tight and it is easy to create a furrow in the capitate.<sup>20</sup> Thus always triangulate this space with an 18-gauge needle prior to placing the blunt trocar. Sharp trocars should never be utilized in wrist arthroscopy. The ulnar midcarpal portal is created as well, for instrumentation and visualization of the ulnar portion of the midcarpal joint. The midcarpal joint space is smaller than that of the radiocarpal joint, and occasionally a smaller arthroscope is beneficial.<sup>21</sup>

The scaphocapitate joint is viewed through the radial midcarpal portal (Figure 2.11).<sup>22</sup> However, it is easiest to get one's orientation by visualizing the scapholunate joint ulnar to the insertion point of the arthroscope. One should first see the head of the capitate and the well-defined normal cleft between the scaphoid and lunate. This must always be probed through the companion ulnar midcarpal portal. The scapholunate interosseous ligament is present on the palmar, proximal, and dorsal edges but not the distal edge of the scapholunate joint; therefore, midcarpal arthroscopy usually gives the best view within the scapholunate joint. Marginal degenerative changes without an obvious static scapholunate dissociation may indicate a dynamic instability.<sup>11</sup> A fibrocartilaginous meniscus may extend into the joint from the membranous regions of the interosseous ligament. Intraoperatively, the stability of the joint can be assessed



**FIGURE 2.10.** Ulnolunate ligament lies just radial to the ulnotriquetral ligament, both running in an ulnar to radial direction.



**FIGURE 2.11.** The radial midcarpal portal allows visualization of scaphoid and lunate pathology. The ulnar midcarpal portal (not shown) offers views of the lunate and triquetrum.

by performing the “scaphoid shift test.”<sup>23</sup> While visualizing the joint arthroscopically, do not forget to move the wrist in the traction tower to provoke provocative stress when examining the scapholunate ligament.

The arthroscope is then brought back to the scaphocapitate joint. The articular surface of the capitate is convex, whereas that of the scaphoid is concave. If the arthroscope is advanced volarly, the scaphocapitate ligament can be seen. This ligament originates from the scaphoid tubercle and inserts onto the palmar aspect of the capitate.

The arthroscope is then brought distally along the scaphocapitate joint. The edge of the capitate-trapezoid joint can be seen. The arthroscope is further advanced over the scaphoid to enter the scapho-trapeziotrapezoidal (STT) joint. The trapezoid appears closer to the camera than the trapezium. Significant degenerative changes can be seen in the STT joint.<sup>24</sup> It is sometimes possible to see the palmar scapho-trapezoidal ligament on advancing the arthroscope volarly. This ligament is a strong structure reinforced by the flexor carpi radialis tendon sheath.<sup>5,24</sup> Bubbles tend to collect in this joint because it is higher than the RMC portal when the arm is held vertically in the traction device. If need be, the bubbles can be removed with a hypodermic needle placed through the STT portal.

The STT portal, located just ulnar to the extensor pollicis longus in line with the radial side of the second metacarpal, is utilized primarily for instrumentation of the STT joint. Located between the distal pole of the scaphoid, trapezium, and trapezoid, this portal can be created for better visualization or for instrumentation. When utilizing the radial midcarpal portal and visualizing the STT joint, evacuating bubbles with a needle inserted via the STT portal can be very beneficial.

The lunocapitate surface is then inspected and followed ulnarly. The distal ulnar aspect of the lunate should be evaluated for the presence of a medial facet. This facet, which articulates with the hamate, is present in approximately two-thirds of cases and is associated with degenerative changes of the hamate articular surface. In wrists with a medial facet of the lunate, the proximal articular surfaces of the capitate and hamate tends to form a biconvex curve, whereas in wrists with only a single facet on the lunate, the capitate and hamate generally form a single convex curve.<sup>25</sup> The arthroscope is then advanced further ulnarly and rotated proximally to view the lunotriquetral joint. It is possible to peer into this joint as with the scapholunate joint. A fibrocartilaginous meniscus may be present in this joint as well. A ballottement test can be performed while visualizing the joint to assess for instability.<sup>11,26</sup>

Rotating the arthroscope ulnarly shows the saddle-shaped triquetrohamate joint. Ordinarily the joint is held tightly by the volar triquetrohamate and triquetrocapitate ligaments.<sup>24</sup> Midcarpal laxity may be present if one can see across the joint to the volar capsule.

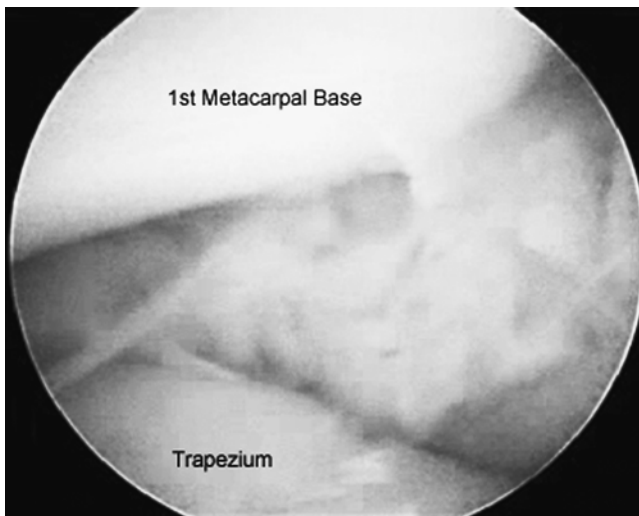## FIRST CARPOMETACARPAL JOINT ARTHROSCOPIC ANATOMY

Arthroscopic evaluation of the first carpometacarpal joint can be utilized in any instance where direct visualization of the first CMC intra-articular anatomy is desired and is a viable alternative to open arthrotomy. To date, the primary indication has been in osteoarthritis, but authors have advocated it both for the early treatment and partial resection of the trapezium, and for interpositional arthroplasty.<sup>27,28</sup>

After a 1.9-mm arthroscope has been inserted in either the 1-R (radial) or 1-U (ulnar) portal, most of the articular surface of the trapezium and the base of the first metacarpal articular surface can be visualized. With appropriate traction and anatomy, a 2.7-mm scope can be safely placed (Figure 2.12). The far lateral capsule and articular surfaces may be difficult to visualize from either portal. The 1-R (radial) portal allows visualization of the dorsoradial ligament (DRL), the posterior oblique ligament (POL), and the ulnar collateral ligament (UCL), while the 1-U (ulnar) portal provides for optimal viewing of the radial collateral ligament (RCL) and the anterior oblique ligament (AOL).<sup>29</sup>

## DISTAL RADIOULNAR JOINT (DRUJ) ARTHROSCOPIC ANATOMY

Indications for diagnostic DRUJ arthroscopy include distal radius fracture involving the DRUJ; articular cartilage injury; partial-thickness, proximal-sided TFCC tear; and capsular contraction resulting in limitation



**FIGURE 2.12.** The 1-U (utilized here) or the 1-R portal allows visualization of most of the carpometacarpal articular surface and capsule.

of forearm rotation.<sup>30</sup> Therapeutic uses of DRUJ arthroscopy include arthroscopic distal ulnar resection for ulnocarpal abutment, removal of loose bodies, and synovectomy.<sup>31</sup> Arthroscopy of the DRUJ is more difficult than that of the radiocarpal or midcarpal joints because of the limited space. Occasionally, the 2.7-mm arthroscope cannot be inserted into the DRUJ, and a smaller arthroscope is required. In some wrists, however, it may be impossible to enter the joint even with a 1.9-mm arthroscope. Again, it is important to triangulate the entry portals with 18-gauge needles first. In these cases, one should abort the procedure or perform an arthrotomy instead rather than continue to struggle and risk iatrogenic injuries to the joint or surrounding soft tissue.

DRUJ arthroscopy is carried out with the forearm held vertically in the wrist traction device as in radiocarpal and midcarpal arthroscopy, but without any traction applied. After the joint is localized with the wrist in supination, 3 mL of saline are injected into it. A longitudinal incision is then made through the skin approximately 5 mm proximal to the proximal portion of the joint. After the soft tissue is spread down to the capsule with a hemostat, the arthroscopic sleeve with a blunt obturator is angled slightly distally and placed into the joint. If required, outflow can also be created by placing an 18-gauge needle into the distal portion of the joint. The sigmoid notch of the distal radius and the articular surface of the distal ulna are immediately seen through the arthroscope. Forearm rotation allows visualization of more of the distal ulna joint surface. Advancing the arthroscope distally allows inspection and brings the undersurface of the TFCC and dorsal and palmar radioulnar capsular ligaments into view. This is useful for lysis of adhesions, marginal debridement chondroplasty, exostectomy, or capsulotomy of the distal radioulnar joint.

## CONCLUSION

Arthroscopic wrist anatomy is best learned from cadaveric bioskills first, and reinforced through experience. Correlating focal clinical findings with arthroscopic anatomy, both normal and pathologic, can expand the clinician's understanding and nuanced-interpretation of presenting complaints. Wrist arthroscopy has been shown to be more effective and predictable than all but the most sophisticated MRI and has an added benefit of real-time assessment of dynamic instability and partial cartilage lesions. Visualizing wrist pathology with the arthroscope is often more reliable than a physical examination or imaging studies such as MRI, arthrography, or plain radiographs. It is essential to alternate viewing and instrumentation portals to properly view normal and abnormal anatomy from various angles. Once arthroscopic wrist anatomy is understood and mastered, the surgeon can best plan and perform treatment based on the patient's internal wrist pathology.

## References

1. Miyasaka KaR, MP. Diagnostic wrist arthroscopy. *Oper Tech Sports Med* 1998;6(1):42–51.
2. Geissler WB, Freeland AE, Weiss AP, et al. Techniques of wrist arthroscopy. *J Bone Joint Surg* 1999;81A:1184–1197.
3. Culp R. Wrist and hand arthroscopy. *Hand Clin* 1999;15:393–535.
4. Grechenig W, Peicha G, Fellingner M, et al. Anatomical and safety considerations in establishing portals used for wrist arthroscopy. *Clin Anat* 1999;12(3):179–185.
5. Bettinger PC, Cooney WP 3rd, Berger RA. Arthroscopic anatomy of the wrist. *Orthop Clin North Am* 1995;26(4):707–719.
6. North ER, Thomas S. An anatomic guide for arthroscopic visualization of the wrist capsular ligaments. *J Hand Surg Am* 1988;13(6):815–822.
7. Berger RA. Arthroscopic anatomy of the wrist and distal radioulnar joint. *Hand Clin* 1999;15(3):393–413, vii.
8. Stanley JSP. *Wrist Arthroscopy*. Philadelphia: Saunders, 1994.
9. Whipple TL, Cooney WP 3rd, Osterman AL, et al. Wrist arthroscopy. *Instr Course Lect* 1995;44:139–145.
10. Berger RA, Landsmeer JM. The palmar radiocarpal ligaments: a study of adult and fetal human wrist joints. *J Hand Surg Am* 1990;15(6):847–854.
11. Whipple TL. *Arthroscopic Surgery: The Wrist*. Philadelphia: Lippincott Williams & Wilkins, 1992:55–90.
12. Berger RA, Kauer JM, Landsmeer JM. The radioscapholunate ligament: a gross anatomic and histologic study of fetal and adult wrists. *J Bone Joint Surg* 1991;16:350–355.
13. Osterman AL, Terrill RG. Arthroscopic treatment of TFCC lesions. *Hand Clin* 1991;7:277–281.
14. Mikic Z. Age changes in the triangular fibrocartilage of the wrist. *J Anat* 1978;126:367–384.
15. Bowers W. The distal radioulnar joint. In: Green DP, (ed.) *Operative Hand Surgery*; 3rd ed. New York: Churchill Livingstone, 1993.
16. Kleinman WB, Graham TJ. The distal radioulnar joint capsule: clinical anatomy and role in posttraumatic limitation of forearm rotation. *J Hand Surg Am* 1998;23(4):588–599.
17. Abe Y, Doi K, Hattori Y, et al. A benefit of the volar approach for wrist arthroscopy. *Arthroscopy* 2003;19(4):440–445.
18. Slutsky DJ. Wrist arthroscopy through a volar radial portal. *Arthroscopy* 2002;18(6):624–630.

19. Tham S, Coleman S, Gilpin D. An anterior portal for wrist arthroscopy. Anatomical study and case reports. *J Hand Surg Br* 1999;24(4):445-447.
20. Hanker GJ. Diagnostic and operative arthroscopy of the wrist. *Clin Orthop* 1991;263:165-174.
21. Botte MJ, Cooney WP, Linscheid RL. Arthroscopy of the wrist: anatomy and technique. *J Hand Surg Am* 1989;14A:313-316.
22. Hofmeister EP, Dao KD, Glowacki KA. The role of midcarpal arthroscopy in the diagnosis of disorders of the wrist. *J Hand Surg Am* 2001;26(3):407-414.
23. Watson HK, Ashmead D IV, Makhlof MV. Examination of the scaphoid. *J Hand Surg Am* 1988;13A:657-660.
24. Viegas SF. Midcarpal arthroscopy: anatomy and portals. *Hand Clin* 1994;10:577-587.
25. Viegas SF, Wagner K, Patterson R, et al. Medial (hamate) facet of the lunate. *J Hand Surg Am* 1990;15A:564-571.
26. Reagan DS, Linscheid RL, Dobyns JH. Lunotriquetral sprains. *J Hand Surg Am* 1984;9A:502-514.
27. Menon J. Arthroscopic management of trapeziometacarpal joint arthritis of the thumb. *Arthroscopy* 1996;12(5):581-587.
28. Berger RA. A technique for arthroscopic evaluation of the first carpometacarpal joint. *J Hand Surg Am* 1997;22(6):1077-1080.
29. Bettinger PC, Berger RA. Functional ligamentous anatomy of the trapezium and trapeziometacarpal joint (gross and arthroscopic). *Hand Clin* 2001;17(2):151-168, vii.
30. Zelouf DS, Bowers WH. Arthroscopy of the distal radioulnar joint. *Hand Clin* 1999;15(3):475-477, ix.
31. Whipple TL. Arthroscopy of the distal radioulnar joint. Indications, portals, and anatomy. *Hand Clin* 1994;10(4):589-592.