Intestinal Obstruction

4

Jae Hoon Lim

CONTENTS

4.1 Introduction

The diagnosis of bowel obstruction used to be made by means of clinical history, physical examination, and plain abdominal radiography; however, abdominal radiographs are not confirmatory or are even confusing, and the cause of obstruction is rarely detected. For the management issue of whether to initiate immediate surgical intervention or to recommend a trial of conservative management, it is mandatory to identify the cause of bowel obstruction. Barium studies are not always satisfactory (Herlinger and Maglinte 1989; Mucha 1987; Dunn et al. 1984). Computed tomography (CT) has been shown to be useful in revealing the level and cause of obstruction (Megibow et al. 1991; Taourel et al. 1995), and recently, multidetector CT scanning has been proven to be very useful (Sinha and Verma 2005a; Sinha and Verma 2005b). Furthermore, multiplanar reformatted imaging may help identify the site, level, and cause of obstruction, and to increase diagnostic confidence (Furukawa et al. 2001) when axial CT findings are indeterminate; therefore, multidetector CT is becoming the first-line diagnostic method in the diagnosis of bowel obstruction (Patak et al. 2005).

Sonography is not considered helpful in most patients with intestinal obstruction. This is easily appreciated if one remembers that the presence of abundant gas in the intestinal tract prevents satisfactory examination of the abdomen, and that adhesions, the most common cause of intestinal obstruction, are not visible on a sonogram (Wilson 1991); however, when the obstructed bowel segments are dilated and filled with fluid, the dilated segments of the bowel loops are well demonstrated and the cause of obstruction can be demonstrated by sonography using the fluid-filled bowel as a sonic window (Fig. 4.1). Judicious use of sonography in evaluating patients with bowel obstruction may be helpful in confirming the presence of obstruction, in determining the level of obstruction, and in identifying of the cause of obstruction (Ko et al. 1993a).

The use of sonography in the era of multi-detector CT scanning is controversial. A CT diagnosis of intestinal obstruction has a decided advantage in terms of accuracy in diagnosis of bowel obstruction and in demonstration of the cause. Furthermore, interpretation of multi-detector CT images is not as operator dependent as sonography; however, sonography is much more widely available than multi-detector CT, much cheaper, and there is no radiation hazard; therefore, sonographic examination may be attempted in patients with normal plain radiographs or gasless abdomen, suspected obstruction in proximal bowel loops, in children, or in pregnant women (Ko et al. 1993b).

4.2 Pathology of Bowel Obstruction

Bowel obstruction is characterized by dilatation of the intestinal segments proximal to the site of obstruction and collapse of the segment distal to the obstruc-

J. H. Lim, MD
Department of Radiology and Center for Imaging Science, Samsung Medical Center, Sungkyunkwan University School of Medicine, 50 Ilwon-dong, Kangnam-ku, Seoul 135-710, Korea

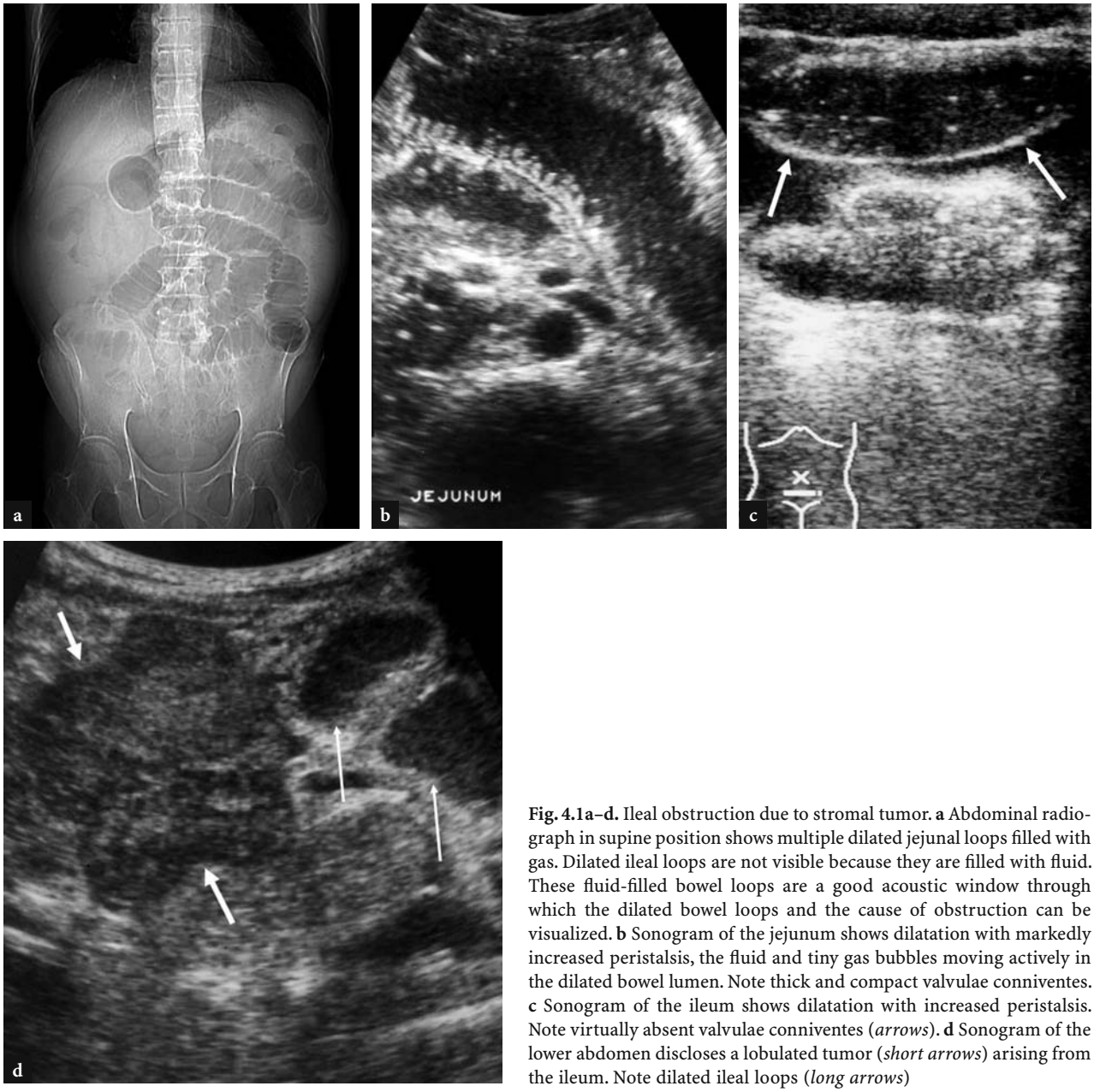

Fig. 4.1a–d. Ileal obstruction due to stromal tumor. **a** Abdominal radiograph in supine position shows multiple dilated jejunal loops filled with gas. Dilated ileal loops are not visible because they are filled with fluid. These fluid-filled bowel loops are a good acoustic window through which the dilated bowel loops and the cause of obstruction can be visualized. **b** Sonogram of the jejunum shows dilatation with markedly increased peristalsis, the fluid and tiny gas bubbles moving actively in the dilated bowel lumen. Note thick and compact valvulae conniventes. **c** Sonogram of the ileum shows dilatation with increased peristalsis. Note virtually absent valvulae conniventes (*arrows*). **d** Sonogram of the lower abdomen discloses a lobulated tumor (*short arrows*) arising from the ileum. Note dilated ileal loops (*long arrows*)

tion. The dilated bowel contains a large amount of fluid, food stuff, or gas. There is increased peristalsis to attempt to pass the luminal content beyond the obstruction site. Bowel obstruction can be due to obturation by blockage of the lumen by bowel content, such as food stuff, bezoar, or gallstone, due to bowel wall abnormality, such as neoplasm or stenosis, and due to extrinsic causes, such as adhesion and hernia. In paralytic ileus, the bowel is dilated and filled with fluid and gas, but there is no peristaltic movement.

4.3 Small Bowel Obstruction

Characteristic sonographic findings of small bowel obstruction is demonstration of dilated bowel loops with active peristalsis (Ko et al. 1993a). Multiple segments of dilated bowel loops can be readily demonstrated when the lumen is filled with fluid. The fluid may be clear or there may be air bubbles or

debris. The dilated loops are continuous, the diameter of the bowel lumen being over 2.0 cm and the segments being longer than 10 cm. Valvulae conniventes, or intestinal folds, are prominent and compact along the jejunum and are thin and sparse along the ileum (Fig. 4.1). Sometimes, there is no valvulae conniventes in the distal ileum and the bowel wall is flat. Increased peristalsis of the proximal segment of the bowel can be directly observed. The dilated bowel loop changes in caliber as well as in position, very vigorously, sometimes with some pauses. The fluid and tiny gas bubbles in the involved bowel show to-and-fro or whirling motion (Fig. 4.2). When the lumen is filled with gas, bowel dilatation is not easily recognized and it is difficult to make a diagnosis of bowel obstruction with sonography (Fig. 4.3). Usually, the bowel contains both fluid and gas. Sonographer should try to avoid gas filled lumen by pressing the abdomen with the transducer or change the position of the patient.

The causes of bowel obstruction can be demonstrated (Ko et al. 1993a). Small bowel bezoar is usually caused by persimmons and orange, sometimes by cabbage, sauerkraut, potato peel, or grapefruit.

Fig. 4.2. Increased peristalsis. Sonogram of the jejunum shows dilated loop with increased peristalsis. The dilated loop shows vigorous change in caliber and position. Tiny gas bubbles in the lumen show to-and-fro and whirling motion

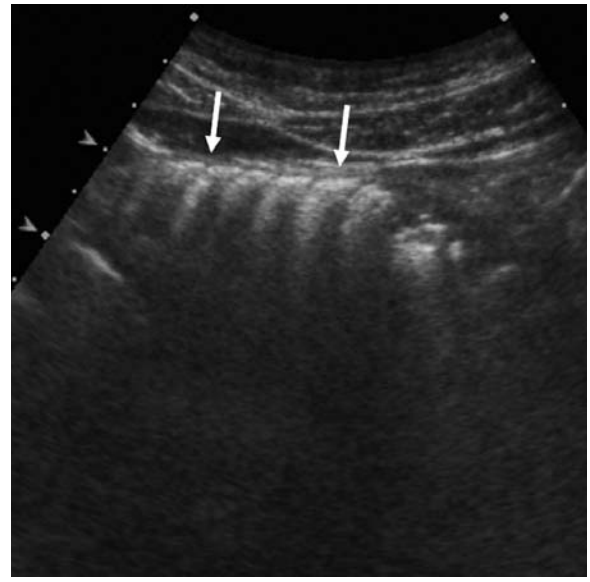

a

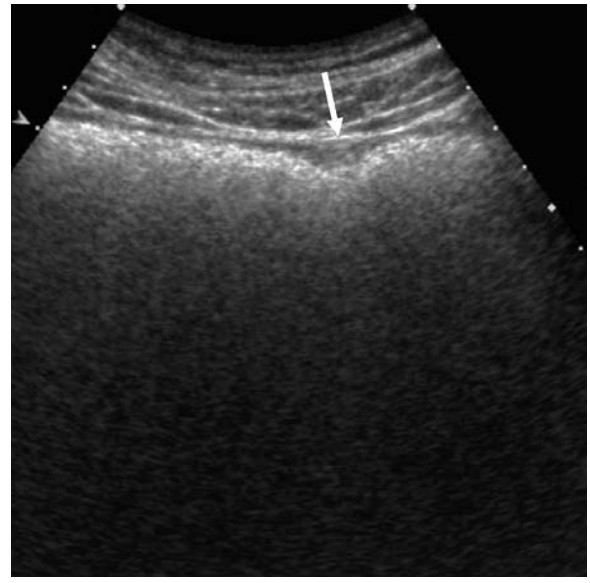

b

Fig. 4.3a,b. Gas-filled distended bowel loops. **a** Sonogram of the gas-filled jejunum shows air trapping in the valvulae conniventes (*arrows*). **b** Sagittal sonogram along the right side of the abdomen shows gas-filled, distended ascending colon. Note a haustral indentation (*arrow*)

Patients who have had subtotal gastrectomy or gastrojejunostomy are prone to develop bezoars.

Sonographically, bezoars are seen as an intraluminal mass with a hyperechoic arc-like surface casting a clear posterior acoustic shadow (Fig. 4.4; Ko et al. 1993b; Tennenhouse and Wilson 1990). Phytobezoar or trichbezoar are the same in sonographic appearances. The obstructed small bowel loops usually contain a large amount of air and bezoars can be overlooked if sonographic examination is not per-

a b

Fig. 4.4a,b. Phytobezoar in the jejunum. **a** Sonogram of upper abdomen shows hyperechoic, arc-like echo with clear acoustic shadow within a loop of the jejunum (*arrows*). Bowel loops proximal to the bezoar are dilated and filled with fluid. **b** Small bowel follow-through examination shows a large intraluminal filling defect at the end of the dilated jejunum, representing bezoar (*arrow*)

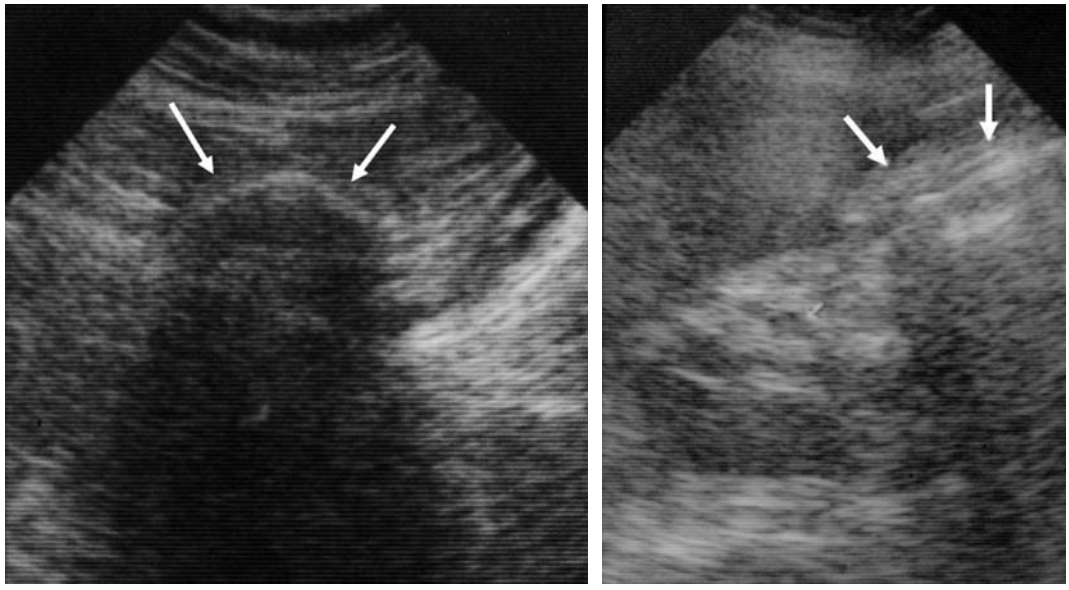

a b

Fig. 4.5a,b. Gallstone ileus. **a** Sonogram shows hyperechoic arc-like echo with posterior acoustic shadow within a dilated loop of ileum, representing a large gallstone (*arrows*). **b** Sonogram of the right upper abdomen discloses the gallbladder, which is empty (*arrows*)

formed meticulously. Sonographic findings of gallstone ileus are identical to those of bezoars (Fig. 4.5; Ko et al. 1993a; Davir et al. 1991). Air in the biliary tree or nonvisualization of the gallbladder lumen may be a clue for gallstone ileus.

Small bowel tumor, either primary or metastatic, can be identified as a cause of bowel obstruction (Ko et al. 1993a). At the end of dilated small bowel or between the dilated bowel loops, a tumor can be identified when the tumor is fairly large (Fig. 4.1).

Fluid within the bowel may comes into direct contact with that the mass indicating the mass arises from the bowel. There may be vascular structure in the mass visualized by Doppler study. Small bowel intussusception can be diagnosed by demonstration of bowel-within-bowel by recognizing characteristic multiple concentric rings, caused by invaginating layers of telescoped bowel, seen in cross section of the bowel loop.

Intestinal adhesion, the most frequent cause of bowel obstruction, cannot be demonstrated on sonography. Likewise, internal hernia and congenital fibrotic band can rarely be identified at sonography. Previous history of abdominal operation in patients without a sonographically visible cause of obstruction can lead to a diagnosis of adhesive ileus.

By virtue of demonstrating the vascular flow signal from the vessels of the dilated bowel wall, sonography may be useful in demonstrating the bowel segment at risk of strangulation. The sonographic finding of a thickened bowel wall, valvulae conniventes, and localized ascites within the leaves of the small bowel mesentery, is suggestive of complicated obstruction such as infarction or gangrene, and these cases require rapid surgical decompression (Ko et al. 1993a).

It has been reported that the accuracy of preoperative sonography in establishing the diagnosis of small bowel obstruction was 89% (Ko et al. 1993a). The cause of obstruction, such as tumor, bezoar, gallstone, or recurrent cancer in afferent loop syndrome may be predicted (Ko et al. 1993a; Meiser and Meissner 1985). Sonography has definite advantages in the diagnosis of proximal obstruction, such as duodenal or proximal jejunal obstruction (Ko et al. 1993a): in these cases, simple abdominal radiographs are often normal or do not show gas, because frequent vomiting results in lack of air in the obstructed segment (Fig. 4.6). Afferent loop syndrome can be reliably diagnosed with sonography (Lee et al. 1991). The superior mesenteric artery and vein are useful landmarks in the diagnosis of duodenal obstruction such as afferent loop or proximal jejunal obstruction, since the dilated lumen of the third portion of the duodenum crosses the midline anterior to the aorta and behind the superior mesenteric artery and vein (Fig. 4.7). By careful examination, recurrent tumor at the gastric stump as a cause of afferent loop can be diagnosed sonographically (Lee et al. 1991).

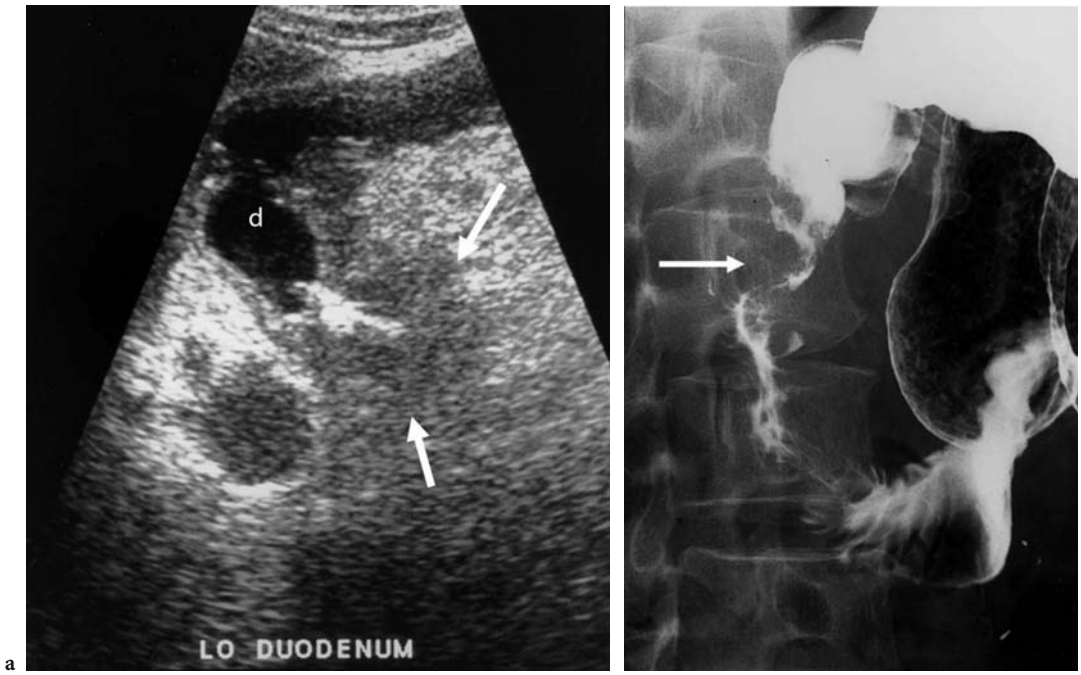

a b

Fig. 4.6a,b. Duodenal obstruction by adenocarcinoma. **a** Sagittal sonogram of the right upper abdomen discloses a mass (*arrows*) with dilated first part of the duodenum (*d*). **b** Upper gastrointestinal series shows near-complete obstruction by adenocarcinoma (*arrows*)

a

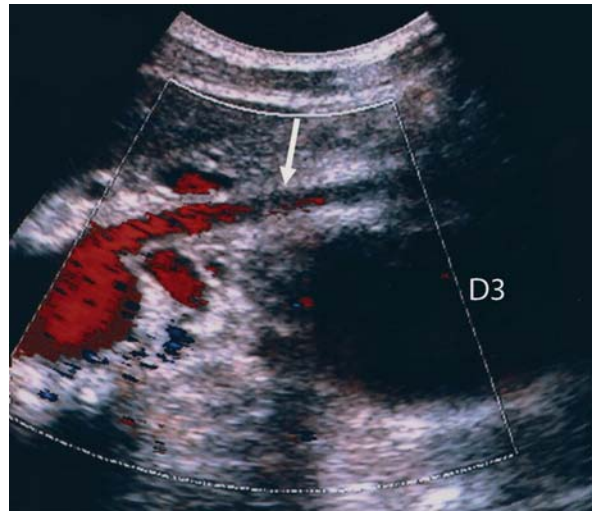

b

Fig. 4.7a,b. Afferent loop syndrome. **a** Supine abdominal radiograph shows virtually absent bowel gas because of frequent vomiting. **b** Sagittal color Doppler sonogram of the upper abdomen shows the dilated third part of the duodenum (*D3*) anterior to the abdominal aorta and posterior to the superior mesenteric artery (*arrows*)

4.4 Colon Obstruction

The most common cause of colonic obstruction is carcinoma, either primary or metastatic, whereas the most common cause of small bowel obstruction is adhesions; therefore, it is necessary to differentiate colonic obstruction from small bowel obstruction. Radiographs of the abdomen may be useful for the diagnosis of colonic obstruction in 60–70% of cases (Gore and Eisenberg 1994). Once colonic obstruction is suspected, contrast enema, is indicated to confirm the obstruction and to determine its level, severity, and cause (Amberg 1994). In the CT era, multidetector row CT examination is the best method for the evaluation of patients with acute abdomen including colon obstruction (Sinha and Verma 2005b; Patak et al. 2005).

Identification of the colon with sonography is relatively difficult because the colon is filled with gas and feces, rather than fluid. As gas and feces are present in various amounts in the normal colon, the diagnosis of obstruction can be made only when the colon is found to be dilated continuously to the level of the lesion (see Fig. 4.3), where abnormal distension ends abruptly, with the colon distal to it free of gas (Wilson 1994). Since the colon is fixed in position, each segment of colon is identified by position.

The causes of colon obstruction can be identified (Kojima et al. 1992). It has been reported that sonography predicted the cause of colon obstruction in 81% (Lim et al. 1994). As the majority of colon obstructions are due to colon cancer or ileocecal intussusception, sonography may reveal an obstructing mass or segmental thickening of the colon wall at the end of the dilated colon (Fig. 4.8; Ko et al. 1993a), or characteristic concentric rings along the sausage-like, invaginated bowel loops in intussusception (Weissberg et al. 1977). Sometimes, a soft tissue mass as a leading point of intussusception can be demonstrated (Fig. 4.9). Sonography is particularly useful in child intussusception (Woo et al. 1992; Verschelden et al. 1992).

4.5 Paralytic Ileus

Paralytic ileus can be reliably diagnosed by sonography by demonstrating very quilt or aperistaltic dilated bowel loops (Fig. 4.10). When the bowel loops are filled with more gas than fluid, sonography may

a b

Fig. 4.8a,b. Transverse colon obstruction due to adenocarcinoma. **a** Transverse sonogram of the right upper abdomen discloses circumferential thickening of the wall of the transverse colon (*arrows*) and fluid-filled dilated proximal colon. **b** CT image shows encircling thickening of the wall of the transverse colon (*arrow*) due to adenocarcinoma and dilated ascending and transverse colon

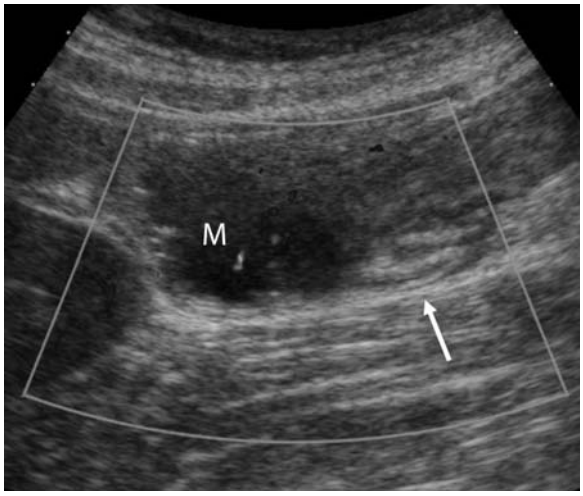

a

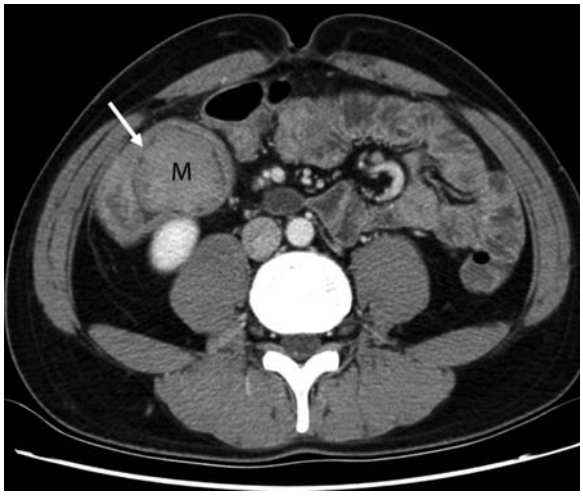

b

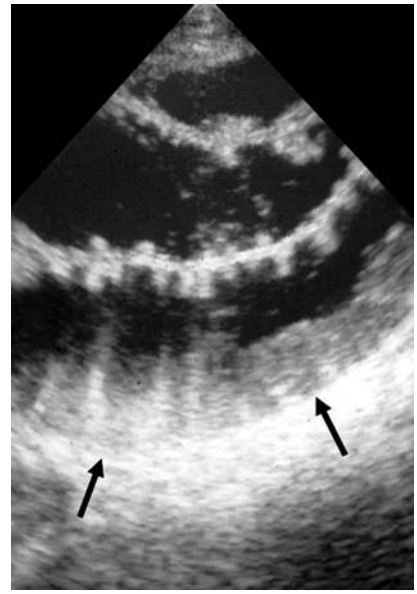

Fig. 4.10. Paralytic ileus. Sonogram of the lower abdomen shows dilated jejunum filled with fluid and debris. The dilated loops are essentially static and the bowel contents do not move. Note debris in the dependent part of the dilated loop (*arrows*), indicating no peristaltic movement

Fig. 4.9a,b. Ileocolic intussusception due to lymphoma. **a** Sagittal sonogram of the right abdomen shows an oval mass (*M*) in intussusception. Note folded bowel wall at the orifice of intussuscepted bowel (*arrow*). **b** CT image shows a round mass (*M*) surrounded by a thin line of fat invaginated into the ascending colon (*arrow*). Note slightly dilated jejunum and ileum

be of little value. Some difficulty may arise when the obstruction becomes prolonged and the obstructed segment becomes paralytic, and thus may be mistaken for paralytic ileus.

References

Amberg JR (1994) Overview: the acute abdomen. In: Margulis AR, Burhenne HJ, (eds) Alimentary tract radiology, 5th edn. Mosby, St. Louis, pp 2118–2119

Davir RJ, Sandrasagra FA, Joseph AEA (1991) Ultrasound diagnosis of gallstone ileus. Clin Radiol 43:282–284

Dunn JT, Halls JM, Berne TV (1984) Roentgenographic contrast studies in acute small bowel obstruction. Arch Surg 119:1305–1308

Furukawa A, Yamasaki M, Furuichi K et al (2001) Helical CT in the diagnosis of small bowel obstruction. Radiographics 21:341–355

Gore RM, Eisenberg RL (1994) Large bowel obstruction. In: Gore RM, Levine MS, Laufer I (eds) Textbook of gastrointestinal radiology. Saunders, Philadelphia, pp 1247–1258

Herlinger H, Maglinte DDT (1989) Small bowel obstruction. In: Herlinger H, Maglinte DDT (eds) Clinical radiology of the small intestine. Philadelphia, Saunders, pp 479–509

Ko YT, Lim JH, Lee DH, Lee HW, Lim JW (1993a) Small bowel obstruction: sonographic evaluation. Radiology 188:649–653

Ko YT, Lim JH, Lee DH, Yoon Y (1993b) Small bowel phytobezoars: sonographic detection. Abdom Imaging 18:271–273

Kojima Y, Tsuchiyama T, Niimoto S, Nakagawara G (1992) Adult intussception caused by cecal cancer and diagnosed preoperatively by ultrasonography. J Clin Ultrasound 20:360–363

Lee DH, Lim JH, Ko YT (1991) Afferent loop syndrome: sonographic findings in seven cases. Am J Rogentgenol 157:41–43

Lim JH, Ko YT, Lee DH et al (1994) Determining the site and causes of colonic obstruction with sonography. Am J Roentgenol 163:1113–1117

Megibow AJ, Balthazar EJ, Cho KC, Medwid SW, Birnbaum BA, Noz ME (1991) Bowel obstruction: evaluation with CT. Radiology 180:313–318

Meiser G, Meissner K (1985) Sonographic differential diagnosis of intestinal obstruction: results of a prospective study of 48 patients. Ultraschall Med 6:39–45

Mucha P (1987) Small intestinal obstruction. Surg Clin North Am 67:597–620

Patak MA, Mortele KJ, Ros PR (2005) Multidetector row CT of the small bowel. Radiol Clin North Am 43:1063–1077

Sinha R, Verma R (2005a) Multidetector row computed tomography in bowel obstruction. Part 1. Small bowel obstruction. Clin Radiol 60:1058–1067

Sinha R, Verma R (2005b) Multidetector row computed tomography in bowel obstruction. Part 2. Large bowel obstruction. Clin Radiol 60:1068–1075

Taourel PG, Fabre JM, Pradel JA, Seneterre EJ, Megibow AJ, Bruel JM (1995) Value of CT in the diagnosis and management of patients with suspected acute small bowel obstruction. Am J Roentgenol 165:1187–1192

Tennenhouse JE, Wilson SR (1990) Sonographic detection of a small bowel bezoar. J Ultrasound Med 9:603–605

Verschelden P, Filiatrault D, Garel L et al (1992) Intussusception in children: reliability of US in diagnosis: a preoperative study. Radiology 184:741–744

Weissberg Dl, Scheible W, Leopold GR (1977) Ultrasonographic appearance of adult intussusception. Radiology 124:791–792

Wilson SR (1991) The gastrointestinal tract. In: Rumack CM, Wilson SR, Charboneau JW (eds) Diagnostic ultrasound. Mosby, St. Louis, pp 181–206

Wilson SR (1994) The acute abdomen of gastrointestinal tract origin: sonographic evaluation. In: Margulis AR, Burhenne HJ (eds) Alimentary tract radiology, 5th edn. Mosby, St. Louis, pp 2099–2117

Woo SK, Kim JS, Suh SJ, Paik TW, Choi SO (1992) Childhood intussusception: US-guided hydrostatic reduction. Radiology 182:77–80