Anatomy of the Abdominal Wall 1

Orhan E. Arslan

1.1 Introduction

The abdominal wall encompasses an area of the body bounded superiorly by the xiphoid process and costal arch, and inferiorly by the inguinal ligament, pubic bones and the iliac crest.

Visualization, palpation, percussion, and auscultation of the anterolateral abdominal wall may reveal abnormalities associated with abdominal organs, such as the liver, spleen, stomach, abdominal aorta, pancreas and appendix, as well as thoracic and pelvic organs. Visible or palpable deformities such as swelling and scars, pain and tenderness may reflect disease processes in the abdominal cavity or elsewhere. Pleural irritation as a result of pleurisy or dislocation of the ribs may result in pain that radiates to the anterior abdomen. Pain from a diseased abdominal organ may refer to the anterolateral abdomen and other parts of the body, e.g., cholecystitis produces pain in the shoulder area as well as the right hypochondriac region. The abdominal wall should be suspected as the source of the pain in individuals who exhibit chronic and unremitting pain with minimal or no relationship to gastrointestinal function, but which shows variation with changes of posture [1]. This is also true when the anterior abdominal wall tenderness is unchanged or exacerbated upon contraction of the abdominal muscles (positive Carnett's sign). Abdominal wall pain can be the result of localized endometriosis, rectus sheath hematoma, or abdominal incision or hernia.

1.2 Regions of the Abdominal Wall

To accurately describe the locations of visible abnormalities, masses, and pain in a typical clinical write-up, the anterolateral abdomen is divided into nine regions by four imaginary planes: two verticals (midclavicular/midinguinal) and two horizontal (transpyloric/intertubercular) planes (Fig. 1.1). The transpyloric plane corresponds to the midpoint between the umbilicus and xiphoid process, crossing the pylorus of the stomach at the lower border of the first lumbar vertebra. The subcostal plane that passes across the costal margins and the upper border of the third lumbar vertebra may be used instead of the transpyloric plane. The lower horizontal plane, designated as the intertubercular line, traverses the anterior abdomen at the level of fifth lumbar vertebra, and connects the iliac tubercles on both sides. A second lower horizontal plane, the interspinous plane, may also be used, interconnecting the anterior superior iliac spines on both sides and running across the sacral promontory. Of the nine areas, the centrally placed zone is the umbilical region. This region surrounds the umbilicus and usually corresponds to the location of the jejunum, transverse part of the duodenum, terminal ileum, transverse colon, ureter and the greater curvature of the stomach.

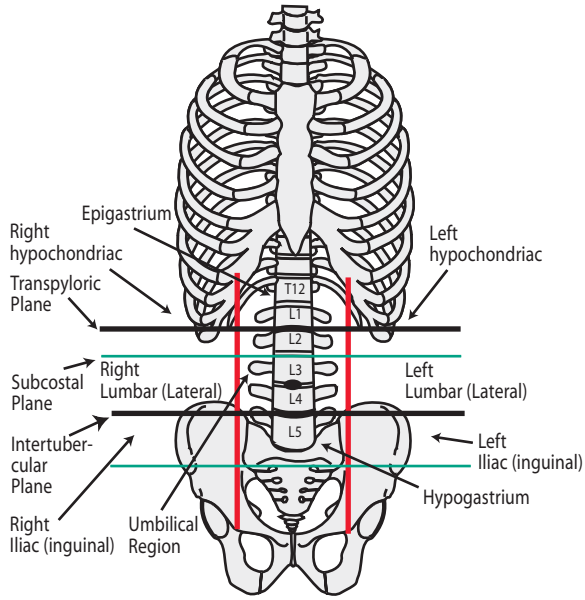

Fig. 1.1. Various regions of the anterior abdominal wall

The epigastrium is the upper middle part of the anterior abdomen between the umbilicus below and the costal arches and the xiphoid process above. It contains the stomach, left lobe of the liver, and part of the pancreatic head. The pubic region known as the hypogastrium de-

fines the zone immediately distal to the umbilical region and contains the ileum and sigmoid colon. The hypochondriac regions flank the epigastrium and are occupied on the right side by the liver, gallbladder, right colic flexure, descending duodenum, right kidney and suprarenal gland. On the left side these regions contain the spleen, left kidney and suprarenal gland, tail of the pancreas, left colic flexure, and fundus of the stomach. Most of the hypochondriac and parts of the epigastric regions are protected by the lower ribs. Areas immediately to the right and left of the umbilical region are designated as the right and left lumbar (lateral) regions, containing the ascending and descending colon, respectively. The right and left iliac regions surround the hypogastrium. The right iliac region contains the appendix and cecum, and the left iliac region corresponds to locations of the sigmoid colon and left ureter.

A simplified division of the anterolateral abdomen uses two imaginary planes that run through the umbilicus, one passing horizontally and the other vertically. The four quadrants separated by these planes divide the anterior abdomen into the right and left upper and lower quadrants.

In summary, the regions described above help medical practitioners to accurately describe the pathological processes associated with the anterior abdominal wall and to document the findings in the differential diagnosis. For example, periumbilical and hypogastric pain is felt during the initial stage of appendicitis, while pain in the right iliac region occurs at a later phase in this condition. Pancreatic or esophageal disorders produce pain that projects to the epigastrium.

1.3 Layers of the Abdominal Wall

The anterolateral abdominal wall consists, from the outside in, of the skin, superficial fascia, deep fascia, external and internal abdominal oblique, transverse abdominis and associated aponeuroses, rectus abdominis and pyramidalis, as well as the transversalis fascia.

1.3.1 Skin

The skin is of average thickness, and loosely attaches to the underlying tissue. It exhibits certain surface markings such as the umbilicus, linea alba, linea semilunaris, epigastric fossa, and McBurney's point.

The umbilicus, a midline fibrous cicatrix covered by a folded area of skin, is an important anatomical landmark in the anterior abdomen that marks the original attachment of the fetal umbilical cord. In young adults, it is usually located at the level of the intervertebral disc between the third and fourth vertebrae. However, lower levels are observed in obese individuals and in conditions that reduce abdominal tone. In the fetus, the umbilicus transmits the vitelline and umbilical vessels and yolk stalk.

The umbilicus can be the site of an acquired umbilical hernia or omphalocele [2, 3]. It is surrounded by the paraumbilical veins that establish connections with both the portal vein and the inferior vena cava (portacaval anastomosis) through a series of venous channels. It is also the site of attachment of the umbilical ligaments that consist of the median umbilical (remnant of the urachus), medial umbilical (obliterated umbilical arteries) and lateral umbilical (inferior epigastric vessels) ligaments/folds. A patent urachus may discharge urine because of its connection to the urinary bladder, and it can be associated with outflow obstruction or pus from an infected urachal cyst or with fecal matter if it is connected to part of the large intestine.

The umbilicus may also receive the embryological remnant of the vitelline duct known as Meckel's diverticulum. This diverticulum occasionally protrudes through the anterolateral abdomen and produces Littre's hernia. The umbilicus also receives the round ligament of the liver, a remnant of the umbilical vein. The umbilical vein remains patent for some time during early infancy and allows blood transfusion through catheterization in individuals with hemolytic diseases such as erythroblastosis fetalis [4].

The superficial abdominal reflex refers to deviation of the umbilicus toward the stimulated side when the skin of the anterolateral abdomen is stimulated by a blunt object applied to the flank at the midaxillary line inward toward the umbilicus. This reflex, which involves contraction of the abdominal muscles and subsequent deviation of the umbilicus, reveals the condition of the ninth through the eleventh spinal cord segments. Disappearance of this reflex is associated with postoperative pain following thoracotomy [5]. Absence of this reflex can be an early sign of syringomyelia in individuals with scoliosis [6, 7].

The linea alba (white line) is formed by the midline fusion of the aponeuroses of flat abdominal muscles and may be visible through the skin of muscular individuals. The linea semilunaris (Spigelian line) marks the lateral border of the rectus abdominis, extending from the costal arch near the ninth costal cartilage to the pubic tubercle. This line marks the sites of entry of motor nerves to the rectus abdominis, rendering it a surgically undesirable site for incisions. Spigelian hernia, which consists of extraperitoneal fat covered by the skin, superficial fascia and the aponeurosis of the external oblique, may be hidden at the junction of the linea semilunaris and arcuate line of Douglas. The small depression below the infrasternal angle is termed the epigastric fossa. McBurney's point marks the junction of

the lateral and middle third of a line that connects the anterior superior iliac spine to the pubic tubercle. This topographic landmark on the anterior abdomen corresponds to the common location of the appendix.

The horizontal directions of the connective tissue fibers beneath the epidermis form the visible Langer's cleavage lines. Due to the elastic quality of the connective tissue, an incision will produce retraction of the connective tissue and eventual gapping of the skin. An incision made perpendicular to the direction of Langer's lines is most likely to gape and result in prominent scarring. Since the course of the nerves and vessels that supply the anterolateral abdomen parallels the cleavage lines of the skin, transverse incisions of the abdomen are surgically more favorable. They are less likely to gape or cause damage to nerves or vasculature and heal faster without visible scarring. The dermis of the skin of the anterolateral abdomen is resilient, permits some degree of stretch, and is able to counteract the prolonged tearing pressure. However, stretch exerted by the pregnant uterus can disrupt the connective tissue fibers of the dermis and produce striae perpendicular to the Langer's lines, commonly known as 'stretch marks'.

1.3.2 Superficial Fascia

The superficial fascia (Fig. 1.2) is a soft and movable layer, which comprises, to a great extent, a single variably fatty superficial layer known as Camper's fascia. The amount of fat in Camper's fascia varies depending on the nutritional status of the individual. In the male, it continues inferiorly with the dartos layer of the scrotum and outer layer of the penis and spermatic cord, where it becomes thinner, lacking adipose tissue. In the female, it continues with the superficial fascia covering the labia majora. Approximation of Camper's fascia at closure of the abdominal incision during cesarean delivery appears to prevent postoperative superficial wound disruption [8].

In the lower wall of the anterior abdomen, a deeper membranous layer known as Scarpa's fascia becomes visible [9]. This layer remains connected, though loosely, to the deep fascia that covers the aponeurosis of the external abdominal oblique muscle. The strength of the Scarpa's fascia can stabilize sutures placed when closing incisions of the abdominal wall. The space between the deep fascia that covers the external oblique and Scarpa's fascia (superficial inguinal pouch) occupied by loose connective tissue may serve as a frequent site for retracted ectopic testis in children.

Scarpa's fascia (Fig. 1.2) firmly attaches to the linea alba and symphysis pubis and forms the fundiform ligament of the penis or the clitoris. In the male, it joins the Camper's fascia and continues into the scrotum as a single smooth muscle containing a layer known as the dartos. This deep and tough collagenous layer is continuous with Colle's fascia of the perineum, and with the inferior wall of the superficial perineal pouch or recess. In the upper thigh, it is attached to the fascia lata

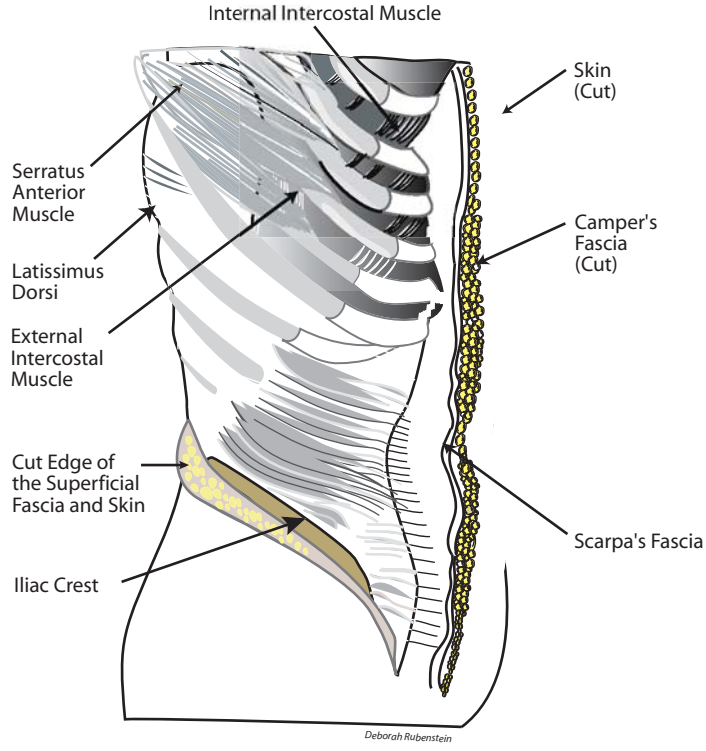

Fig. 1.2. The two layers of the superficial fascia of the abdominal wall

just below and parallel to the inguinal ligament. Since the superficial perineal pouch contains the urethra, rupture of the urethra may result in extravasation of blood and urine into the superficial perineal pouch. Accumulated blood and urine in this pouch may extend into the anterior abdominal wall between Scarpa's fascia and the deep fascia covering the external oblique. Because of the firm attachment of Scarpa's fascia to the fascia lata, inferior spread of fluid is not possible. The space between the two layers of the superficial fascia allows passage of the cutaneous vessels, nerves and lymphatics of the superficial inguinal nodes.

1.4 Blood Supply of the Abdominal Wall

The abdominal wall receives blood supply through branches of the femoral, external iliac, subclavian and intercostal arteries as well as the abdominal aorta (Fig. 1.3). These branches include the superficial epigastric, superficial circumflex iliac, superficial external pudendal, deep circumflex iliac, superior and inferior epigastric, posterior intercostal, subcostal, musculophrenic, and lumbar arteries [10].

1.4.1 Superficial Epigastric Artery

The superficial epigastric artery is a branch of the femoral artery distal to the inguinal ligament that ascends in the superficial fascia of the abdomen toward the umbilicus. This vessel provides the blood supply to the superficial fascia and skin of the abdomen, anastomosing with the inferior epigastric artery [10].

1.4.2 Superficial Circumflex Iliac Artery

The superficial circumflex iliac artery arises from the femoral artery near the origin of the superficial epigastric artery. It pierces the deep fascia of the thigh lateral to the saphenous opening and courses laterally toward the anterior superior iliac spine to supply the superficial fascia and skin. It is considered the smallest branch of the femoral artery that anastomoses with the deep circumflex iliac, lateral femoral circumflex iliac and superior gluteal arteries. The course of this vessel, an important structure in a groin flap, can best be localized by palpation of the anterior superior iliac spine and the pubic tubercle through the skin of the inguinal region [11].

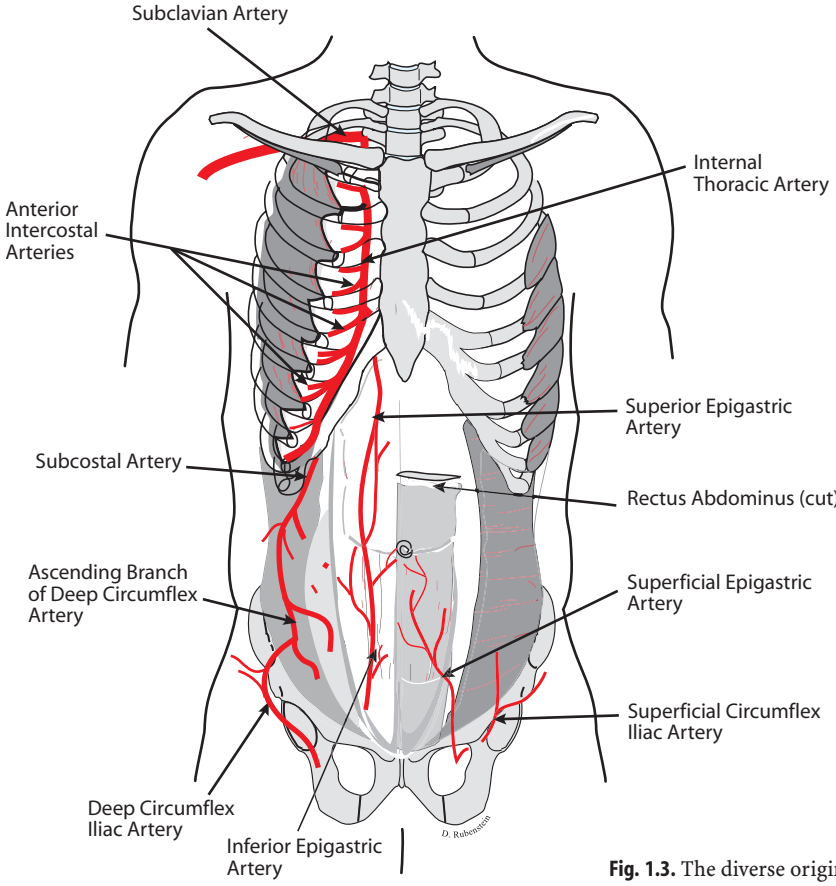

Fig. 1.3. The diverse origin of the arterial supply to the abdomen

1.4.3 Superficial External Pudendal Artery

The superficial external pudendal artery branches off the femoral artery and runs medially deep to the great saphenous vein. It travels across the spermatic cord (round ligament) to supply the lower anterior wall of the abdomen.

1.4.4 Deep Circumflex Iliac Artery

The deep circumflex iliac artery originates from the external iliac artery lateral to the point of origin of the inferior epigastric artery and advances laterally posterior to the inguinal ligament in a sheath formed by the transversalis and iliac fascia. After it pierces the transverse abdominis and enters the area between this muscle and the internal oblique muscle, it anastomoses with the iliolumbar, superior gluteal, lumbar, and inferior epigastric arteries.

1.4.5 Superior Epigastric Artery

The superior epigastric artery (Fig. 1.3), one of the terminal branches of the internal thoracic artery, arises at the level of the sixth costal cartilage, descends anterior to the transversus thoracis, and continues into the sternocostal triangle of Morgagni. The latter is a gap between the costal and sternal attachments of the diaphragm. It then enters the posterior layer of the rectus sheath at the middle of the xiphoid process and the anterior sheath at the middle of the upper third of the upper abdomen and supplies the rectus abdominis, diaphragm and the skin of the abdomen [12]. This vessel establishes linkage with the inferior epigastric artery and with the hepatic arteries through the falciform ligament. The arterial anastomosis between the superior and inferior epigastric arteries provides important collateral circulation to the lower part of the body in individuals with postductal coarctation.

1.4.6 Inferior Epigastric Artery

The inferior epigastric artery (Fig. 1.3) is a branch of the external iliac artery that ascends obliquely along the medial margin of the deep inguinal ring, posterior to the spermatic or round ligament. It may arise from the femoral artery, or, very rarely from the obturator artery. It pierces the transversalis fascia to enter into the posterior wall of the rectus abdominis at the level of the arcuate line. This vessel penetrates the posterior sheath near the middle of the lower abdomen and the anterior sheath in an area ranging from the upper third of the lower abdomen to the umbilicus. The arterial anastomosis between the inferior and superior epigastric arteries and the posterior intercostal arteries at the lower third of the upper abdomen allows collateral circulation to develop with the internal thoracic artery upon obstruction or ligation of the common or external iliac artery. This arterial anastomosis is also significant in the planning and implementation of vertical fasciocutaneous flaps of the abdominal wall [12]. After giving rise to the pubic, cremasteric and cutaneous branches, the inferior epigastric artery ascends under the parietal peritoneum as the lateral (epigastric) umbilical fold.

The cremasteric branch of the inferior epigastric artery supplies the cremasteric muscle and other coverings of the spermatic cord as well as the testis through its anastomosis with the testicular artery. In the female, it provides blood supply to the round ligament. The pubic branch descends posterior to the pubis, supplies the parietal peritoneum and anterior abdominal muscles, forming an anastomosis with branches of the lumbar, circumflex iliac, and the obturator arteries. In one-third of individuals, the pubic branch may be replaced by the obturator artery. The pubic branch forms an anastomosis with and supplies the parietal peritoneum and anterior abdominal muscles. The cutaneous branches establish anastomoses with the superficial epigastric artery and supply the skin of the lower abdomen and the adjacent part of the aponeurosis of the external abdominal oblique.

1.4.7 Posterior Intercostal Arteries

The lower two or three posterior intercostal arteries cross the corresponding intercostal space into the costal groove proximal to the costal angle. At this location they lie between the intercostal vein (above) and intercostal nerve (below), continuing into the anterior abdomen with the subcostal, superior epigastric and lumbar arteries. The posterior intercostal arteries enter the rectus sheath from its lateral border, anastomosing with the superior and inferior epigastric arteries.

1.4.8 Subcostal Artery

The subcostal artery courses inferior to the last rib and anterior to the 12th thoracic vertebra. It lies posterior to the sympathetic trunk, thoracic duct, pleura and diaphragm. Then, it descends into the posterior abdominal wall posterior to the lateral arcuate ligament accompanied by the corresponding vein and nerve. As it continues anterior to the quadratus lumborum and posterior to the kidney, the right subcostal artery courses behind the ascending colon, whereas the left subcostal artery travels behind the descending colon.

The subcostal artery establishes anastomoses with the lower posterior intercostal, superior epigastric and lumbar arteries.

1.4.9 Musculophrenic Artery

The musculophrenic artery, a terminal branch of the internal thoracic artery, runs inferiorly and laterally posterior to the seventh to ninth costal cartilages and gives rise to the lower two anterior intercostal arteries to the corresponding intercostal spaces. It supplies the pericardium and anterior abdominal muscles, anastomosing with the deep circumflex iliac and the lower two posterior intercostal arteries.

1.4.10 Lumbar Arteries

The lumbar arteries arise from the abdominal aorta anterior and to the left of the lumbar vertebrae. A fifth pair of lumbar arteries may arise from the middle sacral artery. They run posterior to the sympathetic trunk and the tendinous origins of the psoas major muscle. On the right side they travel posterior to the inferior vena cava but only the upper two pairs of lumbar arteries course posterior to the corresponding crus of the diaphragm. The upper three pairs run anterior, while the lowest course runs posterior, to the quadratus lumborum. After they pierce the transverse abdominis, running between this muscle and the internal oblique, the lumbar arteries anastomose with the iliolumbar, subcostal, deep circumflex, inferior epigastric and lower posterior intercostal arteries. Spinal branches of the lumbar arteries supply the conus medullaris, cauda equina, and spinal meninges.

1.5 Venous Drainage of the Anterolateral Abdomen

The anterior abdominal wall is drained via the superficial epigastric, thoracoepigastric, paraumbilical and the superficial circumflex iliac veins (Fig. 1.4).

1.5.1 Superficial Epigastric Vein

The superficial epigastric vein drains the inferior part of the anterior abdominal wall and is connected to the paraumbilical and thoracoepigastric veins. This vessel drains via the great saphenous vein into the femoral, external iliac and common iliac veins and eventually into the inferior vena cava. It also drains into the portal vein through the paraumbilical veins and the partially obliterated umbilical vein. Through this venous linkage to both the inferior vena cava and portal vein, a portacaval anastomosis is established. Occlusion of the por-

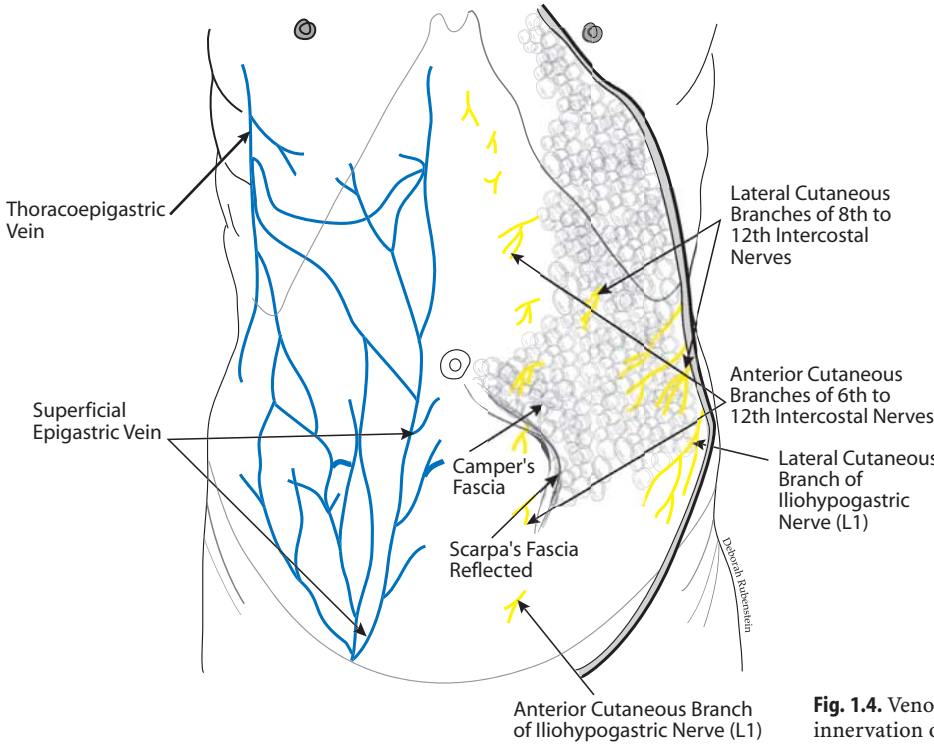

Fig. 1.4. Venous drainage and cutaneous innervation of the abdominal wall

tal vein may activate this collateral venous circulation, producing distension of the paraumbilical veins.

1.5.2 Thoracoepigastric Vein

The thoracoepigastric vein drains the middle portion of the anterolateral abdomen and connects the superficial epigastric and superficial circumflex iliac veins to the lateral thoracic vein. The lateral thoracic vein joins the axillary, which continues with the subclavian and brachiocephalic veins and eventually drains with the great saphenous vein; this, in turn, joins the femoral vein, which continues with the external iliac and common veins and later with the inferior vena cava. Through these elaborate venous connections, the lateral thoracic vein forms a venous link for cava-caval anastomosis. Occlusion of the inferior vena cava is most likely to activate this collateral venous circulation, producing dilation of the thoracoepigastric, the lateral thoracic, and the tributaries of the superficial circumflex iliac and the superficial epigastric veins.

1.5.3 Paraumbilical Veins

The paraumbilical veins are relatively small veins that drain the periumbilical region and into the portal vein. They are involved in formation of the porta-caval anastomosis via their connections to the superficial epigastric vein. Dilation of these veins produces caput medusa, after a Greek mythological character whose head was covered with a multitude of snakes, referring to the radial pattern of varicosed paraumbilical veins around the umbilicus.

1.5.4 Superficial Circumflex Iliac Vein

The superficial circumflex iliac vein drains the superficial structures in the lower anterior abdominal wall and the proximal region of the superficial thigh. It is connected to the lateral thoracic vein that drains into the superior vena cava via the thoracoepigastric vein. This venous connection may also show dilation in caval obstruction.

1.6 Innervation of the Abdominal Wall

The skin of the anterior abdominal wall is innervated by the ventral rami of the lower five or six thoracic (thoracoabdominal) spinal nerves that continue from the intercostal spaces into the abdominal wall (Fig. 1.5). The anterolateral abdomen also receives nerve fibers from the subcostal, iliohypogastric, and ilioinguinal nerves.

A typical intercostal nerve runs across the deep surface of the internal intercostal muscle and membrane between the internal and innermost intercostal muscles. It then continues in the costal groove below the in-

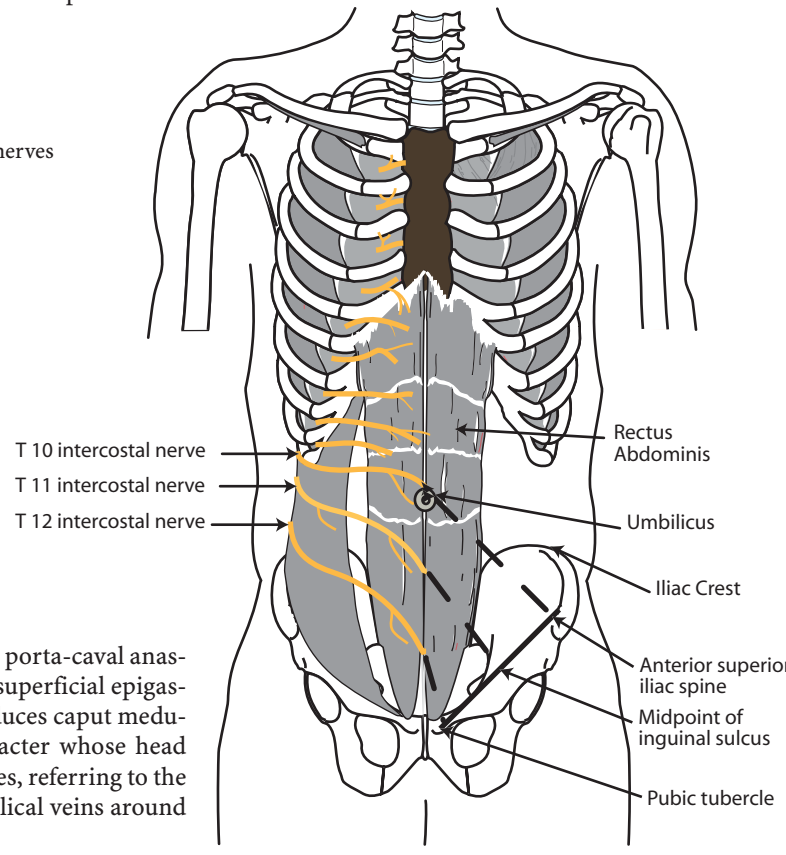

Fig. 1.5. Course of the thoracoabdominal nerves

tercostal artery. Each intercostal nerve is connected to an adjacent sympathetic ganglion by a white communicating ramus conveying presynaptic sympathetic fibers, and by a gray communicating ramus that transmits postsynaptic sympathetic fibers.

1.6.1 Thoracoabdominal Nerves

The seventh and eight intercostal nerves, as is the case with the rest of the intercostal nerves, divide into lateral and anterior cutaneous branches. The lateral branch further divides into anterior and posterior branches, piercing the flat abdominal muscles in the midaxillary line to reach the skin. The anterior cutaneous branches, which represent the terminal branches of the ventral rami of the intercostal nerves, pierce the rectus sheath laterally and emerge anteriorly to reach the skin. They pursue a curved course toward the lateral border of the rectus abdominis, and perforate the transverse abdominis to reach the internal abdominal oblique aponeurosis. After piercing the internal abdominal oblique, they run parallel to the costal margin, enter the posterior surface of the rectus abdominis to continue in its sheath to reach and supply the skin.

The ninth to eleventh intercostal nerves pierce the diaphragm and transverse the abdominis and enter the gap between the transverse and internal oblique, where they pierce the posterior layer of the internal abdominal oblique aponeurosis near its lateral border. Beyond this point, they travel in a similar manner to the seventh and eight intercostal nerves. The ninth intercostal nerve is much larger and should be preserved in a subcostal (Kocher's) incision, which is usually done one inch below the costal arch in individuals with a wider infrasternal angle. The downward and forward direction of the anterior branches of the intercostal nerves brings the tenth intercostal nerve to the umbilicus. The lower intercostal nerves may be entrapped as they pierce the rectus sheath and cause rectus abdominis syndrome, which is characterized by numbness and paresthesia in the median and paramedian areas of the abdomen.

The subcostal nerve, the ventral ramus of the 12th thoracic spinal nerve, is much larger than the intercostal nerves and runs inferior to the corresponding rib with corresponding vessels. It passes posterior to the lateral arcuate ligament and kidney, and anterior to the quadratus lumborum. It pierces the aponeurosis of the transverse abdominis and internal abdominal oblique and then assumes a course similar to that of the lower intercostal nerves. After crossing the iliac crest immediately posterior to the anterior superior iliac spine, the subcostal nerve supplies the pyramidalis via the medial branch and the anterior gluteal skin via its lateral branch.

Since thoracoabdominal nerves also convey sensation from the costal and peripheral diaphragmatic pleura, pleural inflammation can produce pain felt in the abdominal wall. Appendicitis induced pain and rigidity in the abdominal are due to the fact that the sympathetic innervation of the abdominal viscera is derived from the same segments that supply the dermatomes of the anterolateral abdomen. Tuberculosis affecting the lower five thoracic vertebrae can also produce pain that projects to the anterior abdominal wall. Similarly, shingles of the lower ganglia of the thoracic spinal nerves produce diffuse pain and vesicular eruptions in the anterolateral abdominal wall. Referred abdominal pain may also occur as a result of subluxation of the interchondral joints that entraps the intercostal nerves. Constrictive pain, felt as a tight cord around the abdomen, is usually a manifestation of a lesion that has affected a single pair of intercostal nerves. Clicking rib syndrome, which results from subluxation of the interchondral joints of the lower ribs, may cause compression of the lower intercostal nerves and produce pain in the anterior abdomen.

Thoracoabdominal nerves that supply the abdominal muscles form an extensive communicating network that allows considerable overlap. This type of overlap is responsible for the limited or complete lack of perceptible clinical deficits upon damage to one or two nerves. In contrast, the segmental innervation of the rectus abdominis has no or very little cross-linkage. Consequently, individual nerve damage associated with the rectus abdominis is likely to produce deficits in the affected area.

Tapping the anterior abdominal wall produces contraction of the abdominal muscles and thereby reveals the conditions of certain spinal segments. A quick tap at the midclavicular line below the costal arch assesses the integrity of the seventh through the ninth spinal segments. Tapping the area immediately lateral to the umbilicus appraises the condition of the ninth to the eleventh spinal segments. Imparting a quick tap immediately above the inguinal ligament at the midclavicular line discloses information about the eleventh through the first lumbar spinal cord segments [13].

1.6.2 Iliohypogastric Nerve

The iliohypogastric nerve courses posterior to the psoas major and exits through its lateral border posterior to the kidney and anterior to the quadratus lumborum and the iliacus muscles. Near the iliac crest, it pierces and provides innervation to the transverse abdominis and internal abdominal oblique muscles, and splits into lateral and anterior branches. The lateral branch distributes cutaneous branches to the gluteal region, while the anterior branch pierces the internal and external oblique

above the superficial inguinal ring to supply the suprapubic region. When McBurney's incision is employed in appendectomy, superior and medial to the anterior superior iliac spine, the iliohypogastric nerve is preserved and usually isolated from the adjacent structures.

1.6.3 Ilioinguinal Nerve

The ilioinguinal nerve follows a course identical to that of the iliohypogastric nerve. It runs downward and forward between the transverse abdominis and internal oblique. It enters the inguinal canal by piercing the internal oblique to lie between it and the overlying external abdominal oblique aponeurosis. Within the inguinal canal, the ilioinguinal nerve descends inferior and lateral to the spermatic cord in the male, or the round ligament of the uterus in the female. As it emerges via the superficial inguinal ring, it provides sensory fibers to the anterior part of the external genitalia, and motor fibers to the lower part of the internal abdominal oblique and transverse abdominis. The ilioinguinal nerve may be absent or very small, and may join the iliohypogastric nerve.

In a study conducted by Rab et al. [14] on cadaveric specimens, the ilioinguinal nerve provided no sensory branches in 40% of examined specimens. In 30% of specimens it shared a branch with the genitofemoral nerve and was the principal nerve to the groin. In the remaining specimens it assumed a primary sensory function supplying the mons pubis, anterior part of the labia majora, inguinal crease, and root of the penis and anterior scrotum.

The ilioinguinal nerve may be damaged in lower quadrant surgical procedures, e.g., appendectomy, resulting in a weakness of the affected abdominal muscles, and predisposition to herniation. Similarly, the course of the ilioinguinal nerve and its genital branches varies considerably, rendering them prone to injury in the repair of an inguinal hernia. A direct inguinal hernia may also develop as a result of damage to the ilioinguinal nerve and subsequent wearing down of the abdominal muscles. Entrapment [15] of the ilioinguinal nerve within the inguinal ligament (ilioinguinal syndrome) may produce debilitating chronic pain in the cutaneous area of its distribution.

Postoperative persistent lower abdominal pain in the absence of gastrointestinal and or gynecologic workup should alert the surgeon to the possibility of ilioinguinal or iliohypogastric nerve entrapment. Painful recurrent neuroma [16] within the ventral abdominal wall can be avoided by neuroectomy using a retroperitoneal proximal resection.

1.6.4 Genitofemoral Nerve

The genitofemoral nerve (L1, L2) pierces the psoas major and emerges on the anterior surface of that muscle. It descends posterior to the ureter and gonadal vessels, and usually divides anterior to the lower third of the psoas major into femoral and genital branches. In the male, the genital branch enters the deep inguinal ring, innervates the cremasteric muscle, emerging from the superficial inguinal ring to supply the scrotum. In the female it follows a similar course and distributes sensory fibers to the skin of the major labium. The femoral branch passes posterior to the inguinal ligament to provide sensory fibers to the upper middle part of the femoral triangle. Due to the variability of the course of the genitofemoral nerve in the inguinal region, entrapment of the genital branch of this nerve may be a possible cause of chronic groin pain [17].

1.7 Lymphatics

Lymphatics of the supraumbilical part of the anterolateral abdominal wall drain into the anterior or pectoral group of the axillary lymph nodes. This group of lymph nodes is located along the inferior border of the pectoralis minor adjacent to the lateral thoracic vessels. Lymphatics from the infraumbilical region drain into the lateral and medial subgroups of the superficial inguinal lymph nodes that lie distal to the inguinal ligament.

1.8 Deep Fascia

The deep fascia of the abdominal wall cannot easily be separated from the underlying epimysium and the aponeuroses of the flat abdominal muscles, and it usually continues with the external spermatic fascia. Anterior to the lower end of the linea alba, this fascia is thickened to form the suspensory ligament of the penis or clitoris and continues with their deep fascia of the external genitalia.

1.9 Musculature of the Anterior Abdominal Wall

The anterolateral abdomen consists of the external and internal abdominal oblique, transverse and rectus abdominis, pyramidalis, as well as the cremasteric muscles. Positive Carnett's sign, which refers to increased tenderness associated with contraction of the abdomi-

nal muscles, usually indicates that the cause of the pain is in the anterolateral abdominal wall and not due to intestinal dysfunction.

The muscles of the anterolateral abdomen maintain intra-abdominal pressure and the position of the viscera, by exerting compressive and twisting force. They facilitate certain physiologic functions such as parturition, vomiting, defecation, urination and coughing. Contraction of these muscles also promotes expiration by depressing and compressing the lower thorax.

1.9.1 External Abdominal Oblique

The external abdominal oblique muscle (Figs. 1.6, 1.7) is the most superficial abdominal muscle that originates from the external surfaces of the lower seven or eight ribs and interdigitates with the serratus anterior and latissimus dorsi muscles. Most of the muscle fibers run downward and medially, forming an aponeurosis near the lateral border of the rectus abdominis. The muscle fibers from the lower two ribs descend vertically downward to attach to the iliac crest. Muscle fibers are rarely found inferior to the line that connects the umbilicus to the anterior superior iliac spine. The vessels and nerves that supply the abdominal wall are contained in the double fascial layer that covers the internal surface of the external abdominal oblique and the external surface of the internal abdominal oblique muscle.

The portion of the muscle that inserts into the outer margin of the iliac crest has a free posterior border, which forms the anterior wall of the inferior lumbar trigone of Petit. This trigone is bounded anteriorly by the external abdominal oblique muscle, posteriorly by the latissimus dorsi, and inferiorly by the iliac crest. It is a weak zone in the abdominal wall can that tends to herniate (Petit's hernia), and the hernial sac is usually broad and less likely to incarcerate.

Three different groups of arteries were identified in a study conducted by Schlenz et al. [18] as the sources of blood supply to the external abdominal oblique. The cranial part of this muscle is supplied by the intercostal arteries. In 94.7 % the deep circumflex iliac artery and in 5.3 % the iliolumbar artery is responsible for the blood supply to the caudal of the muscle. The lateral branches of these arteries run on the outer surface of the muscle, while the anterior branches enter the muscle from its inner surface. Arterial injection studies conducted by Kuzbari et al. [19] have also confirmed the significant contribution of the deep circumflex iliac artery to the blood supply of the external abdominal oblique muscle.

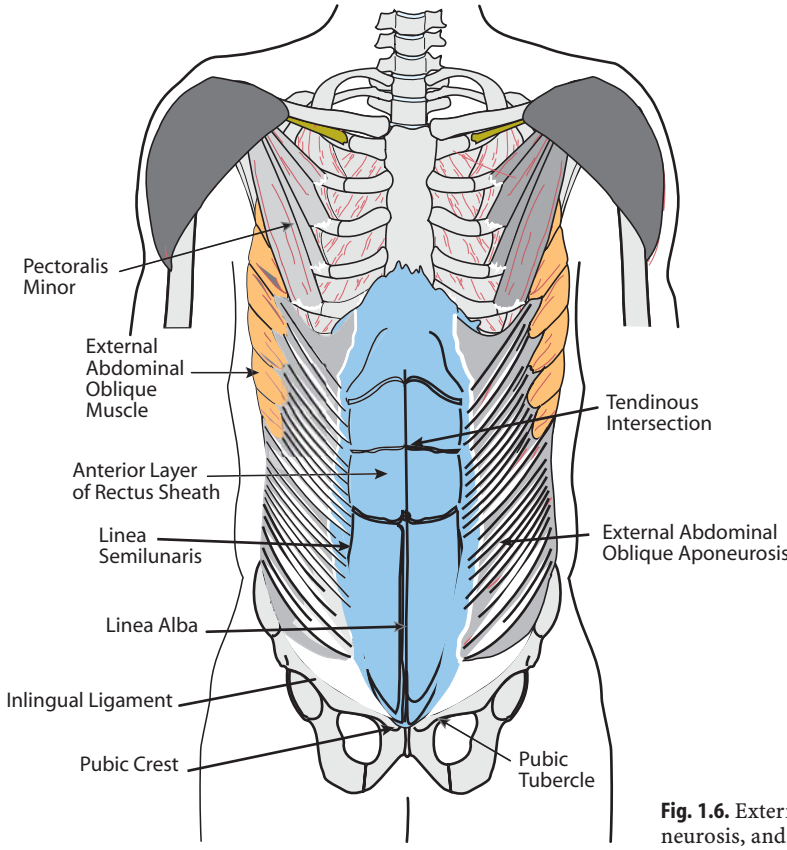

Fig. 1.6. External abdominal oblique muscle and aponeurosis, and inguinal ligament

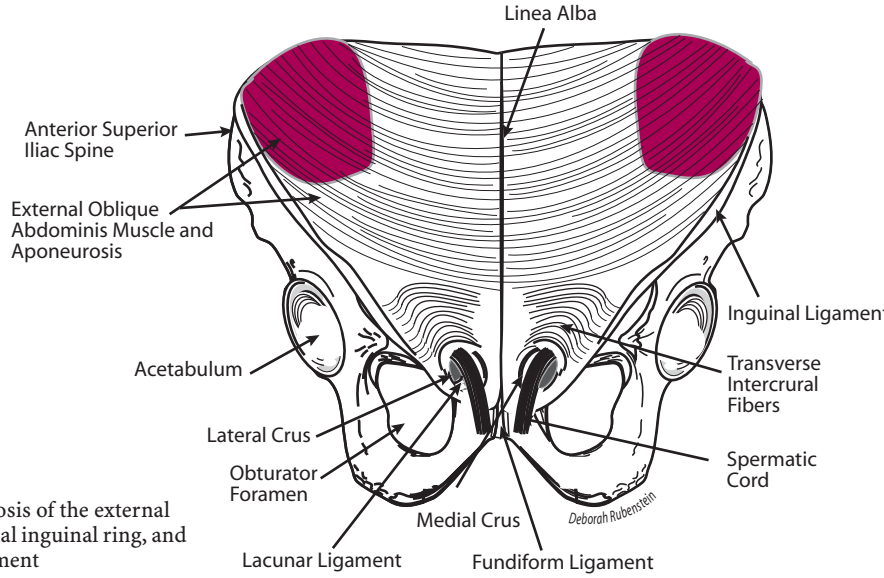

Fig. 1.7. Aponeurosis of the external oblique, superficial inguinal ring, and the inguinal ligament

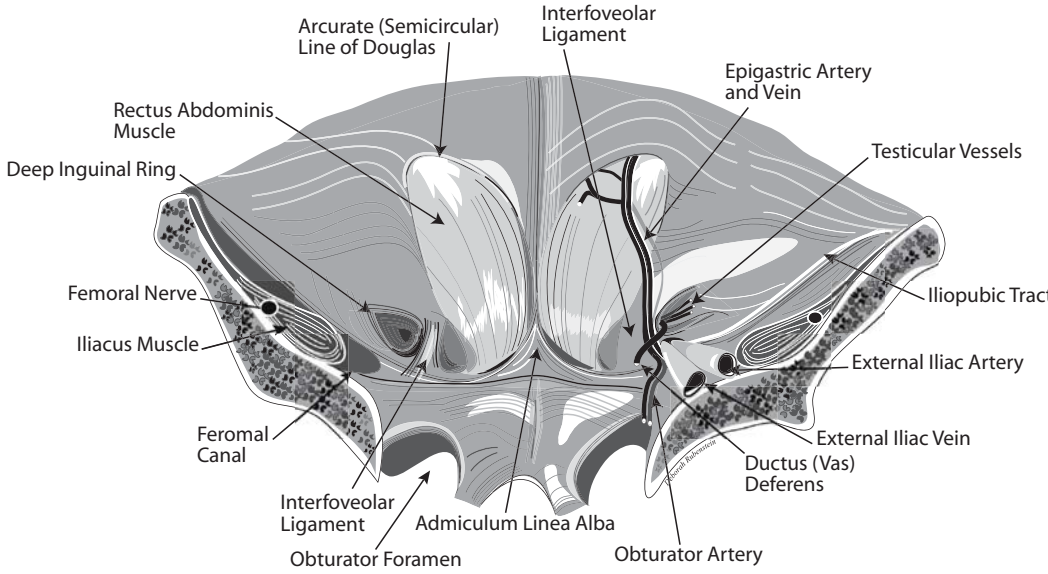

Fig. 1.8. Deep inguinal ring, epigastric vessels, and the structures that pass posterior to the inguinal ligament

The aponeurosis of the external abdominal oblique (Fig. 1.7) runs anterior to the rectus abdominis and joins the aponeurosis of the internal and transverse abdominis at the linea alba. The linea alba is a tendinous midline raphe that extends between from the xiphoid process to the symphysis pubis and pubic crest. It is wider above the umbilicus, separating the recti completely. However, this demarcation may not be easily felt inferior to the umbilicus. As a fibrous structure, it is virtually a bloodless line along which a surgical incision can be made. The triangular part of the linea alba that attaches to the pubic crest is known as the adminiculum linea alba (Fig. 1.8).

Inferiorly, the external oblique aponeurosis attaches to the pubic tubercle, pubic symphysis and crest. The aponeurosis infolds backward and slightly upward upon itself between the anterior superior iliac spine and the pubic tubercle to form the inguinal (Poupart) ligament (Figs. 1.6, 1.7). This ligament, which measures approximately 15 cm, marks the transition between the abdominal wall and thigh. Its curved surface constitutes the floor of the inguinal canal, and maintains an oblique angle to the horizontal.

The reflected part of the inguinal ligament is represented by the fibers of the external oblique aponeurosis that course superiorly and medially to join the rectus

sheath and linea alba (Figs. 1.9, 1.10). This ligament extends from the lateral crus of the superficial inguinal ring toward the linea alba anterior to the conjoint tendon.

A medially and horizontally aligned extension of the inguinal ligament, which is best seen from the abdominal side, extends posterolaterally to attach to the medial end of the pecten pubis and is known as the lacunar (Gimberant's) ligament (Figs. 1.7, 1.8). This triangular ligament (pectineal part of the inguinal ligament) measures 2 cm from base to apex, and forms the medial border of the femoral canal, separating it from the femoral vein. A second lacunar ligament, known as the fascial lacunar ligament, can be seen as an extension of the fascia lata that joins the inguinal ligament, pectineal fascia and the periosteum of the pecten pubis, and receives fibers from the transversalis fascia. The fascial lacunar ligament forms a thickening around the femoral sheath. It is approximately 1 cm anterior and inferior to the pecten pubis and 3 cm lateral to the pubic tubercle.

The superficial inguinal ring (Fig. 1.7), the outer opening of the inguinal canal, appears superior to the inguinal ligament and superolateral to the pubic tubercle. Although the superficial inguinal ring does not as a rule stretch beyond the medial third of the inguinal ligament, it shows some variation in size. In the female it is usually much smaller, accommodating the thin round ligament. The base of the superficial inguinal ring is at the pubic crest and its sides are formed by the medial and lateral crura. The thin medial crura interdigitate anterior to the symphysis pubis while the much stronger lateral crus attaches to the pubic tubercle. Intercrural fibers cross the apex of the superficial inguinal ring and resist widening of this gap. As the spermatic cord passes through the superficial inguinal ring, it rests upon the lateral crus and becomes invested by the external spermatic fascia, which is an extension of the external abdominal aponeurosis.

A robust fibrous band, the Cooper's ligament, extends laterally along the sharp edge of the pecten pubis and connects the base of the lacunar ligament to the pecten pubis. It receives fibers from the pectineal fascia and adminiculum albae (lateral extension from the lower end of the linea alba) and is considered as a firm structure to which sutures can be anchored. The findings of Faure et al. [20] and Rousseau et al. [21] emphasized the role of the ligament of Cooper in laparascopic surgery of the inguinal region and female urinary incontinence. They confirmed the fact that this ligament is a thickening of the pectineal fascia rather than the periosteum. In McVay's technique of repair of inguinal hernia [22, 23], the Cooper's ligament is sutured to the transversalis fascia. The close proximity of this ligament to the femoral vessels must always be remembered.

As the inguinal ligament runs from the anterior superior spine toward the pubic tubercle, it leaves a posterior gap occupied by vessels and nerves that supply the thigh (Fig. 1.8). This gap is divided by the iliopectineal arch, a septum continuous with the iliopsoas fascia and inguinal ligament into vascular (lacuna vasorum) and muscular (lacuna musculorum) compartments. The vascular compartment contains the femoral vein and artery, and the femoral ring, whereas the muscular compartment encloses the femoral nerve and iliopsoas muscle.

1.10 Innervation

The external oblique muscle receives innervation from the anterior primary divisions of the lower five or six intercostal nerves.

1.10.1 External Oblique Muscle

1.10.1.1 Action

Contraction of the external abdominal oblique muscle flexes the vertebral column and helps to rotate the thorax and pelvis. It depresses the thorax in expiration, and supports the abdominal viscera. Other abdominal muscles share many of these actions.

1.10.2 Internal Abdominal Oblique Muscle

The internal abdominal oblique (Figs. 1.9, 1.10) muscle is much thinner and lies deep to the external abdominal oblique. It arises from the iliac crest and the lateral two-thirds of the inguinal ligament, as well as from the thoracolumbar fascia. Fibers of this muscle, particularly those from the iliac crest and thoracolumbar fascia, pursue a reverse course perpendicular to that of the external abdominal oblique, extending for the most part upward and medially.

The part of the muscle that originates from the inguinal ligament becomes aponeurotic and arches over the spermatic cord in the male, or the round ligament in the female. It joins the aponeurosis of the transverse abdominis muscle anterior to the rectus abdominis muscle to form the conjoint tendon (falx inguinalis). It attaches to the pubic crest and for a variable distance to the medial part of the pecten pubis. In the Bassini technique of herniorrhaphy [24–26], the conjoint tendon is sutured to the transversalis fascia and the reflected part of the inguinal ligament. The conjoint tendon joins medially the anterior wall of the rectus sheath and unites laterally with the interfoveolar ligament, an inconstant fibrous

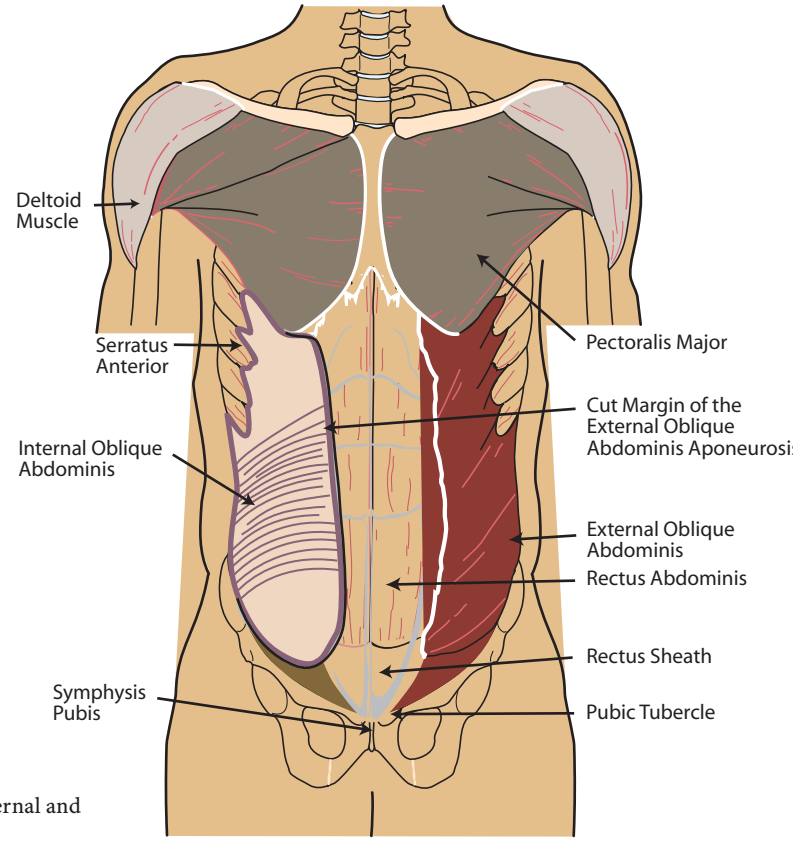

Fig. 1.9. Direction of the fibers of the external and internal abdominal oblique muscle

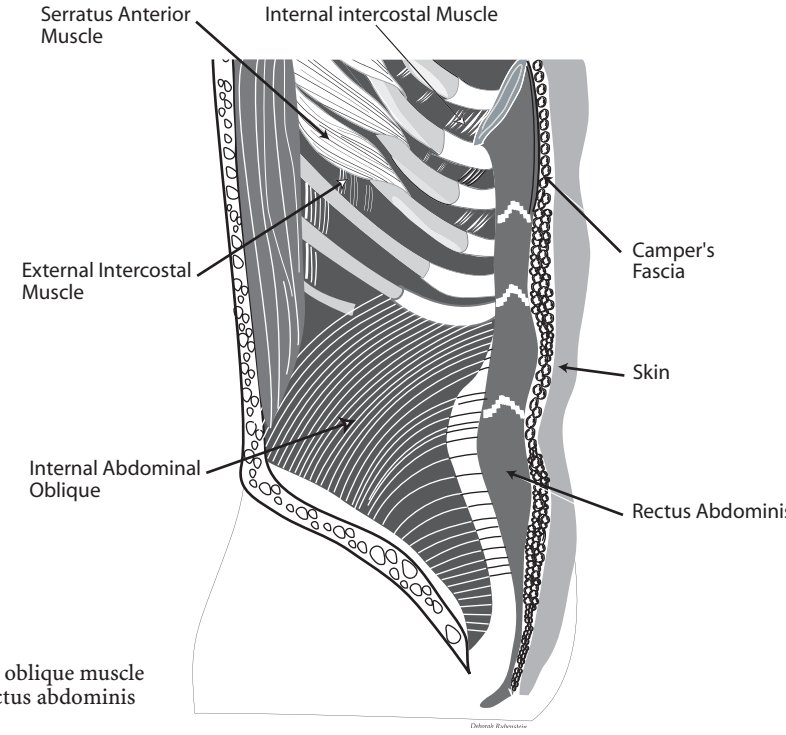

Fig. 1.10. Fibers of the internal abdominal oblique muscle and aponeurosis in relationship to the rectus abdominis muscle

band that connects the transverse abdominis to the superior pubic ramus. However, variations do exist in regard to the extent of attachment of the conjoint tendon and its structural characteristics. The part of the tendon that inserts on the pecten pubis extends posterior to the superficial inguinal ring, forming a natural barrier that prevents the occurrence of inguinal hernia. A direct inguinal hernial pouch may pass through this tendon, acquiring the coverings of this structure.

The posterior fibers of the internal abdominal oblique muscles that gain origin from the iliac crest extend upward and laterally to the inferior border of the lower three or four ribs, continuing with the internal intercostal muscles. They become aponeurotic towards the midline and contribute to the formation of the linea alba by joining the aponeurosis of the flat abdominal muscles of the same and opposite side.

Superior to the midpoint between the umbilicus and the symphysis pubis (upper two-thirds), the internal oblique aponeurosis divides into two layers. The anterior layer covers the anterior surface of the rectus abdominis and the posterior layer invests the posterior surface of the rectus abdominis. Distal to this site (lower one-third), the aponeurosis of the internal oblique remains a single layer anterior to the rectus abdominis (Fig. 1.11).

The loosely arranged fasciculi of the internal oblique muscle and its aponeurosis, which extend around the spermatic cord and testis, constitute the cremasteric muscle and fascia that invariably receive fibers from the transverse abdominis. The cremasteric, a striated muscle with a lateral and a medial part, is an involuntary muscle innervated by the genital branch of the genitofemoral nerve (L1, L2). The lateral part is thicker, directly arises from the inguinal ligament, and extends to the anterior superior iliac spine. The medial part of the internal abdominal oblique, which is sometimes absent, arises from the pubic tubercle, conjoint tendon, and possibly the transverse abdominis.

From the inferior edge of the internal abdominal oblique, the cremasteric muscle and fascia loop over the spermatic cord and testis to terminate at the pubic tubercle and merge with the anterior layer of the rectus sheath. This muscle is considered to have internal and external components separated by the internal spermatic fascia [27]. Redman [28] concluded that exposure of the inguinal canal and deep inguinal ring in hernial repair is greatly enhanced by careful dissection of the cremasteric muscle and fascia.

In the female, the round ligament is invested by the sporadic fibers from the lateral part of the cremasteric muscle. Contraction of the cremasteric muscle mediates the cremasteric reflex, a brisk reflex, particularly in children, which involves elevation of the testicles towards the superficial inguinal ring upon stimulation of the inner thigh.

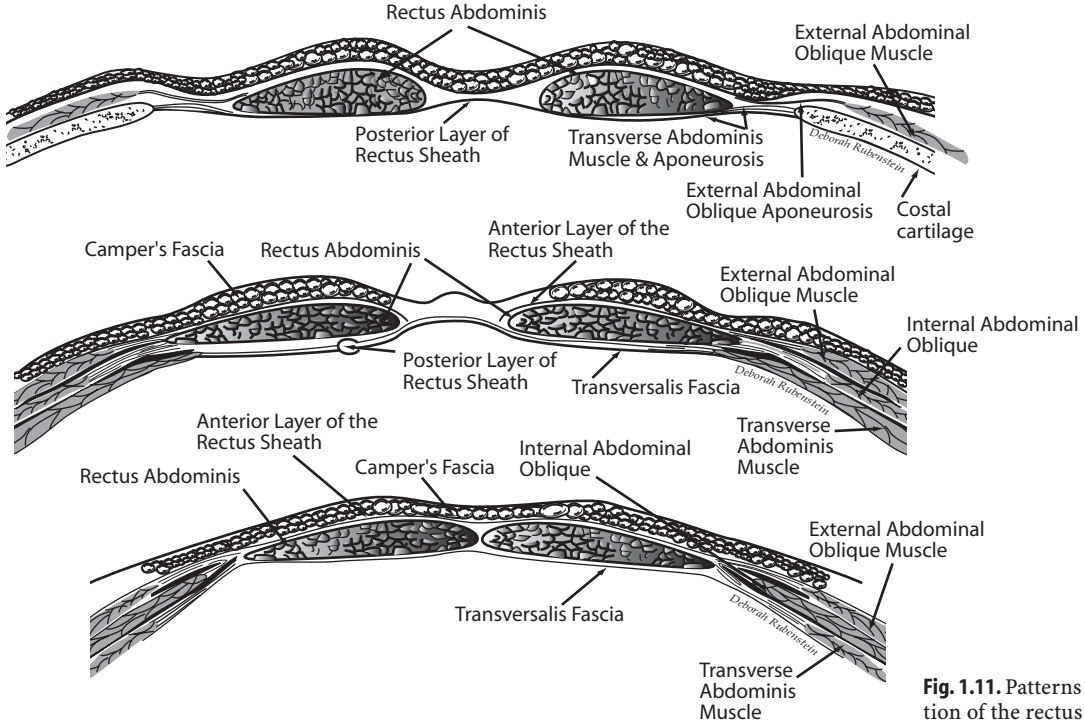

Fig. 1.11. Patterns of lamination of the rectus sheath

1.10.2.1 Action

Bilateral contraction of the external abdominal oblique muscles, in conjunction with the internal oblique and rectus abdominis, produces flexion of the vertebral column. Ipsilateral contraction of the external and internal abdominal oblique muscles produces abduction of the trunk (lateral flexion to the same side). Contraction of the external abdominal oblique on one side and the internal oblique on the opposite side results in rotation of the lumbar vertebral column.

1.10.2.2 Innervation

The internal abdominal oblique is innervated by the ventral rami of the lower six intercostal, iliohypogastric and ilioinguinal nerves.

1.10.3 Transverse Abdominis Muscle

The transverse abdominis (Figs. 1.2, 1.12–1.16) is a wide thin muscular layer that assumes a nearly hori-

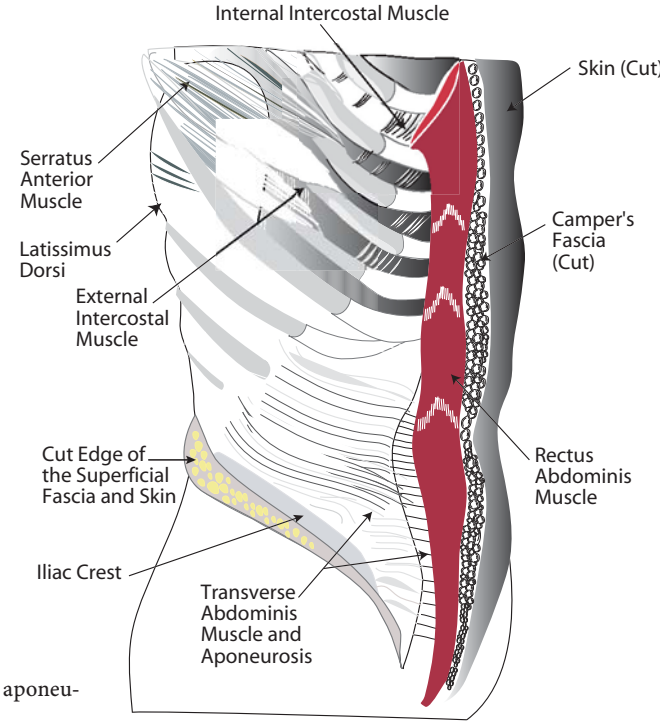

Fig. 1.12. Transverse abdominis muscle and aponeurosis

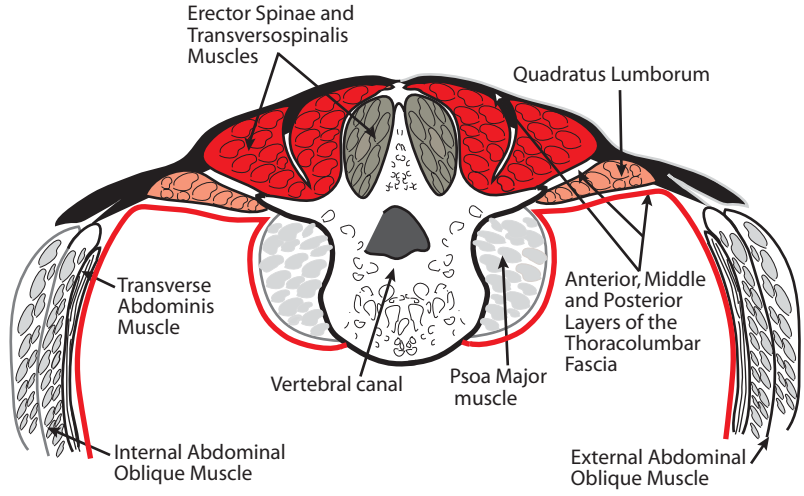

Fig. 1.13. Cross section of the posterolateral abdominal wall showing the external and internal abdominal oblique, transverse abdominis, and the thoracolumbar fascia

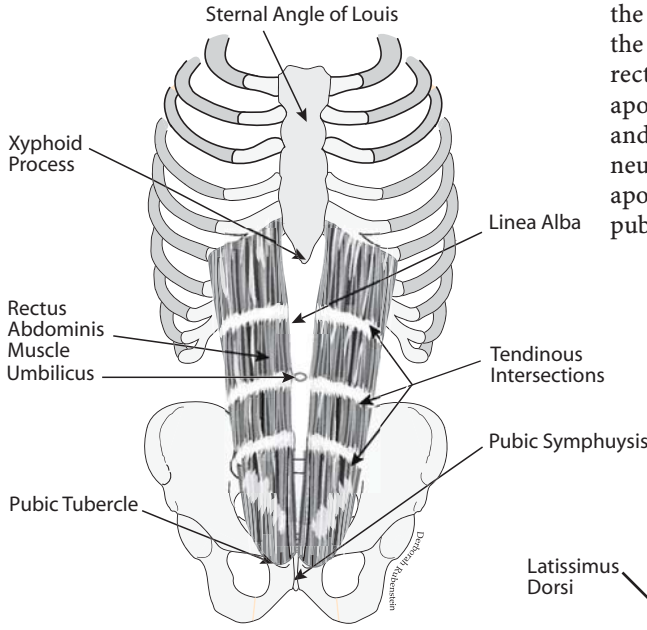

Fig. 1.14. Proximal and distal attachments of the rectus abdominis

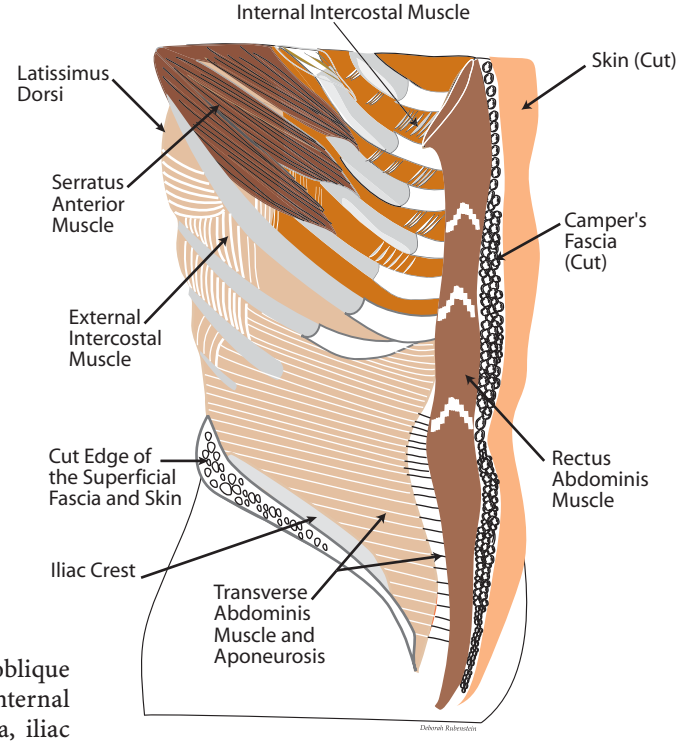

▷
Fig. 1.15. Rectus abdominis muscle in relation to the transverse abdominis and superficial fascia of the abdomen

zontal course deep to the internal abdominal oblique muscle. It maintains a similar origin to the internal oblique, arising from the thoracolumbar fascia, iliac crest and the lateral third of the inguinal ligament. The transverse abdominis receives additional origin from the inner surface of the lower five or six ribs, partly interdigitating with the origin of the muscular diaphragm. This muscle may be absent or fused with the internal abdominal oblique and may contain openings filled with fascia. It becomes aponeurotic as it approaches the lateral border of the rectus abdominis, blending with the linea alba. At the level of the xiphoid process, the transverse abdominis becomes aponeurotic near the linea alba, allowing the muscular part to pursue a course deeper to the rectus abdominis.

Superior to the midpoint between the umbilicus and symphysis pubis (upper two-thirds), the aponeurosis of the transverse abdominis joins the anterior layer of the aponeurosis of the internal abdominal oblique and the external oblique to form the anterior layer of the rectus sheath. Inferior to the midpoint, the transverse aponeurosis runs posterior to the rectus abdominis and anterior to the muscle. The lower fibers of the aponeurosis curve downward and medially and join the aponeurosis of the internal abdominal oblique at the pubic crest to form the conjoint tendon.

1.10.3.1 Innervation

This muscle is innervated by the ventral rami of the lower five or six intercostal nerves, as well as by the subcostal, iliohypogastric and ilioinguinal nerves.

1.10.3.2 Action

The effect of contraction of the transverse abdominis on the vertebral column is not clear, despite its role as a compressive force resisting intra-abdominal pressure.

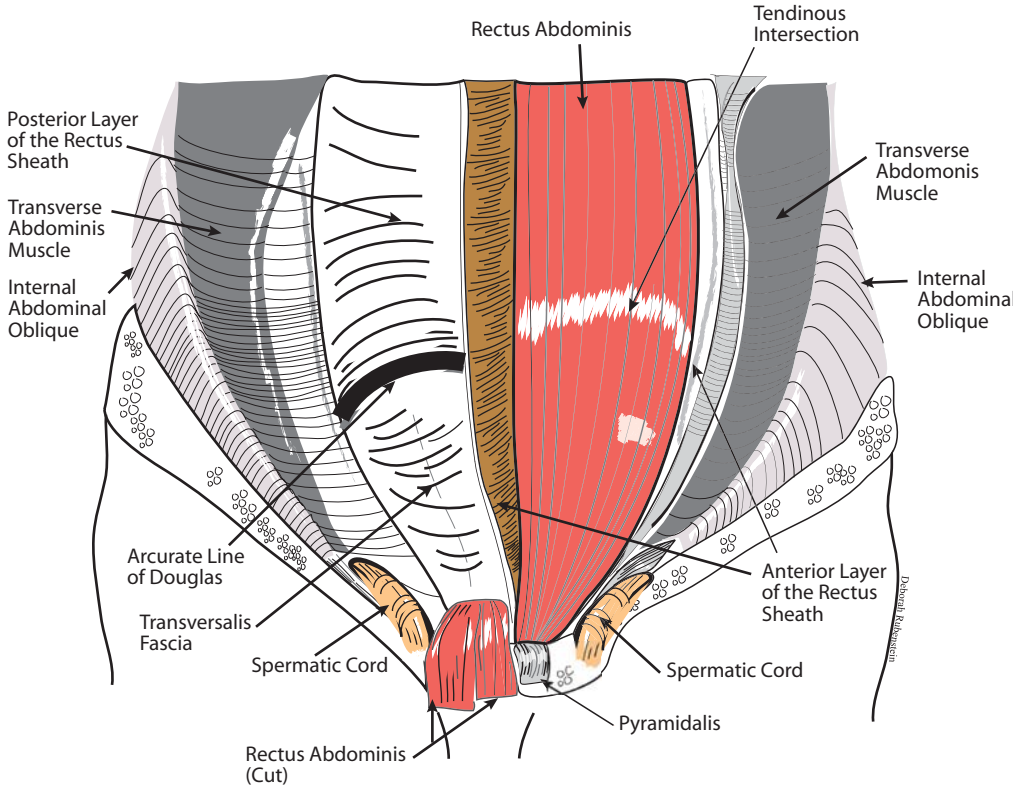

Fig. 1.16. Posterior layer of the rectus sheath, arcuate line of Douglas, internal abdominal oblique, and transverse abdominis

It is believed that the actions of the transverse abdominis are basically common to the internal and external abdominal oblique muscles. The transverse abdominis is believed to respond more to increases in chemical or volume-related drive than the rectus abdominis and external abdominal oblique. This is supported by neuroanatomical studies that have demonstrated many more inputs to, and outputs from, the motor neurons that innervate the transverse abdominis muscle than can be accounted for by its respiratory role [29].

1.10.4 Rectus Abdominis

The rectus abdominis (Figs. 1.5, 1.6, 1.8–1.10, 1.16), a paired longitudinal muscle on both sides of the midline, widens as it descends through the rectus sheath, maintaining distal and proximal attachments. Proximally, it attaches to the xiphoid process and the costal cartilages of the fifth through the seventh ribs. Distally it attaches via a medial tendon to the pubic symphysis, interlacing with the opposite muscle and via a lateral tendon to the pubic crest, extending to the pecten pubis and pubic tubercle. The site of intersection of the lateral border of the right rectus and costal arch marks the topographic location of the fundus of the gallbladder. The recti muscles are completely separated in the midline above the umbilicus by the linea alba and less so below it. Its lateral border forms the semilunar line, a curved groove that extends from the pubic tubercle to the ninth costal cartilage, which is particularly visible in muscular individuals. This muscle is usually interrupted by three transversely running tendinous intersections that assume a zigzag path and firmly adhere to the anterior layer of the rectus sheath. The upper tendinous intersection is usually near the xiphoid process; the lower one is at the level of the umbilicus and is segmentally related to the tenth rib and tenth intercostal nerve; and the middle one is found between the above intersections.

In order to gain access to the rectus abdominis, the rectus sheath should carefully be dissected off the rectus muscle and the associated segmental artery and vein are severed at each of the intersections. A paramedian incision that cuts through the anterior layer of the rectus sheath and rectus abdominis carries the advantage of protecting the sutured peritoneum when the rectus abdominis slips back into its proper anatomical position. Since this muscle receives innervation through its lateral border (Figs. 1.4, 1.5) by piercing the tendinous intersections, incisions immediately lateral to the rectus abdominis near the linea semilunaris can

carry a great risk of denervation and atrophy. Therefore, the rectus abdominis can surgically be transected anywhere other than the sites of these fibrous intersections, without possible threat of herniation. Cosmetic [30] results are greatly enhanced when the approximation of the recti muscles is combined with a flap advancement and rotation of the external abdominal oblique muscle.

The rectus sheath (Figs. 1.8, 1.11, 1.16) consists of the aponeuroses of the external and internal oblique and transverse abdominis muscles, exhibiting two primary patterns of laminations demarcated by the arcuate line of Douglas (Figs. 1.8, 1.16). This line corresponds to the midpoint between the umbilicus and the symphysis pubis. Proximal to the arcuate line the aponeuroses of the external abdominal oblique and the anterior layer of the internal abdominal oblique form the anterior layer of the rectus sheath. At this level, the posterior layer comprises the aponeuroses of the transverse abdominis and the posterior layer of the internal abdominal oblique as well as the transversalis fascia. Distal to the arcuate line, the anterior layer of the rectus sheath is formed by the combined aponeuroses of the external and internal oblique and the transverse abdominis. At this level, the posterior layer is only formed by the transversalis fascia that separates the rectus abdominis from the peritoneum.

Since the aponeuroses of the internal oblique and transverse abdominis only extend to the costal margin, the rectus abdominis above this level rests on the costal cartilages, and the anterior layer of the sheath at this level is formed only by the external oblique aponeurosis. Immediately below the costal margin, the transverse abdominis muscle extends posterior to the rectus muscle. The rectus sheath contains the pyramidalis muscle, the superior and inferior epigastric vessels and the terminal branches of the lower five or six intercostal nerves.

Although spontaneous hematoma into the rectus sheath as a result of a rupture of the epigastric vessels is rare in pregnancy, acute abdominal pain in the third trimester or at the beginning of the postpartum period should alert the surgeon for this very possibility [31, 32]. Diastasis recti, a symptomatic separation of the recti by a stretching or widening of the linea alba, is commonly associated with parturition.

1.10.4.1 Innervation

The rectus abdominis muscle is segmentally innervated by the ventral rami of the lower six or seven thoracic spinal nerves.

1.10.4.2 Actions

With the pelvis fixed, the recti act as flexors of the lumbar vertebral column; with the thorax fixed, they draw the pelvis upward. The recti come to action as flexors,

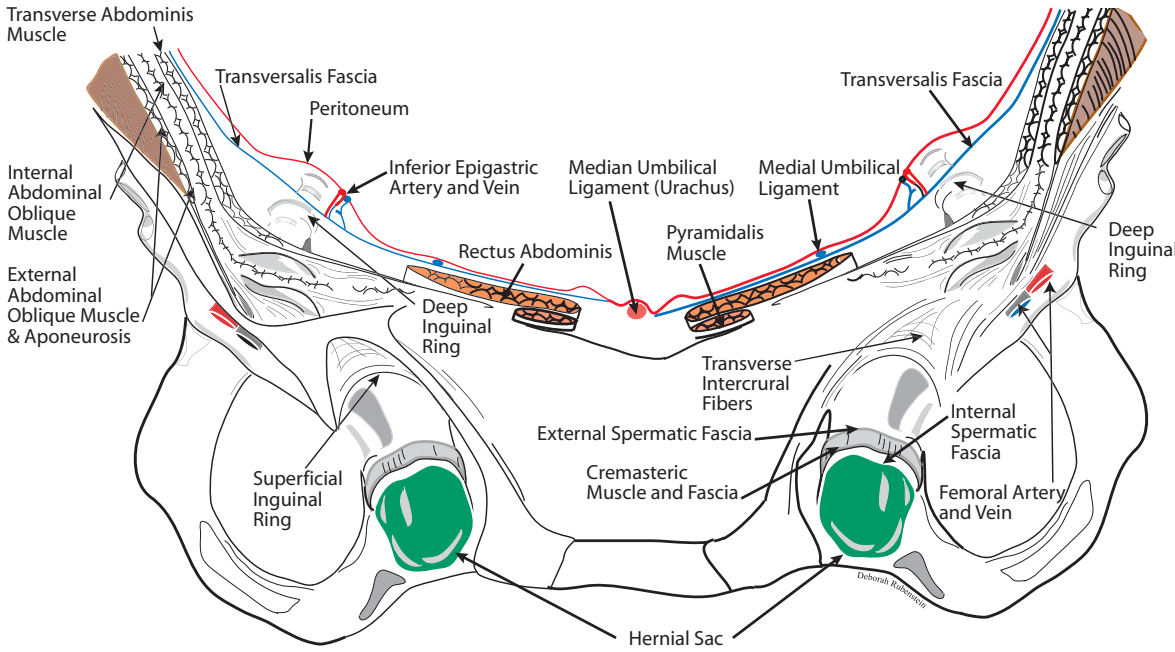

Fig. 1.17. Course of a hernial sac in the indirect inguinal hernia. Observe the inguinal canal, inferior epigastric vessels and the protruding hernial sac

particularly in the supine position, overcoming gravitational pull.

1.10.5 Pyramidalis Muscle

The pyramidalis (Fig. 1.17), an inconstant small muscle which is absent in approximately 25% of the population, originates from the symphysis pubis and pubic crest and inserts into the linea alba as far as one-third of the distance to the umbilicus. This triangular muscle lies anterior to the lower end of the rectus abdominis and becomes smaller and pointed as it ascends towards the junction of the linea alba and the arcuate line. Although the significance of this muscle is not clear, it is thought to tense the linea alba.

1.10.5.1 Innervation

The pyramidalis muscle is innervated by the subcostal nerve and occasionally by branches of the iliohypogastric and ilioinguinal nerves.

1.11 Transversalis Fascia

The transversalis fascia [33, 34] is a segment of the endoabdominal fascia that forms the lining of the entire abdominal cavity. It contributes to the posterior wall of the rectus sheath and contains the deep inguinal ring midway between the anterior superior iliac spine and the symphysis pubis. It lies between the transverse abdominis and the extraperitoneal fat and continues inferiorly with the iliac and pelvic fascia and superiorly with the fascia on the inferior surface of the diaphragm. Although it is a very thin layer on the inferior surface of the diaphragm, it shows some thickening in the inguinal region. In the posterior abdominal wall it joins the anterior layer of the thoracolumbar fascia. The transversalis fascia attaches to the iliac crest and to the posterior margin of the inguinal ligament as well as to the conjoint tendon and the pecten pubis. Its prolongation around the spermatic cord, known as the internal spermatic fascia, fuses with the parietal layer of the tunica vaginalis. It blends with the iliac fascia as it forms the anterior layer of the femoral sheath.

Anterior to the femoral vessels, the transversalis fascia is augmented by the transverse crural arch, a horizontally disposed layer that descends to attach medially to the pecten pubis and laterally to the anterior superior iliac spine. The transverse crural arch plays an important role in strengthening the medial and inferior margins of the deep inguinal ring. Menck and Lierse [35] have demonstrated that the transversalis fascia consists of an internal and an external layer; the internal layer contributes to the sphincteric mechanism that reduces the size and strengthens the deep inguinal ring. The role of the transversalis fascia in inguinal hernial repair and reinforcement of the dorsal wall of the inguinal canal has been suggested by Morone et al. [36] and Witte et al. [37]. The study conducted by Teoh [38] confirmed the presence of the iliopubic tract as a thickening of the transversalis fascia that runs parallel to the inguinal ligament and believed to be a significant structure in various approaches to repair of inguinal hernia. It attaches to the superomedial part of the pubic bone medially, but laterally it joins the iliac fascia with no bony attachments.

1.12 Extraperitoneal Fatty Tissue

The extraperitoneal tissue (subserous fascia) is a generally thin connective tissue layer that occupies the area between the peritoneum and the transversalis fascia in the abdomen, and between the peritoneum and the endopelvic fascia in the pelvis. It is loose and fatty in the lowest portion, allowing for the expansion of the bladder. The potential space represented by this loose preperitoneal layer, the space of Bogros, is used for the placement of prostheses in the repair of inguinal hernia. This layer is particularly thick and fatty in the posterior abdomen as it surrounds the major vessels and also the kidney to form the perinephric renal capsule. The extraperitoneal tissue also shows thickening around the iliac crest and pubic bone.

1.13 Peritoneum

The peritoneum is part of the coelomic cavity that becomes separated from the pleural cavities by the development of the diaphragm. The free surface of this extensive membrane is covered by a layer of mesothelium, saturated by a thin film of serous fluid. The peritoneum is a serous membrane that resembles, but is much more complicated than, the pleura essentially due to the fact that in the course of fetal development rotations of the gut allow certain parts of the abdominal viscera to variably invaginate into the peritoneum. However, this process does not occur in the thoracic cavity and the pleura maintains a much simpler arrangement. In general the peritoneum consists of parietal and visceral layers separated by the peritoneal cavity. The parietal layer forms the lining of the abdominal walls and the diaphragm separated from the transversalis fascia by an extraperitoneal connective tissue. Although loosely attached to the abdominal wall, it is

denser and firmly adherent to the linea alba and inferior surface of the diaphragm. It converts the umbilical ligaments into folds. The median umbilical fold covers the urachus, an embryological remnant of the allantois, which is connected to the apex of the urinary bladder. The medial umbilical fold, located lateral to the median umbilical fold, is formed by the (upper) obliterated part of the umbilical artery. The lower (non-obliterated) part of the umbilical artery remains functional in the adult. The lateral umbilical (epigastric) fold is located lateral to the medial umbilical fold, covering the inferior epigastric vessels.

Since the lower five intercostal nerves and branches of the first lumbar spinal segment innervate the skin, muscles and also the parietal peritoneum, peritonitis may stimulate these nerves, thereby producing pain, involuntary spasmodic contraction of all abdominal muscles, and palpable rigidity (guarding). These important manifestations signify inflammation of the parietal peritoneum.

In contrast, the visceral peritoneum invests the abdominal viscera to various degrees. An organ which is completely invested by the visceral peritoneum is considered an intraperitoneal organ. Intraperitoneal organs include the spleen, stomach, initial part of the duodenum, tail of the pancreas, jejunum, ileum, transverse colon, and sigmoid colon. Conversely, a retroperitoneal organ is covered by the peritoneum anteriorly and laterally or only anteriorly. Retroperitoneal organs include the kidney, ureter, suprarenal gland, inferior vena cava, abdominal aorta, ascending and descending colon, most of the duodenum, and the rectum.

The visceral peritoneum is innervated by sympathetic and parasympathetic fibers. Since sympathetic fibers are the principal carriers of visceral pain, inflammation of the visceral peritoneum produces referred pain in the dermatomes that correspond to the segmental sympathetic innervation of the affected organs.

1.14 Inguinal Canal

The inguinal canal [39] is an oblique tunnel that borders the anterior thigh and extends from the superficial to the deep inguinal ring, running parallel to and above the inguinal ligament. It develops between the 5th and the 32nd week of prenatal life, initially as the processus

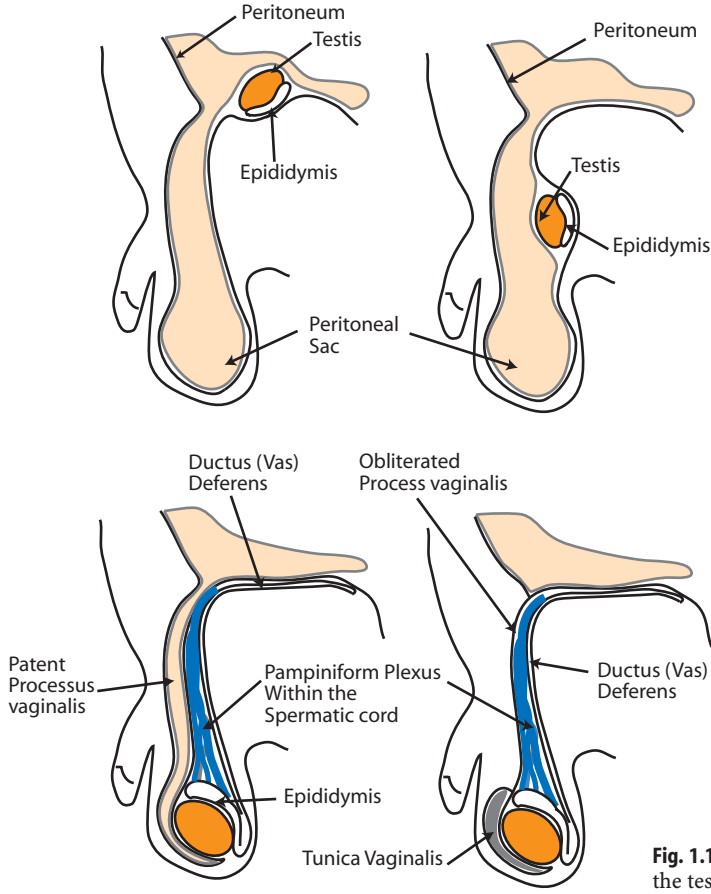

Fig. 1.18. Formation of the process vaginalis, descent of the testis, and the spermatic cord

vaginalis, a peritoneal evagination that extends into the transversalis fascia. The processus vaginalis (Fig. 1.18) eventually loses its connection with the peritoneal cavity of the abdomen and persists as a double-walled serous layer, the tunica vaginalis, anterior and lateral to the testis. The transversalis fascia continues with the internal spermatic fascia in the form of a tubular sheath that travels forward, first by passing between the arched fibers of the aponeuroses of the transverse abdominis and internal abdominal oblique abdominis, and finally through the external abdominal oblique aponeurosis (Fig. 1.19). During the passage of the processus vaginalis and internal spermatic fascia through the aponeuroses of the internal and external abdominal oblique, they acquire additional coverings from the cremasteric muscle and fascia, and the external spermatic fascia.

The triangular gap proximal and lateral to the pubic crest that marks the continuation of the external spermatic fascia with the external abdominal oblique aponeurosis is known as the superficial inguinal ring. This opening, formed by a division of the fibers of the external abdominal oblique aponeurosis, is bounded by medial and lateral crura. The medial crus passes superomedially to join with the corresponding fibers of the contralateral side. The fibers of the lateral crus extend inferolateral to the superficial inguinal ring, forming the medial end of the inguinal ligament. Variable fibrous strands that run across the upper part of the superficial inguinal ring form the intercrural fibers. These fibers play a role in strengthening the superficial inguinal ring and preventing further splitting of the fibers of the external oblique aponeurosis.

The deep inguinal ring is a funnel-shaped opening in the transversalis fascia; it is located lateral and superior to the inferior epigastric vessels, and inferior to the arched lower margin of the aponeurosis of the transverse abdominis. Although size variations do exist, the deep inguinal ring is almost always larger in the male to accommodate the spermatic cord and its components. It is approximately 2.54 cm above the midpoint of the inguinal ligament, corresponding to the site of passage of the femoral artery under the inguinal ligament. The precise location of the deep inguinal ring as 0.52 cm lateral to the midinguinal point and 0.46 cm medial to the midpoint of the inguinal ligament has been documented by Andrews et al. [40]. Neither the midinguinal point nor the midpoint of the inguinal ligament can accurately predict the position of the deep inguinal ring.

The force exerted by the contraction of the internal abdominal oblique muscle on the margins of the deep inguinal ring may play an important role in preventing herniation. The oblique direction of the inguinal canal, the strength of the abdominal muscles, and the traction exerted by the internal oblique abdominis muscle during strenuous activity appear to compensate for weakness of the anterior abdominal wall. Presence of the conjoint tendon and the reflected inguinal ligament directly posterior to the superficial inguinal ring also play an important role in counteracting the weakness in the inguinal area. Contraction of the abdominal muscles forces the wall of the inguinal canal to collapse and thus act as a safety valve, preventing the occurrence of hernia in normal individuals.

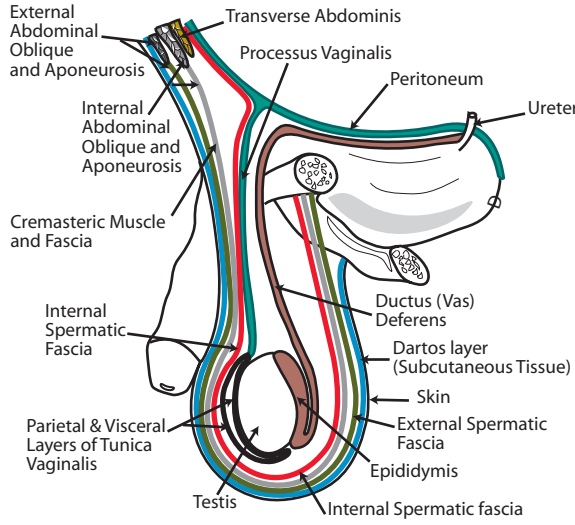

Fig. 1.19. Coverings of the testis and spermatic cord

The inguinal canal is bounded superiorly (on its roof) by the arched lower free fibers of the internal abdominal oblique and the transverse abdominis muscles and inferiorly (on its floor) by a combination of the inguinal and lacunar ligaments and the transversalis fascia. It is enclosed anteriorly by the aponeurosis of the external and abdominal internal oblique muscles and posteriorly by the transversalis fascia, falx inguinalis, and the reflected inguinal ligament. This canal contains the spermatic cord and ilioinguinal nerve in the male, and the round ligament of the uterus and ilioinguinal nerve in the female.

In the male (Fig. 1.18), descent of the gonads from the posterior abdominal wall follows the gubernaculum hunteri [41], a mesenchymal tissue that extends from the posterior abdominal wall to the deep inguinal ring. The processus vaginalis, guided by the gubernaculum, protrudes through the deep inguinal ring and descends to the scrotum, as additional fascial coverings are added to it. Variations in the attachments of the gubernaculum to the testis may determine the location of the testis. A recent study [42] found the proximal portion of the gubernaculum to be attached to the testes and epididymis in all fetuses that did not exhibit congenital malformations or epididymal alterations, such as tail disjunction or elongated epididymis. In undescended (cryptorchid) testes, an increased incidence of

gubernacular attachment anomalies was accompanied by paratesticular structural malformations compared to the testes of normal fetuses. Cryptorchid testes are frequently located in the inguinal canal, sometimes in the femoral canal and suprapubic region (at the base of the penis), and rarely found in the contralateral scrotum or perineal region [43]. Tanyel et al. [44] reported neurogenic changes within all cremasteric muscles of boys with cryptorchid testis.

In the female, the gonads follow a much shorter course, and the gubernaculum attaches to the ovary and the uterus during its descent toward the anterolateral abdomen. The portion of the gubernaculum that connects the ovary to the uterus becomes the proper ovarian ligament. The remaining part, which extends through the anterolateral abdomen, develops into the round ligament of the uterus that travels through the inguinal canal to the major labium. Since the round ligament attaches to the anterolateral abdomen before the inguinal canal is completely formed, it does not have the same fascial coverings as the processus vaginalis in the male. In the female, the coverings are so thin that they are indistinguishable from the round ligament itself.

In the male, obliteration of the processus vaginalis, and thus the connection between the peritoneal cavity in the abdomen and scrotum, is usually complete at birth. However, this process may begin late, and when it does, it becomes completed by the first few weeks of postnatal life. Closure begins at the deep inguinal ring and extends downward to involve all the intervening regions.

The only postnatal remnant of the processus vaginalis is a closed sac anterior and lateral to the testis, known as the tunica vaginalis. Failure of the processus vaginalis to close (patent processus vaginalis) may allow part of the abdominal viscera to protrude through the deep inguinal ring and follow the course of the inguinal canal to the superficial inguinal ring, producing an indirect inguinal hernia. Kahn et al. [45] published a report that objectively confirms that presence of a patent processus vaginalis is not a prerequisite to the development of indirect inguinal hernia.

The tunica vaginalis (Fig. 1.18) consists of visceral and parietal layers separated by a cavity that contains a thin film of fluid. Accumulation of fluid in this cavity produces hydrocele, a condition that exhibits transilluminating scrotal swelling anterior to the testis. Hydrocele can be a primary (idiopathic) or secondary condition. A primary hydrocele is usually large and rigid, occurs over the age of 40, and develops slowly. A secondary hydrocele tends to occur in younger individuals as a sequel to inflammation or tumors of the testis. A congenital hydrocele associated with indirect inguinal hernia is usually large and full during the day and shrinks during the night. A spermatic cord hydrocele tends to move downward when traction is applied to the testis.

The blood supply, venous and lymphatic drainage, and innervation of the testis are associated with the posterior abdominal wall and are contained within the spermatic cord (Figs. 1.7, 1.18, 1.19). This cord is a composite bundle that contains the vas deferens (ductus deferens), testicular artery, pampiniform venous plexus, deferential artery, and the genital branch of the genitofemoral nerve. It is covered by the external spermatic fascia, cremasteric muscle and fascia and the internal spermatic fascia. Separation of the vas deferens and associated vessels within the spermatic cord from the processus vaginalis and attainment of inguinal orchiplexy can successfully be accomplished by division of the internal spermatic fascia [46].

The vas deferens (Figs. 1.18, 1.19), a cord-like structure rich in smooth muscle fibers, begins as a direct continuation of the tail of the epididymis and ascends in the center of the spermatic cord, entering the abdominal wall via the superficial inguinal ring. Subsequent to its course through the deep inguinal ring into the pelvis, it joins the duct of the seminal vesicle to form the ejaculatory duct. Bilateral congenital absence of the vas deferens is associated with azoospermia and may determine the likelihood of cystic fibrosis [47].

The testicular artery (Fig. 1.19) emanates from the abdominal aorta and descends anterior to the ureter, coursing within the inguinal canal to supply the testis. The angle between the ductus deferens and the testicular vessels, and the thickness of the adjacent tissue around the deep inguinal ring, show great variations. This angle, which constitutes the apex of what is called the "triangle of doom", may be used as a point of reference to predict the position of the ductus deferens, thereby preventing accidental surgical stapling of the underlying external iliac vessels during herniorraphy [48]. The thickness of the peritoneum, transversalis fascia, and intervening connective tissue is greatest lateral to the testicular vessels and least over the ductus deferens.

The deferential artery, a branch of the inferior vesical artery, forms an extensive anastomosis with the testicular and the cremasteric arteries. The cremasteric artery arises from the inferior epigastric artery and supplies the cremasteric muscle and fascia. The pampiniform plexus (Fig. 1.18) travels through the inguinal canal and gives rise to a number of veins that coalesce to form the right and left testicular veins, which drain into the inferior vena cava and the left renal vein, respectively. Dilation of the pampiniform plexus produces varicocele, a condition that is usually visible when standing or straining. It is associated with defective valves in the plexus, thrombosis of the left renal vein, renal diseases, and rarely with superior mesenteric artery syndrome.

The round ligament of the uterus, a remnant of the gubernaculum, follows the inguinal canal from the

deep to the superficial inguinal ring and eventually reaches the major labium. It is considerably stretched during pregnancy and maintains the anteverted position of the uterus. The wall of this ligament contains great numbers of smooth muscle fibers near the uterus; these diminish toward the deep inguinal ring, converting into fibrous strands as it reaches the major labium. The round ligament courses diagonally within the mesometrium toward the pelvic floor anterior to the external iliac, obturator, and vesical vessels, and the obliterated umbilical artery. The round ligament allows some lymphatics from the cervix and fundus of the uterus to follow its course to the superficial inguinal lymph nodes.

1.15 Abdominal Hernias

A hernia, meaning "sprouting forth", is an outpouching of a visceral organ or a part of organ through an opening that it does not normally transverse. When hernias are associated with the abdomen, they may occur through the inguinal canal, lumbar trigone of Petit, femoral canal, or umbilicus. Nerve damage and weakening of the muscles, as a postsurgical complication, may lead to herniation. A variety of other situations such as pregnancy, constipation, peritoneal dialysis, ascites, and asthma may predispose an individual to herniation. Each hernia consists of a sac, usually a diverticulum of the parietal peritoneum that invests the hernial contents, and a protruded tissue or organ with its coverings. The proximal tapered end of the sac that marks the site of herniation is known as the neck of the hernial sac. Although the ratio of the length of the inguinal canal to the circumference of the hernial sac may define the clinical picture best, this parameter cannot be the sole determinant of the clinical outcome. Abdominal wall hernias are usually asymptomatic, discovered incidentally on routine physical examination. However, complications of abdominal hernia may be life threatening and require urgent medical attention.

1.15.1 Inguinal Hernia

The bony attachments of the inguinal region counteract abdominal thrust, and the presence of natural gaps that exist in this region may allow peritoneal diverticula to externalize and appear as hernias. Inguinal hernia sac, which represents approximately 95 % of abdominal wall hernias in the male and 50 % in the female, has the highest incidence of onset in the 1st year of life followed by a second peak between the ages of 16 and 20. Hernial sac traverses the entire length of the inguinal canal from the deep to the superficial inguinal ring. It may also pursue a much shorter path, passing only through the superficial inguinal ring. The hernial sac appears above and medial to the pubic tubercle. Herniation that follows the entire length of the inguinal canal is an indirect inguinal hernia; it commonly results from persistent processus vaginalis and therefore is known as an indirect (congenital) inguinal hernia. The Hessert's triangle, formed by the intersection of the aponeurosis of the internal oblique and transverse aponeuroses and the rectus sheath, may play an important role in the etiology of the inguinal hernia [49]. This triangle may be occluded upon contraction of the abdominal muscles and by their movement toward the inguinal ligament. However, when a larger triangle exists, the occlusion cannot be complete, a condition that leads to herniation.

Inguinal hernia is often asymptomatic, but some patients, particularly the middle-aged and elderly, experience aching pain in the lower abdominal quadrants that radiates to the medial thigh. Others relate the sudden occurrence of the condition to strenuous activity. Patients may report an intermittent, reducible or nonreducible groin mass. In infants, it is thought that thickening of the spermatic cord at the superficial inguinal ring on one side is an important sign of an inguinal hernia. The infrequent occurrence of inguinal hernia in the female is commonly attributed to the small size of the superficial inguinal ring and the fatty composition of the major labium.

Laparoscopic procedures in the repair of inguinal hernia have produced an increase in the frequency of debilitating neuropathies, most notably those of the genitofemoral, ilioinguinal, and lateral femoral cutaneous nerves. The highly variable course of the lateral femoral cutaneous nerve and its branches within the pelvis may directly account for this complication [50]. Aszman [51] demonstrated five different types of relationships of the lateral femoral cutaneous nerve to soft tissue and bony structures. Four percent (type A) maintained a course posterior to the anterior superior iliac spine and across the iliac crest; 27 % (type B) traveled anterior to the anterior superior iliac spine, within the inguinal ligament and superficial to the origin of the sartorius muscle. In 23 % (type C) the nerve ran medial to the anterior superior iliac spine within the tendinous origin of the sartorius, and in 26 % (type D) the nerve was found deep to the inguinal ligament between the iliopsoas fascia and the sartorius muscle. In the same study 20 % (type E) pursued a course deep to the inguinal ligament within the soft tissue anterior to the iliopsoas muscle, joining the femoral branch of the genitofemoral nerve. This study has suggested that the lateral femoral cutaneous nerve is most prone to damage when it pursues a course indicated by types A, B, or C.

In a study conducted by Rosenberg et al. [52], the course of the genitofemoral, lateral femoral, and ilioin-

guinal nerves and their relationships to the deep inguinal ring, iliopubic tract, and anterior superior iliac spine were carefully examined. The findings indicate that both branches of the genitofemoral nerve penetrate the abdominal wall lateral to the deep inguinal ring and cranial to the iliopubic tract. The ilioinguinal and lateral femoral cutaneous nerves pursued a course immediately lateral to the anterior superior iliac spine. It concluded that placement of staples either cranial to the iliopubic tract or lateral to the anterior superior iliac spine is likely to produce injury to these nerves.

Hospodar et al. [53] examined, in a series of cadaveric pelvis, the lateral femoral cutaneous nerve with respect to the ilioinguinal surgical dissection. In approximately 10 % of the pelves examined the lateral femoral cutaneous nerve was found either within a half-centimeter of the iliopubic tract or in the vertical plane of the anterior superior iliac spine. These are the principal anchoring sites for mesh in laparascopic hernial repair. In another study, the lateral femoral cutaneous nerve was most commonly found at 10 – 15 mm from the anterior superior iliac spine (ASIS), and as far medially as 46 mm. Because of this variation, careful dissection medial to the ASIS may be essential to locate the nerve.

1.15.2 Indirect Inguinal Hernia

Indirect inguinal hernia (Fig. 1.19) occurs when the processus vaginalis persists, connecting the peritoneal cavity of the abdomen and that of the scrotum or major labium. Indirect inguinal hernia is common in all ages and in both sexes. Kahn and Hamlin [45] concluded that patent processus vaginalis is not always a prerequisite for the occurrence of indirect inguinal hernia. It is often associated with cryptorchid testis and hydrocele. Incarcerated indirect inguinal hernia may occur as a complication of spilled gallstones [54 – 56]. Persistent processus vaginalis may be unmasked by the presence of fluid that fills this peritoneal extension and presents as a scrotal or occasionally as labial edema. In a large indirect inguinal hernia, the inguinal canal is no longer oblique due to the close proximity of the dilated superficial and deep inguinal rings. Since the deep inguinal ring lies lateral to the inferior epigastric vessels, the neck of the hernial sac protrudes through the lateral inguinal fossa, shifting these vessels medially. As it traverses the deep inguinal ring, the hernial sac is invested by the internal spermatic fascia. After pushing up the arching fibers of the transverse and internal abdominal oblique, it becomes invested by the cremasteric muscle and fascia. It emerges at the superficial inguinal ring and descends to the scrotum, where it is covered by the external spermatic fascia, superficial fascia, and the skin. The hernial sac may be strangulated and the blood supply compromised at the deep inguinal ring. Surgical relief may require a superolateral cut to avoid any possible injury to the inferior epigastric vessels.

It may appear in infancy or early adult life subsequent to forced opening of a preexisting or partially patent processus vaginalis during a strenuous activity, such as lifting of heavy objects, or repeated stresses on the wall during sneezing, coughing or vomiting. Pediatric inguinal hernia is almost always indirect and bilateral with right side predominance, and is prone to incarceration and strangulation.

In the male, the hernial sac descends into the scrotum anterior to the spermatic cord testis, and is usually felt as an impulse at the examiner's fingertip upon a sudden increase in intra-abdominal pressure. In the female, the hernial sac descends through a much narrower canal to the major labium; as a result, palpation of the hernial sac is not adequate. This is particularly evident with women in whom the expanding impulse on coughing is not easily felt due to the overlying fatty tissue.

1.15.3 Direct Inguinal Hernia

Direct inguinal hernia is a form of acquired outpouching in which the hernial sac runs through the posterior wall of the inguinal canal and protrudes through the superficial inguinal ring without entering the deep inguinal ring. The neck of the hernial sac is medial to the inferior epigastric vessels and within the supravesical fossa or the Hesselbach's (inguinal) triangle. The supravesical fossa [57 – 59] lies superior to the urinary bladder between the medial and median umbilical ligaments. Since the conjoint tendon is anterior to the supravesical fossa and posterior to the superficial inguinal ring, the hernial sac either passes between the fibers of the conjoint tendon or is completely covered by this tendon. When the hernial sac pierces the conjoint tendon it will be covered by the peritoneum as well as by the aponeurosis of the internal abdominal oblique and transverse abdominis muscle.

Hesselbach's triangle is bounded medially by the rectus abdominis, laterally by the inferior epigastric vessels, and inferiorly by the inguinal ligament [60]. When the hernial sac passes through Hesselbach's triangle, it is usually lateral to the conjoint tendon and will be invested by the extraperitoneal fat, transversalis fascia, external spermatic fascia, superficial fascia, and the skin. In individuals with direct inguinal hernia, the spermatic cord is usually posterolateral to the hernial sac, not posterior to it as in indirect hernia. When the hernial sac is occasionally large, it may protrude into the scrotum or major labium.

Direct inguinal hernia is a commonly bilateral condition that occurs as a result of weakness of the transversalis fascia. Since the path of the hernial sac does not involve the muscular layers or tendinous borders and

the neck of the hernial sac is wide, the risk of incarceration is low. On standing, the hernial sac is felt as a diffuse medial outpouching over the inguinal canal, which is not controlled by digital pressure applied immediately proximal to the femoral artery. Direct inguinal hernia is a less common type of hernia, is age related, usually affects men over age 40, and is rare in women. It is an acquired condition associated with obesity, constipation, and benign prostatic hypertrophy. It is usually asymptomatic and is even less noticeable than the indirect type. This type of hernia is not contained in the spermatic cord, and unless the hernial sac is large it rarely extends to the scrotum or major labium. The hernial sac protrudes anteriorly and pushes the side of the examiner's index finger forward. Both direct and indirect inguinal hernia may protrude on each side of the inferior epigastric vessels as pantaloon hernia.

1.15.4 Femoral Hernia

A femoral hernia presents a hernial sac that protrudes anterior to the pectineal (Cooper's) ligament and through the femoral canal, a potential space between the lacunar ligament and the femoral vein. The femoral ring, which is the upper margin of the femoral canal, is the medial portion of the lacuna vasorum. It is bounded anteriorly by the extension of the transversalis fascia, and posteriorly by the continuation of the pectineal fascia. The neck of the hernial sac is always distal and lateral to the pubic tubercle, a bony landmark between the site of inguinal and femoral hernia. The fundus of the hernial sac (lower part) usually occupies the medial part of the femoral triangle.

The hernial sac traverses the femoral canal and descends vertically posterior to the inguinal ligament, displacing the femoral vein, to exit through the saphenous opening. It tends to ascend from this point proximally, by following the superficial epigastric vessels anterior to the inguinal ligament and the lower part of the external oblique. The hernial sac may turn medially and toward the scrotum or major labium. It may also descend anterior (prevascular hernia) or posterior (retrovascular hernia) to the femoral vessels. It is prevented from descending further down by the attachment of the femoral sheath and the superficial fascia of the thigh to the margins of the saphenous opening. The course of progression of the hernial sac should be taken into consideration and reduction of femoral hernia should be directed in the reverse direction with the thighs passively flexed.

Femoral hernia is more common in female than male at the ratio of 3 : 1. It affects approximately 35 % of the female population particularly in women over 50 years of age. This gender-based difference is attributed to the unique shape of the pelvis, the size of the ring, and the dramatic changes exerted during pregnancy. Its incidence is far lower than that of inguinal hernia and can be easily missed during physical examination.

There is a dramatic correlation between inguinal hernial repair and the incidence of femoral hernia. Mikkelsen et al. [61] reported a 15-fold greater incidence of femoral hernia postinguinal herniorrhaphy compared with spontaneous incidence. Due to the rarity of the femoral hernia in children and the similarity of its manifestations to that of the indirect inguinal hernia, femoral hernia in this population remains a challenging clinical problem.

Misdiagnosis of femoral hernia may be perpetuated by the presence of a patent processus vaginalis and incidental indirect inguinal hernia [62, 63]. A variety of conditions must be excluded in the differential diagnosis of femoral hernia such as lipoma, psoas abscess, obturator hernia, lipoma, and hydrocele.

The femoral hernial sac consists of the parietal peritoneum, femoral septum (extraperitoneal tissue), femoral sheath, cribriform fascia (covers the saphenous opening), superficial fascia, and skin. It frequently contains the small intestine and omentum, but the presence of an inflamed appendix, Meckel's diverticulum, or portion of the bladder should also be expected. Occasionally the ureter or broad ligament of the uterus may also be found. Femoral hernial sac becomes irreducible when it attains a large size, protruding anterior to the inguinal ligament. Due to the ligamentous boundaries, the hernial sac carries a higher risk of strangulation and should be considered part of the differential diagnosis in pregnant women and in individuals with intestinal obstruction. The strangulation is a frequent manifestation at the saphenous opening, the femoral ring, or at the junction of the inguinal ligament and falciform margin of the saphenous opening [64].

1.15.5 Umbilical Hernia

Umbilical hernia, common among African-American children, is associated with failure of complete closure of the umbilical orifice during the 1st year of postnatal life [2]. It is often noticed when the infant cries, which raises the intra-abdominal pressure and causes protrusion of part of the intestine. Surgery becomes essential when the defect is relatively large and persists beyond the age of 4, or becomes incarcerated. In the adult, umbilical hernia may develop more commonly in women, usually postpartum, and a pose serious danger due to the rigid walls of the linea alba, which predisposes the hernial sac to strangulation and incarceration.

Herniation immediately above or below the umbilicus is known as paraumbilical hernia, and occurs in women with multiple pregnancies. It is usually prone to incarceration and usually contains part of the greater omentum.

1.15.6 Omphalocele

Omphalocele is a rare but severe congenital umbilical hernia in which part of a visceral organ protrudes through the umbilical ring into the base of the umbilical cord. This condition begins when the cranial limb of the gut loop coils and rapidly increases in length, protruding through the umbilical ring into the extraembryonic coelomic cavity [2]. This physiological herniation occurs around the 6th week of development, followed by the return of the protruding part of the gut into the enlarged abdominal cavity around the 10th week. Retention of the herniated gut outside the abdomen beyond the 10th week of development is designated as omphalocele. The hernial sac in this case is covered by the combination of a thin layer of peritoneum and by the amnion. In a study involving a large number of consecutive births [3], the overall survival rate was much lower for omphalocele than for gastroschisis. The same study confirmed that omphalocele is usually associated with older maternal age pregnancies, and is more often complicated by threatened abortion.

1.15.7 Epigastric Hernia

Epigastric hernia refers to a protrusion of the peritoneal fat, usually without peritoneal sac, through the linea alba of the epigastrium. The hernial sac may be in the form of a reducible midline nodule that becomes evident in the standing position. It usually contains extraperitoneal fat or it may contain part of the greater omentum or small intestine. Epigastric hernia may produce severe pain, due to ischemia that mimics chronic peptic ulcer.

1.15.8 Incisional Hernia

Incisional hernia occurs up to 5 years following surgical procedures at a site of previous laparatomy where healing was not complete. Postlaparascopy incisional hernia is generally a minor complication and rarely strangulates [65]. It can be visualized by having the patient perform the Valsalva maneuver or raise his or her head while in the supine position. It is the most common type of hernia among all ventral abdominal hernias, and is associated with old age, obesity, improper suturing techniques, postoperational strain, cirrhosis, steroid therapy, infection, hematoma, and ileus. Due to the relatively large size of the neck of the hernial sac, strangulation is rare.

1.15.9 Lumbar Hernias

Lumbar herniation may occur through the superior or inferior lumbar spaces. It is classified as congenital and acquired; the acquired lumbar hernia is subdivided into primary and secondary types. The hernial sac usually consists of the peritoneum, or extraperitoneal tissue, and may contain part of the intestine, kidney, omentum, or mesentery. The hernia produces mild symptoms and can easily be surgically reduced and very rarely becomes strangulated. The superior lumbar hernia occurs through Gynfelt's triangle [66], which is bounded superiorly by the 12th rib and the serratus posterior inferior muscle, laterally by the internal oblique, and medially by the erector spinae muscle. Inferior lumbar hernia [67] is very rare and occurs through Petit's triangle, bounded anterolaterally by the external abdominal oblique, inferiorly by the iliac crest, and posteromedially by the latissimus dorsi muscle.

1.15.10 Spigelian Hernia

The Spigelian hernia is a defect in the aponeurosis of the transverse abdominis muscle between the semilunar line and the lateral border of the rectus abdominis (Spigelian aponeurosis). The semilunar (Spigelian) line represents the transition of the transverse abdominis from muscle to aponeurosis. The hernial sac and the opening cannot usually be palpated because of the intramural location of the hernial sac posterior to the aponeurosis of the external oblique aponeurosis [68]. It can present synchronously with inguinal hernias in neonates, and regardless of age of presentation is almost always congenital in origin [69].

1.15.11 Richter's Hernia

Richter's hernia, which was first described in 1598, refers to the hernial protrusion that contains only a portion of the intestinal wall at any site in the anterolateral abdomen. The involved segment incarcerates or strangulates and may undergo gangrene, but symptoms of ischemic bowel or complete intestinal obstruction are often absent. The hernial sac most commonly occurs at the femoral and inguinal rings and is associated with a high mortality rate [70]. Richter's femoral hernia exhibits vague abdominal signs, groin swelling, but with no intestinal obstruction [71].

References

1. Suleiman S, Johnston DE (2001) The abdominal wall: an overlooked source of pain. Am Fam Physician 64:431 – 438
2. Robinson JN, Abuhamad AZ (2000) Abdominal wall and umbilical cord anomalies. Clin Perinatol 27:947 – 978
3. Stoll C, Alembik Y, Dott B, Roth MP (2001) Risk factors in congenital abdominal wall defects (omphalocele and gastroschisi): a study in a series of 265,858 consecutive births. Ann Genet 44:201 – 208
4. Schild RL, Hoch J, Plath H, Geissen C, Fahnenstich H, Dame C, Hansmann M (1999) Perinatal management of fetal hemolytic disease due to Rh incompatibility combined with fetal alloimmune thrombocytopenia due to HPA-5b incompatibility. Ultrasound Obstet Gynecol 14:64 – 67
5. Benedetti F, Amanzio M, Casadio C, Filosso PL, Molinatti M, Oliaro A, Pischedda F, Maggi G (1997) Postoperative pain and superficial abdominal reflexes after posterolateral thoracotomy. Ann Thorac Surg 64:207 – 210
6. Zadeh HG, Sakka SA, Powell MP, Mehta MH (1995) Absent superficial abdominal reflexes in children with scoliosis. An early indicator of syringomyelia. J Bone Joint Surg Br 77:762 – 767
7. Yngve D (1997) Abdominal reflexes. J Pediatr Orthop 17: 105 – 108
8. Del Valle GO, Combs P, Qualls C, Curet LB (1992) Does closure of Camper Fascia reduce the incidence of post-cesarean superficial wound disruption? Obstet Gynecol 80: 1013 – 1016
9. Markman B, Barton FE Jr (1987) Anatomy of the subcutaneous tissue of the trunk and lower extremity. Plast Reconstr Surg 80:248 – 254
10. Hester TR Jr, Nahai F, Beegle PE, Bostwick J 3rd (1984) Blood supply of the abdomen revisited, with emphasis on the superficial inferior epigastric artery. Plast Reconstr Surg 74:657 – 670
11. Reimann R, Fritz G (1975) The inguinal-flap – anatomical studies of the axial vessels and their course. Handchirurgie 7:109 – 114
12. Onishi K, Maruyama Y (1986) Cutaneous and fascial vasculature around the rectus abdominis muscle: anatomic basis of abdominal fasciocutaneous flaps. J Reconstr Microsurg 2:247 – 253
13. DeGowin RL, Jochimsen PR, Theilen EO (1987) DeGowin & DeGowin's Bedside Diagnostic Examination, 5th edn. Macmillan, New York, pp 813 – 814
14. Rab M, Ebmer J, Dellon AL (2001) Anatomic variability of the ilioinguinal and genitofemoral nerve: implications for the treatment of groin pain. Plast Reconstr Surg 108: 1618 – 1623
15. Schorl M, Schweikardt B, Kaminski M (2000) Idiopathic entrapment neuropathy of the ilioinguinalis nerve – a differential diagnosis in inguinal pain. Schweiz Rundsch Med Prax 89:197 – 200
16. Liszka TG, Dellon AL, Manson PN (1994) Iliohypogastric nerve entrapment following abdominoplasty. Plast Reconstr Surg 93:181 – 184
17. Akita K, Niga S, Yamato Y, Muneta T, Sato T (1999) Anatomic basis of chronic groin pain with special reference to sports hernia. Surg Radiol Anat 21:1 – 5
18. Schlenz I, Burggasser G, Kuzbari R, Eichberger H, Gruber H, Holle J (1999) External oblique abdominal muscle; a new look on its blood supply and innervation. Anat Rec 255:388 – 395
19. Kuzbari R, Worseg A, Burggasser G, Schlenz I, Kuderna C, Vinzenz K, Gruber H, Holle J (1997) The external oblique muscle free flap. Plast Reconstr Surg 99:1338 – 1345
20. Faure JP, Hauet T, Scepi M, Chansiguad JP, Kamina P, Richer JP (2001) The pectineal ligament: anatomical study and surgical applications. Surg Radiol Anat 23:237 – 242
21. Rousseau MA, Perdu M, Ledroux M, Delmas V (1999) Pectineal ligament of Cooper. Micromorphometric study. Morphologie 83:67 – 69
22. Voboril Z (1999) Inguinal hernioplasty according to Lotheissen and McVay. Acta Medica (Hradec Kralove) 42: 25 – 27
23. Grabenhorst R (1994) Evaluation of Bassini reconstruction principle for inguinal hernia. Zentralbl Chir 118:767 – 773
24. Mittelstaedt WE, Rodrigues Junior AJ, Duprat J, Bevilaqua RG, Birolini D (1999) Treatment of inguinal hernias. Is the Bassini's technique current yet? A prospective, randomized trial comparing three operative techniques: Bassini, Shouldice and McVay. Rev Assoc Med Bras 45:105 – 114
25. Dirksen CD, Beets GL, Go PM, Geisler FF, Baeten CG, Kootstra G (1998) Bassini repair compared with laparoscopic repair for primary inguinal hernia: a randomised controlled trial. Eur J Surg 164:439 – 447
26. Maggiore D, Muller G, Hafanaki J (2001) Bassini vs Lichtenstein: two basic techniques for inguinal hernia treatment. Hernia 5:21 – 24
27. Shafik A (1997) Applied anatomy of the cremasteric muscle and fascia. J Urol 158:889
28. Redman JF (1996) Applied anatomy of the cremasteric muscle and fascia. J Urol 156:1337 – 1340
29. Iscoe S (1998) Control of abdominal muscles. Prog Neurobiol 56:433 – 506
30. Nahas FX (2001) Advancement of the external oblique muscle flap to improve the waistline: a study in cadavers. Plast Reconstr Surg 108:550 – 555
31. Humphrey R, Carlan SJ, Greenbaum L (2001) Rectus sheath hematoma in pregnancy. J Clin Ultrasound 29:306 – 311
32. Miyauchi T, Ishikawa M, Miki H (2001) Rectus sheath hematoma in an elderly woman under anti-coagulant therapy. J Med Invest 48:216 – 220
33. Bendavid R, Howarth D (2000) Transversalis fascia rediscovered. Surg Clin North Am 80:25 – 33
34. Memon MA, Quinn TH, Cahill DR (1999) Transversalis fascia: historical aspects and its place in contemporary inguinal herniorrhaphy. J Laparoendosc Adv Surg Tech A 9:267 – 272
35. Menck J, Lierse W (1991) The fascia of the inguinal canal ring. Chirurg 62:117 – 120
36. Morone G, Meriggi F, Forni E (1994) An update of Bassini's operation for the treatment of inguinal hernia. G Chir 15:317 – 320
37. Witte H, Hegelmaier C, Balzer KM, Witte B (1997) Relevance of the fascia transversalis in inguinal hernia repair using total extraperitoneal plastic reconstruction. Chirurg 68:493 – 495
38. Teoh LS, Hingston G, Al-Ali S, Dawson B, Windsor JA (1999) The iliopubic tract: an important anatomical landmark in surgery. J Anat 194:137 – 141
39. Condon RE, Carilli S (1994) The biology and anatomy of inguinofemoral hernia. Semin Laparosc Surg 1:75 – 85
40. Andrews BT, Burnand KG, Ferrar D (1996) Putting a finger on the deep inguinal ring. J R Coll Surg Edinb 41:90 – 92
41. Barteczko KJ, Jacob MI (2000) The testicular descent in human. Origin, development and fate of the gubernaculum Hunteri, processus vaginalis peritonei, and gonadal ligaments. Adv Anat Embryol Cell Biol 156:III–X, 1 – 98
42. Favorito LA, Sampaio FJ, Javaroni V, Cardoso LE, Costa WS (2000) Proximal insertion of gubernaculum testis in normal human fetuses and in boys with cryptorchidism. J Urol 164:792 – 794
43. Maidenberg M. A case of an ectopic testis in the perineum. Prog Urol 3:268 – 271

44. Tanyel FC, Erdem S, Buyukpamukcu N, Tan E (2001) Cremaster muscle is not sexually dimorphic, but that from boys with undescended testis reflects alterations related to autonomic innervation. J Pediatr Surg 36:877 – 880
45. Kahn AM, Hamlin JA, Thompson JE (1997) The etiology of the adult indirect inguinal hernia: revisited. Am Surg 63:967 – 969
46. Hutcheson JC, Cooper CS, Snyder HM 3rd (2000) The anatomical approach to inguinal orchiopexy. J Urol 164:1702 – 1704
47. Merrot T, Delarue A, Chaumoitre K, Panuel M, Sigaudy S, Chazalette JP, Alessandrini P (2001) Bilateral vas deferens agenesis and inguinal hernia in a child: a rare, early presentation of cystic fibrosis. Arch Pediatr 8:728 – 730
48. O'Malley KJ, Monkhouse WS, Qureshi MA, Bouchier-Hayes DJ (1997) Anatomy of the peritoneal aspect of the deep inguinal ring: implications for laparoscopic inguinal herniorrhaphy. Clin Anat 10:313 – 317
49. Abdalla RZ, Mittelstaedt WE (2001) The importance of the size of Hessert's triangle in the etiology of inguinal hernia. Hernia 5:119 – 123
50. de Ridder VA, de Lange S, Popta JV (1999) Anatomical variations of the lateral femoral cutaneous nerve and consequences for surgery. J Orthop Trauma 13:207 – 211
51. Aszman OC, Dellon ES, Dellon AL (1997) Anatomical course of the lateral femoral cutaneous nerve and its susceptibility to compression and injury. Plast Reconstr Surg 100:600 – 604
52. Rosenberg RJ, Loeweneck H, Meyer G (2000) The cutaneous nerves encountered during laparoscopic repair of inguinal hernia: new anatomical findings for the surgeon. Surg Endosc 14:731 – 735
53. Hospodar PP, Ashman ES, Traub JA (1999) Anatomic study of the lateral femoral cutaneous nerve with respect to the ilioinguinal surgical dissection. J Orthop Trauma 13: 17 – 19
54. Bebawi M, Wassef S, Ramcharan A, Bapat K (2000) Incarcerated indirect inguinal hernia: a complication of spilled gallstones. JSLS 4:267 – 269
55. Ok E, Szuer E (2000) Intra-abdominal gallstone spillage detected during umbilical trocar site hernia repair after laparoscopic cholecystectomy: report of a case. Surg Today 30:1046 – 1048
56. Rosin D, Korianski Y, Yudich A, Ayalon A (1995) Lost gallstones found in a hernial sac. J Laparoendosc Surg 5:409 – 411
57. Ekberg O (1981) The herniographic appearance of direct inguinal hernias in adults. Br J Radiol 54:496 – 499
58. Ekberg O, Kullenberg K (1988) Direct diverticular inguinal hernia. Acta Radiol 29:57 – 60
59. Kanamaru H, Odaka A, Horie Y, Makita Y (1995) A case of external supravesical hernia-repair with laparoscopic surgery. Nippon Geka Gakkai Zasshi 96:121 – 124
60. Chevallier JM, Wind P, Lassau JP (1996) Damage to the inguino-femoral nerves in the treatment of hernias. An anatomical hazard of traditional and laparoscopic techniques. Ann Chir 50:767 – 775
61. Mikkelsen T, Bay-Nielsen M, Kehlet H (2002) Risk of femoral hernia after inguinal herniorrhaphy. Br J Surg 89:486 – 488
62. Al-Shanafey S, Giacomantonio M (1999) Femoral hernia in children. J Pediatr Surg 34:1104 – 1106
63. Naude GP, Ocon S, Bongard F (1997) Femoral hernia: the dire consequences of a missed diagnosis. Am J Emerg Med 15:680 – 682
64. Lehur PA, Metairie S (1997) Femoral hernia. Rev Prat 47: 273 – 276
65. Coda A. Bossotti M, Ferri F, Mattio R, Ramellini G, Poma A, Quaglino F, Flippa C, Bona A (1999) Incisional hernia and fascial defect following laparoscopic surgery. Surg Laparosc Endosc Percutan Tech 9:348 – 352
66. Hamasaki K, Yatsugi T, Mochinaga N (1994) A case of superior lumbar hernia. Nippon Geka Gakkai Zasshi 95:719 – 722
67. Rosato L, Paino O, Ginardi A (1996) Traumatic lumbar hernia of the Petit's triangle. A clinical case. Minerva Chir 51: 1125 – 1127
68. Sachs M, Linhart W, Bojunga J (1998) The so called Spigelian hernia – a rare lateral hernia of the abdominal wall. Zentralbl Chir 123:267 – 271
69. White JJ (2002) Concomitant Spigelian and inguinal hernias in a neonate. J Pediatr Surg 37:659 – 660
70. Kadirov S, Sayfan J, Friedman S, Orda R (1996) Richter's hernia – a surgical pitfall. J Am Coll Surg 182:60 – 62
71. Vervest AM, Eeftinck Schattenkerk M, Rietberg M (1998) Richter's femoral hernia; a clinical pitfall. Acta Chir Belg 20:87 – 89